



Atropine and Kounis syndrome, a rare association mimicking ST segment elevation myocardial infarction in a young patient: A Case Report

Asraf Hussain¹, Shyam Raj Regmi¹, Bishnu Mani Dhital¹, Shovit Thapa¹, Tirth Dhungana¹, Amir Khan¹, Sagar Thapa¹, Rohit Murarka¹, Ashok Shrestha¹, Ramgobind Chaudhary¹, Ramnarayan Kurmi¹

¹Department of Cardiology, Chitwan Medical College, Bharatpur, Nepal

ABSTRACT

Kounis syndrome is a hypersensitivity acute coronary disorder which occurs with allergic reaction with drugs, food and insect bite. Atropine is rarely found to be reported with such allergic reactions in the literatures. In this report, we describe a case of a 25 years old male, with a background history of psychotic disorder and cannabis dependent syndrome with persistent bradycardia. When challenged with atropine he developed chest pain, shortness of breath and urticarial rash. ECG showed ST segment changes which settled after symptomatic management. Coronary angiogram revealed normal coronary arteries. Though uncommonly reported, it is one of the confusing and underdiagnosed serious conditions for treating physicians which can potentially mimic ST segment elevation myocardial infarction.

Keywords: Atropine, Hypersensitivity, Kounis Syndrome, Urticaria



This work is licensed under a Creative Commons Attribution 4.0 Unported License.

INTRODUCTION

Kounis syndrome can be defined as the concurrence of acute coronary syndromes including coronary spasm, acute myocardial infarction, and stent thrombosis. It is associated with mast-cell and platelet activation and involves interrelated and interacting inflammatory cells, such as macrophages and T-lymphocytes, in the setting of allergic or hypersensitivity and anaphylactic or anaphylactoid insults. Usually inflammatory mediators like histamine, platelet-activating factor, arachidonic acid products, neutral proteases and a variety of cytokines and chemokines released during the allergic activation process are involved in Kounis syndrome.¹ It is a frequently missed and underdiagnosed allergic condition. Triggers of Kounis syndrome are increasingly being reported. Coronary vasospasm secondary to atropine is reported in one adult patient as well as a single pediatric case in a 10 years old child has also been reported probably due to a cardiac hypersensitivity secondary to atropine.^{2,3} Here we report probably the first case of type 1 Kounis syndrome in Nepal occurring with atropine.

CASE PRESENTATION

A 25-year-old male patient presented with persistent bradycardia, who was admitted to the psychiatry department for acute psychotic disorder with cannabis dependent syndrome. He had been admitted for multiple episodes of nausea and vomiting with a background of five years' history of cannabis abuse. On the 7th day he developed persistent

bradycardia. His vitals at consultation were: pulse 46 beats per minute and regular. His systolic blood pressure was 130mmHg and diastolic blood pressure was 80mmHg. He was afebrile, respiratory rate was 17 breaths per minute and regular. Oxygen saturation was maintained in room air.

He was shifted to CCU for further evaluation. To look for atropine responsiveness 0.6mg of atropine was given intravenously. Soon after receiving atropine he developed chest pain which was associated with vomiting. Patient also complained of palpitation and became pale and sweaty. Oxygen saturation dropped to 76. He developed urticarial rashes all over the body. On auscultation wheeze was noted all over the lung field. Electrocardiographic monitor revealed ST segment elevation. Twelve lead ECG revealed ST segment elevation in infero-lateral leads with ST depression in anterior chest leads.

Intravenous prednisolone was given to the patient at a dose of 100mg. Tab Montelukast was given at a dose of 10mg. Oxygen supplementation was given via face mask. Patient improved with resolution of symptoms over the next few minutes. His complete blood counts, renal function test, liver function test, thyroid function test were within normal limits. Quantitative Troponin I was positive with a value of five. Keeping in view the possibility of acute coronary syndrome in the form of

Corresponding author:
Asraf Hussain
Email: asrafjeevanjyoti2060@gmail.com

ST elevation myocardial infarction, the patient was urgently shifted to the cath laboratory. Coronary angiography was performed which showed normal coronaries. Twelve lead ECG normalized over the next few minutes. On the following

day ECG was normal. Echocardiographic findings were normal too. On the next day he was shifted to the psychiatry ward from where he was discharged on day twelve of admission.

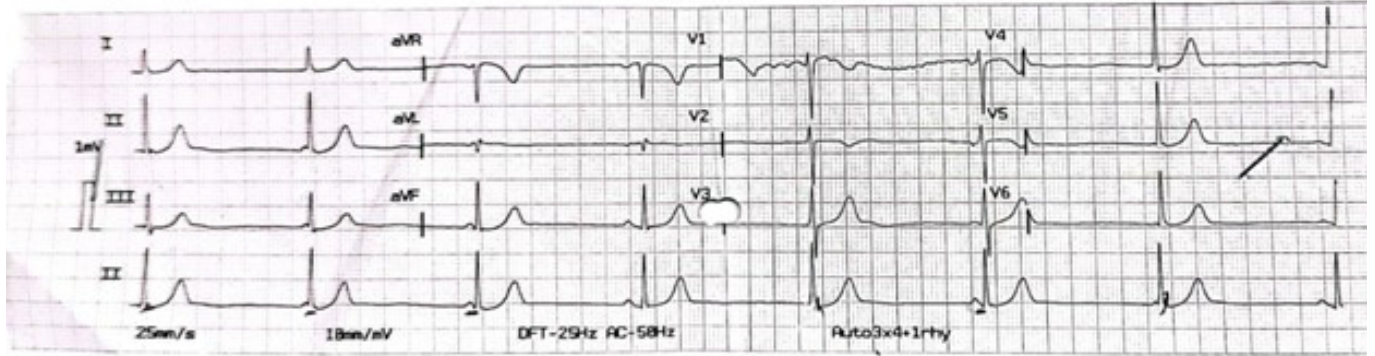


Figure 1: ECG of the patient at first presentation before atropine administration

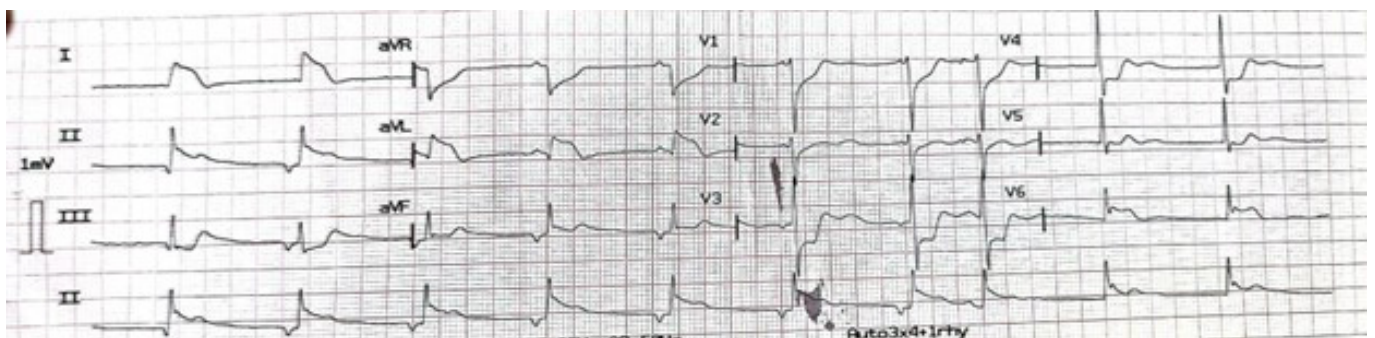

Figure 2: ECG showing ST elevation after administration of atropine

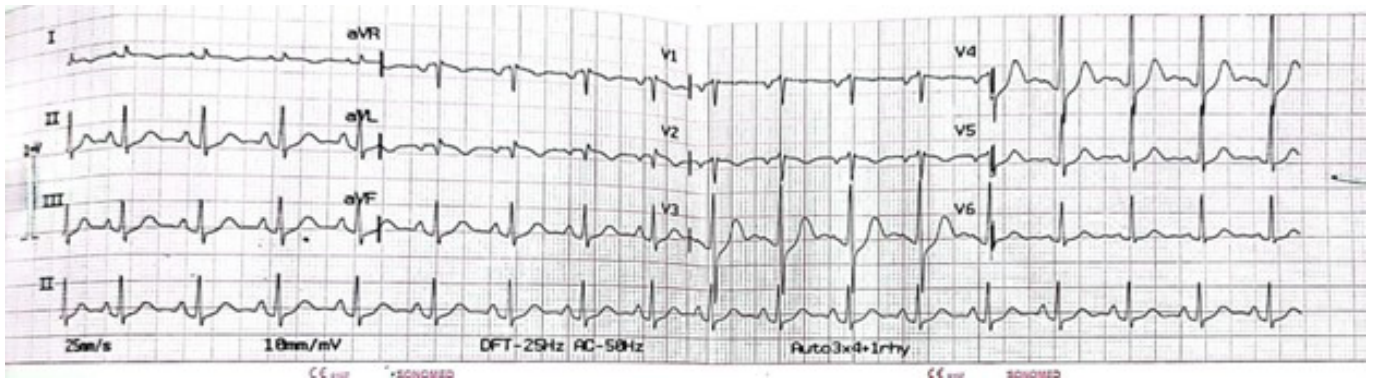


Figure 3: ECG after administration of prednisolone and montelukast

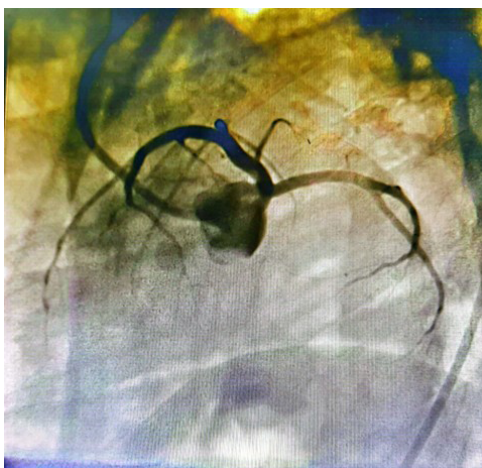


Figure 4: Angiographic findings showing normal coronaries

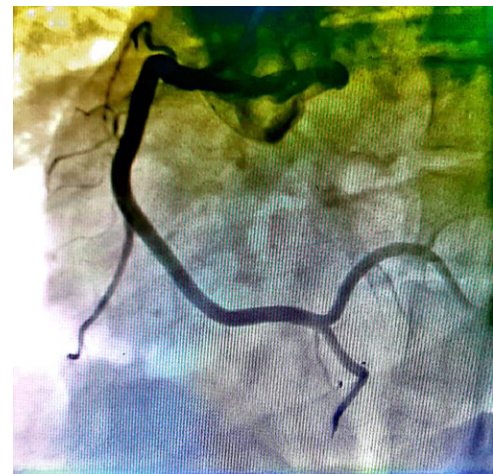

Figure 5: coronary angiography showing normal right coronary artery

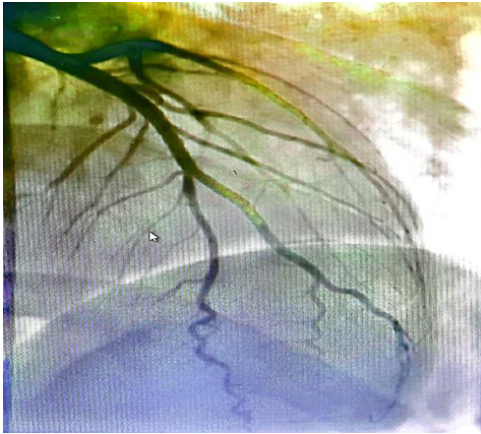


Figure 6: coronary angiography showing normal left circulation

DISCUSSION

Kounis syndrome is a serious hypersensitivity, acute coronary syndrome triggered by food, drugs, insect bites and other environmental factors. It is diagnosed based on clinical presentation, along with laboratory findings, ECG, echocardiographic results, and evidence from coronary angiography. Many therapeutic drugs have been found to be associated with this serious condition in clinical practice including atropine. The diagnosis of atropine-induced Kounis syndrome was made in our case on clinical grounds. Patient developed chest pain, palpitation, shortness of breath, urticarial rashes and ECG changes on intravenous administration of atropine. All these clinical features and ECG findings resolved after the administration of steroid and montelukast. Coronary angiogram revealed normal coronaries and Echocardiography did not show any regional wall motion abnormalities clinching the diagnosis in our case.

NSAIDs and antimicrobials agents are the most commonly involved drugs which are associated with Kounis syndrome in the emergency department.⁴ Anticancer drugs like 5-fluorouracil and epirubicin have also found to be reported in the literature.⁵ A case with inactivated COVID-19 vaccination has recently been reported from Turkey.⁶ Atropine is an antimuscarinic agent used in medical practice for varieties of clinical purposes. However it is considered to be less allergic, few cases of anaphylactic reaction with atropine have been reported in the literature.⁷ A case has been described in pediatric population with coronary artery spasm probably with intravenous infusion of atropine.² Similar episode with anisodiamine, an antimuscarinic agent has also been reported, which shows the evidence that Kounis syndrome can occur with atropine as seen in our case.

In literature three variants of Kounis syndrome have been discussed. Among them, the type I variant (72.6%) is the most common which includes normal or nearly normal coronary arteries without risk factors for coronary artery disease. The type II variant (22.3%) includes the culprit but quiescent

preexisting atheromatous disease. The type III variant (5.1%) includes coronary artery stent thrombosis in which aspirated thrombus specimens when stained with hematoxylin-eosin and Giemsa, demonstrate the presence of eosinophils and mast cells.⁸ Kounis syndrome in our patient was type I variant.

Management of Kounis syndrome is considered in two phases. In the initial phase allergic and anaphylactic reaction is managed with use of corticosteroids, epinephrine and antihistamines.⁹ The coronaries are dealt only after the successful management of allergic reaction. Beta-blockers are better avoided as it opposes effects of epinephrine. Morphine also increases mast cell degranulation which may worsen the allergic reaction so better be avoided.¹⁰ Type I Kounis syndrome usually can be well managed with corticosteroids and H1/H2 receptor blockers in addition to coronary vasodilators such as nitrates/CCBs if tolerated whereas Type II/III Kounis syndrome often may need coronary interventions.¹¹ We managed our case accordingly.

CONCLUSION

Kounis syndrome is a challenging and underdiagnosed serious condition that should be suspected in patients with angina equivalent symptoms and systemic anaphylaxis reaction. Commonly used drugs including atropine can cause Kounis Syndrome. Early diagnosis by the physicians is crucial in management of the patients and good prognostic outcome.

REFERENCES

1. Kounis NG. Coronary hypersensitivity disorder: the Kounis syndrome. *Clin Ther* 2013;35:563–71.10.1016/j.clinthera.2013.02.022
2. Castellano-Martinez A, Rodriguez-Gonzalez M. Coronary artery spasm due to intravenous atropine infusion in a child: possible Kounis syndrome. *Cardiol Young*. 2018 Apr;28(4):616-618. doi: 10.1017/S1047951117002785. Epub 2018 Jan 10. PMID: 29316984.
3. Lee JH, Seok JH, Kim YL, Lee JH, Lee SG, Kim EJ, et al. Atropine injection followed by coronary artery spasm with ventricular tachycardia during spinal anesthesia -A case report-. *Korean J Anesthesiol*. 2013 Jul;65(1):66–70.
4. Wang, C., Fang, W., Song, L., Deng, Z., Li, Z., & Sun, L. (2022). Analysis of Clinical Features of Non-steroidal Anti-inflammatory Drugs Induced Kounis Syndrome. *Frontiers in cardiovascular medicine*, 9, 901522. <https://doi.org/10.3389/fcvm.2022.901522>
5. Liang HZ, Zhao H, Gao J, Cao CF, Wang WM. Epirubicin-induced Kounis syndrome. *BMC Cardiovasc Disord*. 2021 Mar 12;21(1):133.
6. Özdemir İH, Özlek B, Özen MB, Gündüz R, Bayturan Ö. Type 1 Kounis Syndrome Induced by Inactivated SARS-COV-2 Vaccine. *J Emerg Med*. 2021 Oct;61(4):e71–6.

7. Choi J, Kim H, Jeon YS, Hong DM. Anaphylaxis following atropine administration during general anesthesia: a case report. *Korean J Anesthesiol.* 2015 Oct;68(5):496–500.
8. Abdelghany M, Subedi R, Shah S, Kozman H. Kounis syndrome: A review article on epidemiology, diagnostic findings, management and complications of allergic acute coronary syndrome. *Int J Cardiol.* 2017 Apr 1;232:1-4. doi: 10.1016/j.ijcard.2017.01.124. Epub 2017 Jan 27. PMID: 28153536.
9. Takagi S, Goto Y, Hirose E, Terashima M, Sakuragi S, Suzuki S, et al. Successful treatment of refractory vasospastic angina with corticosteroids: coronary arterial hyperactivity caused by local inflammation? *Circ J.* 2004 Jan;68(1):17–22.
10. Ridella M, Bagdure S, Nugent K, Cevik C. Kounis syndrome following beta-lactam antibiotic use: review of literature. *Inflamm Allergy Drug Targets.* 2009 Mar;8(1):11–6.
11. Sebaldt RJ, Sheller JR, Oates JA, Roberts LJ, FitzGerald GA. Inhibition of eicosanoid biosynthesis by glucocorticoids in humans. *Proc Natl Acad Sci U S A.* 1990 Sep;87(18):6974–8.