



# A fatal case of congenital surfactant deficiency caused by ABCA 3 gene mutation in a newborn

Deen Dayalu Ghimire<sup>1</sup>, Suchita Joshi<sup>1</sup>

<sup>1</sup>Nepal Mediciti Hospital, Lalitpur, Nepal

## ABSTRACT:

Respiratory distress syndrome is a common cause for admission in neonatal intensive care unit and is predominant in preterm infants. Rarely, this can cause respiratory distress in full term infants. Here, we present a case of a full term baby without any other obvious cause for respiratory distress and transiently responding to surfactant administration, who eventually died at 1 month of age. As her elder sibling had also died following similar course of illness, congenital surfactant deficiency was suspected and blood sample for genetic testing was sent. This revealed ABCA 3 mutation as the cause of congenital surfactant deficiency.

**Keywords:** Respiratory distress syndrome, Congenital surfactant deficiency



This work is licensed under a Creative Commons Attribution 4.0 Unported License.

## INTRODUCTION

Respiratory distress syndrome (RDS) is a common cause for admission of neonates in neonatal intensive care unit (NICU), especially in preterm infants. However, this condition can sometimes occur in term infants too. Rarely, surfactant deficiency maybe caused by abnormalities of surfactant production or its secondary dysfunction. Surfactant is a complex compound of phospholipids and proteins found in the lungs of all mammals. The most important function of surfactant is to reduce surface tension of the alveoli in order to maintain effective gas exchange in lungs<sup>1</sup> Specific surfactant proteins A(SP-A), B(SP-B), C(SP-C) and D(SP-D) are encoded by the SFTPA, SFTPB, SFTPC and SFTPD genes and each of them have considerable functional Significance<sup>2</sup>. Severe inherited neonatal respiratory distress has also been attributed to mutations in the ATP binding cassette A3 transporter (ABCA 3) gene<sup>3,4</sup>. ABCA 3 protein is believed to transport lipids into lamellar bodies where the components of mature pulmonary surfactant are assembled before being secreted into the alveolar airspaces<sup>5</sup>. The spectrum and severity of disease caused by ABCA 3 deficiency is variable ranging from fulminant neonatal respiratory failure resulting in death during first few days or months of life to interstitial lung disease that may present later in life<sup>3,6</sup>.

## CASE

A full term female baby weighing 3120 grams was born via spontaneous vaginal delivery with normal APGAR score. There was no history of consanguinity in parents, no risk factors for sepsis and meconium aspiration or birth trauma.

There was a history of previous neonatal death two years ago. The previous sibling was also a full term female baby

who developed respiratory distress soon after birth. No specific cause for respiratory distress was found and the baby eventually died at one month of age following several failed attempts at extubation from mechanical ventilation and development of pulmonary interstitial emphysema.

Our patient developed respiratory distress within few minutes after birth. The baby was immediately brought to the NICU and was started on Bubble CPAP (continuous positive airway pressure) support with PEEP (positive end expiratory pressure) of 5 cm of water. Septic work up was negative and echocardiography was normal. At 48 hours of life, her respiratory distress worsened and required mechanical ventilation with high pressures. Chest x ray (Figure 1) and CT angiogram (Figure 2) revealed bilateral diffused ground glass opacity suggestive of surfactant deficiency RDS. Exogenous surfactant was administered via endotracheal tube, following which there was dramatic improvement.

However, after 48 hours of surfactant administration, baby started developing carbon dioxide retention and increase in oxygen requirement. Second dose of surfactant was administered at five days of age. Once again, following exogenous surfactant therapy, there was improvement in arterial blood gas parameters and ventilator parameters, and the baby was extubated to CPAP at 8 days of age. Unfortunately, the baby's respiratory status deteriorated once again. The family decided against further escalation of treatment. The baby eventually died at one month of age following supportive and palliative care in NICU.

Corresponding author:  
Suchita Joshi  
suchitajoshi29@gmail.com

As this baby's presentation was consistent with genetic surfactant deficiency as evidenced by respiratory distress soon after birth requiring mechanical ventilation in a full term baby without other obvious cause, CT chest showing bilateral ground glass opacity, improvement in respiratory status after each dose of exogenous surfactant administration, and previous sibling having similar course of illness eventually leading to death, blood was sent for genetic testing to rule out inherited surfactant deficiency. On exome sequencing (CentodX™), a homozygous variant was identified in the ABCA3 gene suggestive of a genetic diagnosis of autosomal recessive surfactant metabolism dysfunction type 3.

## DISCUSSION

ABCA 3 mutation appears to be the most common cause of inherited surfactant deficiency<sup>7</sup>. About 400 mutations of ABCA 3 gene have been identified till date but very few of them have been studied in vitro to determine their effects on ABCA 3 expression, intracellular routing, and /or function<sup>8</sup>. Various lung diseases caused by ABCA 3 mutation are inherited as an autosomal recessive disorder requiring mutations on both alleles.

Neonates having ABCA 3 deficiency can present with signs and symptoms of respiratory distress, pulmonary hypertension, diffuse infiltrates in chest x-ray with rapid progression to hypoxaemic respiratory failure and death despite intensive medical intervention.

Genetic testing using blood sample in cases of suspected congenital surfactant deficiency is a non-invasive procedure, and a positive molecular diagnosis may obviate the need for lung biopsy. In our case, the genetic diagnosis provided a clear explanation to the baby's severe lung condition. It also helped in counselling of the parents regarding the prognosis and ultimately would aid them in planning for future pregnancies.

There is limited information regarding the treatment of this condition in newborns and infants. Systemic corticosteroids and Hydroxychloroquine are widely used for interstitial disease caused by ABCA 3 mutation, although there is no good evidence about their beneficial effect in these babies<sup>9</sup>. The only definitive treatment option for patients with severe lung disease due to ABCA 3 mutation is lung transplantation. Although it is not readily available and is a complicated procedure in infants, these children have similar survival rates to older children with lung transplantation<sup>10</sup>. The majority of the infants with ABCA 3 mutation who do not undergo lung transplantation do not survive beyond three to six months of life<sup>11</sup>.

## CONCLUSION

Congenital surfactant deficiency should be considered in full term newborn babies presenting with respiratory failure immediately after birth with no other obvious cause. ABCA 3 gene mutations which are commonly associated with a congenital disorder of surfactant metabolism have no specific

treatment till date with almost 100 % mortality without lung transplantation.

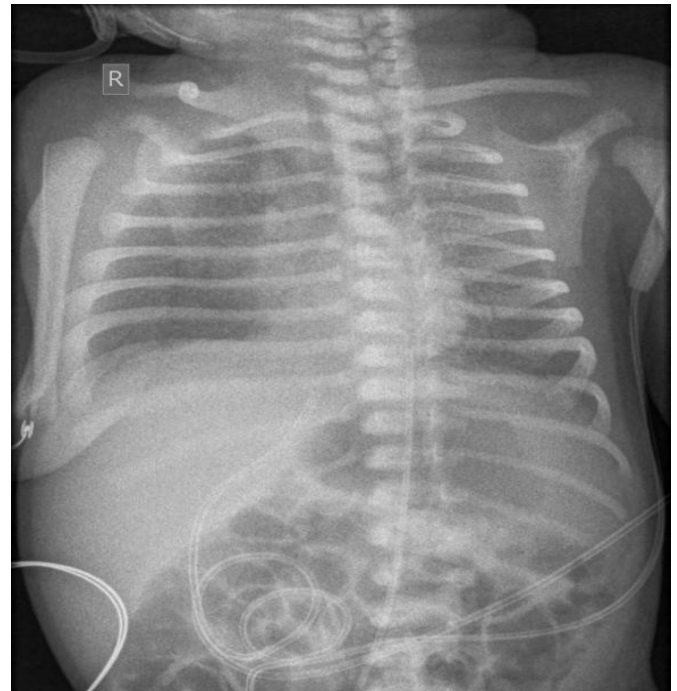


Figure 1. Chest x ray AP view showing subtle diffused ground glass opacities and reticular opacities in all zones of bilateral lungs

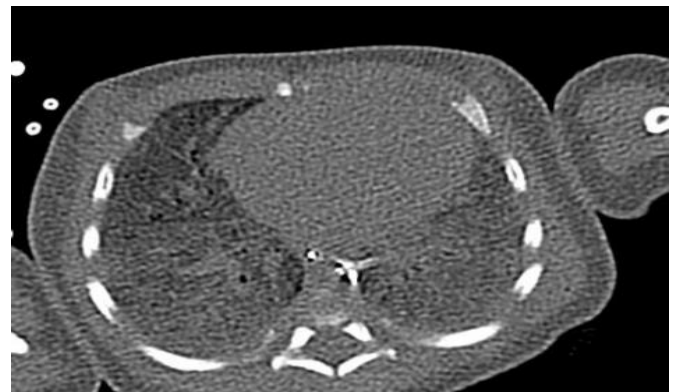

Figure 2. Non-contrast CT axial view in lung and mediastinal window showing ground glass appearance of bilateral lungs

## REFERENCES

1. Nogee LM. Interstitial lung disease in newborns. *Semin Fetal Neonatal Med.* 2017 Aug;22(4):227-33.
2. Hallman M. The Surfactant System Protects Both Fetus and Newborn. *NEO.* 2013;103(4):320-6.
3. Bullard JE, Wert SE, Whitsett JA, Dean M, Nogee LM. ABCA3 mutations associated with pediatric interstitial lung disease. *Am J Respir Crit Care Med.* 2005 Oct 15;172(8):1026-31.
4. Brasch F, Schimanski S, Mühlfeld C, Barlage S, Langmann T, Aslanidis C, et al. Alteration of the pulmonary surfactant system in full-term infants with hereditary ABCA3 deficiency. *Am J Respir Crit Care Med.* 2006 Sep 1;174(5):571-80.

5. Nagata K, Yamamoto A, Ban N, Tanaka AR, Matsuo M, Kioka N, et al. Human ABCA3, a product of a responsible gene for abca3 for fatal surfactant deficiency in newborns, exhibits unique ATP hydrolysis activity and generates intracellular multilamellar vesicles. *Biochem Biophys Res Commun*. 2004 Nov 5;324(1):262–8.
6. Doan ML, Guillerman RP, Dishop MK, Nogee LM, Langston C, Mallory GB, et al. Clinical, radiological and pathological features of ABCA3 mutations in children. *Thorax*. 2008 Apr 1;63(4):366–73.
7. Jouza M, Jimramovsky T, Sloukova E, Pecl J, Seehofnerova A, Jezova M, et al. A Newly Observed Mutation of the ABCA3 Gene Causing Lethal Respiratory Failure of a Full-Term Newborn: A Case Report. *Frontiers in Genetics* [Internet]. 2020 [cited 2022 Mar 17];11. Available from: <https://www.frontiersin.org/article/10.3389/fgene.2020.568303>
8. Nogee LM. Genetic causes of surfactant protein abnormalities. *Curr Opin Pediatr*. 2019 Jun;31(3):330–9.
9. Vece TJ, Fan LL. Diagnosis and management of diffuse lung disease in children. *Paediatr Respir Rev*. 2011 Dec;12(4):238–42.
10. Elizur A, Faro A, Huddleston CB, Gandhi SK, White D, Kuklinski CA, et al. Lung transplantation in infants and toddlers from 1990 to 2004 at St. Louis Children's Hospital. *Am J Transplant*. 2009 Apr;9(4):719–26.
11. Hayes D, Lloyd EA, Fitch JA, Bush A. ABCA3 Transporter Deficiency. *Am J Respir Crit Care Med*. 2012 Oct 15;186(8):807–807.