

Original Article

Colorectal Polyps: A Histopathological Study in Tertiary Care Center

Dipika Basnet¹, Ramesh Makaju¹, Ram Bahadur Gurung², Rachana Dhakal¹

¹Department of Pathology, Dhulikhel Hospital, Kathmandu University Hospital, Kavrepalanchowk, Nepal

²Department of Internal Medicine, Dhulikhel Hospital, Kathmandu University Hospital, Kavrepalanchowk, Nepal.

ABSTRACT

Introduction: Gastrointestinal polyps are commonly encountered in the colorectal region. They can be non-neoplastic or neoplastic. Neoplastic polyps include adenomas which are clinically important because of their premalignant nature. The study was carried out to analyze the histomorphological spectrum of polyps in our institution with special emphasis on adenomatous polyps.

Material and methods: This is a retrospective study done from January 2015 to December 2019 in the Department of Pathology, Dhulikhel Hospital - Kathmandu University Hospital (DH - KUH). Relevant clinical data of the patients were obtained from the histopathological records of the patient from the pathology department and biopsies stained with Haematoxylin and Eosin were studied under the light microscope.

Results: A total of 168 cases of polyp were studied from 125 patients. The most common indication for colonoscopy in patients with polyp was per rectal bleeding. The age of the patient ranged from 2 to 83 years. The rectum was the commonest location. 106(63.1%) of polyps were non-neoplastic and 6(3.6%) of polyps were neoplastic. Juvenile polyp(71;42.3%) was the commonest polyp. Tubular adenoma(55;32.7%) was the commonest neoplastic polyp. The maximum number of neoplastic polyps were seen in the age group of 51-60 years (11;29.7%). Male predominance was seen in neoplastic as well as a non-neoplastic polyp. High grade adenoma(4;6.7%) was more commonly seen in adenomatous polyp >2cm(3;75%) followed by 1-2cm(1;25%) and none in <1cm.

Conclusions: This study gives a fair insight into the distribution of neoplastic and non-neoplastic polyp in the colorectal region. Adenomatous polyp are premalignant lesions so screening of the patients for further treatment and prevention is needed.

Keywords: Adenoma; Colorectal polyp; Juvenile polyp

Correspondence:

Dr. Dipika Basnet, MD
Department of Pathology, Dhulikhel Hospital,
Kathmandu University Hospital, Kavrepalanchowk, Nepal
ORCID ID: 0000-0002-5103-9445
E-mail: dipikabasnet1@gmail.com

Submitted: 24th May 2020

Accepted: 30th June 2021

Source of Support: None

Conflict of Interest: No



Citation: Basnet D, Makaju R, Gurung RB, Dhakal R. Colorectal polyps: A histopathological study in tertiary care center. NMJ 2021;4(1):414-8. DOI 10.3126/nmj.v4i1.37707

INTRODUCTION

Gastrointestinal polyps are masses that project above the level of surrounding mucosa which are most commonly present in the colon and rectum.¹ Major clinical presentations in symptomatic cases of colorectal polyp include gastrointestinal bleeding, abdominal pain, intestinal obstruction, and rectal prolapse, however, most polyps remain asymptomatic and unrecognized.² Colonoscopy is a procedure used to visualize inside of the colon

and rectum and used in screening, assessment, and management of colorectal diseases.³

Colorectal polyps can be classified as neoplastic and non-neoplastic. Neoplastic polyp includes adenoma and non-neoplastic polyp can be classified as inflammatory, hamartomatous or hyperplastic.^{1,4}

According to the population-based cancer registry in Nepal, cancer of the colon and rectum is the third commonest site for cancer irrespective of age and sex.⁵ Around 80-90% of colorectal carcinoma originates on the background of polyp which undergoes dysplasia, adenocarcinoma in situ, and adenocarcinoma sequence.⁶ The prevalence of intestinal adenomas varies in different parts of the world and is common in westernized countries.⁷ Studies done in our country show the frequency of neoplastic polyp ranges from 22-30%.^{8,9} Early recognition of these polyps and colonoscopic polypectomy following histological examination are important for identifying the nature of the lesion for further management of the patient. Simple colonoscopic removal of them can stop the development of colorectal cancer and prevent disease and death.

This study aimed to evaluate the frequency of histological variants among colorectal polypectomy specimens concerning age, sex, size, and site and with special emphasis on adenomatous polyp.

MATERIALS AND METHODS

This retrospective study was carried out in the Department of Pathology, Dhulikhel Hospital - Kathmandu University Hospital(DH-KUH). Ethical approval from the Institutional Review Committee was obtained. 173 specimens labeled as polypectomy specimens from 130 patients that underwent lower gastro-endoscopy were received in the Department of Pathology during a period of five years from January 2015 to December 2019 were included in the study. Tissue that was histologically inadequate for evaluation and autolyzed samples were excluded from the study.

All the biopsy specimen were fixed in 10% formalin for 24 hours. The specimen was then subjected to gross examination, noting the largest size, appearance, external surface, and cut surface. The findings were recorded and the representative bits were given. The tissue was processed and was cut into five-micron sections. Slides were stained with H & E stain. The patient's history, location of polyp, age, gender, and colonoscopic findings were obtained from the patient's record file and histopathological forms. The histopathological features were studied.

Patient data were entered in Microsoft Excel and descriptive data analysis was done using Statistical Package for social sciences(SPSS) 16.0 software.

RESULTS

A total of 173 specimens were received as polypectomy specimens from 130 patients that underwent lower gastro-endoscopy. Out of these, 125 patients had a polyp on histological examination. Five of the samples were histologically not polyp and diagnosed as normal histology in 2 cases, chronic colitis in two case and low-grade dysplasia in 1 case. Out of 125 patients histologically diagnosed as polyps, a total of 168 polypectomy specimen were received. Single polypectomy biopsy was received in 104 patients and multiple polyps were received from 21 patients. The age of the patient ranged from 2 to 83 years. Maximum cases were in the age group of 0-10years (23.2%) whereas minimum cases were in the more than 70years (1.5%) age group. (fig. 1). Male predominance was seen with male to female ratio of 1.8:1. Per rectal bleeding was the major indication for lower gastro

endoscopy as depicted in figure 2.

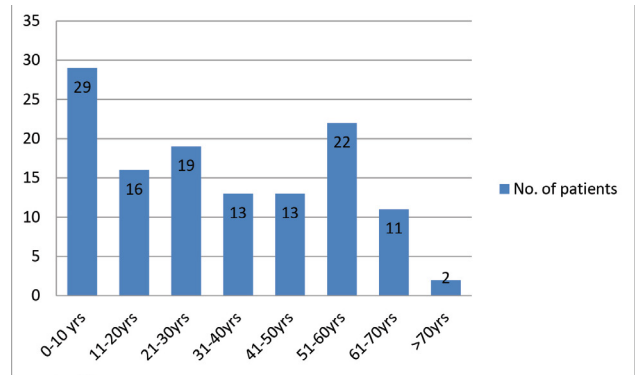


Figure 1: Distribution of the age of the patients (n=125)

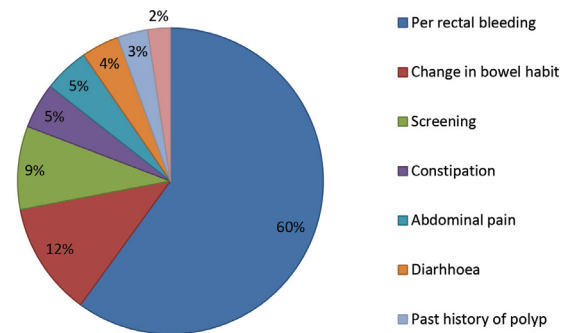


Figure 2: Indication for lower gastro endoscopy examination (n=125)

Most of the biopsies were received from the rectum (49.7%) which was followed by the sigmoid colon (15.6%). (Figure 2) Out of 168 polyps, 118 polyps were pedunculated and 50 were sessile.

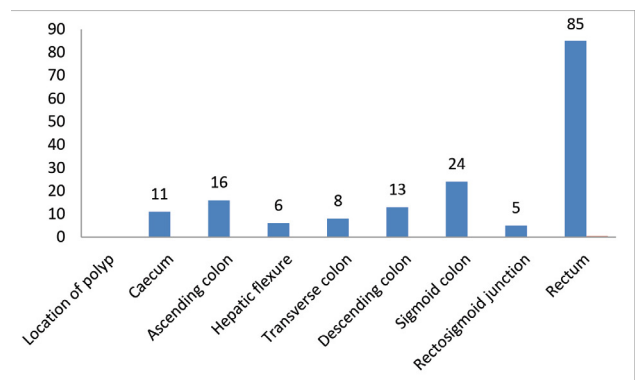


Figure 3. Location of polyps(n=168)

Non-neoplastic polyps comprised the majority of polyps comprising 63.1% of cases and neoplastic polyps were 36.9%. Various histological types of polyps diagnosed are shown in table 1.

Table 1: Histological types of polypoidal lesions

Type of Polyp	Number (%)
Neoplastic	62(36.9)
1. Tubular adenoma	55(32.7)
2. Tubulovillous adenoma	5(3)
3. Sessile serrated adenoma	1(0.6)
4. Lipoma	1(0.6)
Non- neoplastic	106(63.1)
1. Hyperplastic polyp	12(7.1)
2. Juvenile polyp/Retention polyp	71(42.3)
3. Peutzjeghers polyp	13(7.7)
4. Inflammatory polyp	10(6)
Total	168(100)

The juvenile polyp was the commonest histological variant of polyp diagnosed with a total of 71 polyps received from 62 patients. The highest incidence was in the 0-10 years age group consisting of 17.3% cases followed by 11-20 years (7.7%) and 21-30 years (5.9%) of age group respectively. The Predominant number of polyps was from the rectum followed by the sigmoid colon. Male and female were 54.9% and 45.1% respectively. The mean size of the polyp was 16.2mm.

Out of 168 cases, 61(36.3%) cases of adenomatous polyp were identified. 55 cases of tubular adenoma were received from 33 patients. Five cases of tubulovillous adenoma were obtained from 4 patients. Maximum number of adenoma(tubular adenoma and tubulovillous adenoma) were seen in 51-60 years age group(29.7%) followed by 31-40years(21.6%), 41-50 years and 61-70years(18.9%each), 21-30years(8.1%) and >70 years(2.7%). The male to female ratio was 2.1:1. The rectum was the commonest site. The majority of adenoma was low grade(93.4%). High grade adenoma was more commonly seen in adenomatous polyp >2cm(3;75%) followed by 1-2cm(1;25%) and none in <1cm. (Table 2)

Table 2: Characteristic of adenomatous polyps and their relationship with a grade of dysplasia

	Polyp Characteristic	High grade(n)	Low grade(n)
Histological type	Tubular	4	51
	Tubulovillous	-	5
	Sessile serrated adenoma	-	1
Size of polyp (Tubular and tubulovillous)	<1cm	-	28
	1-2cm	1	20
	>2cm	3	8
Morphological type(Tubular and tubulovillous)	Pedunculated	36	2
	Sessile	20	2

DISCUSSION

Colorectal polyps are a common colonoscopic finding which is usually received as a specimen for histopathological examination.

They can be broadly categorized as neoplastic and non-neoplastic which is essential for further management of the patients as simple colonoscopic removal of them can stop the development of colorectal cancer and prevent disease and death.⁷

Polyps are usually asymptomatic and may present with GI bleeding, abdominal pain, intestinal obstruction, and rectal prolapse.²In our study we included the symptomatic cases and per rectal bleeding was the most common presentation (60%) which is similar to the finding by Yousef et al(63.1%), Tony et al(40%), and Fonget al(22.5%).¹⁰⁻¹²

The age of the patients ranged from 2years to 83years. The majority of the patients were children and belonged to the age group of 0-10years (23.2%), followed by 51-60years(17.6%). Comparable to our finding Kumar et al¹² had 85 % of the cases below 20years. In contrast, majority of cases were in the age group of >60 years in studies conducted by Jain et al and Wickramasinghe et al.^{14,15} In the present study male (64.8%) preponderance was observed similar to other studies.^{11,14,16}

Based on location rectum (49.7%) was the commonest site followed by a sigmoid colon(15.6%) which is in concordance with the studies done by Tony et al, Wickramasinghe et al and Kumar et al.^{11,13,15} Non-neoplastic polyps of the colon can be further classified as hyperplastic, inflammatory, hamartomaous, Peutz-Jeghers, juvenile, angiogenic, inflammatory fibroid and lymphoid polyp. In the present study nonneoplastic polyp constituted a major number of cases(63.1%) which is in concordance with the studies done by Kumar et al, Wisedopas et al and Mbakop et al.^{13,17,18}(Table3)

Table3. Comparative distribution of non-neoplastic and neoplastic lesion.

Name of study	Non-neoplastic(%)	Neoplastic(%)
Mbakop et al ¹⁸ (n=102)	87.5	12.5
Wisedopas et al ¹⁷ (776)	50	50
Kumaret al ¹³ (n=70)	83	17
Tony et al ¹¹ (n=124)	20.2	79.8
Yosufet al ¹⁰ (n=154)	37	63
Qureshi et al ¹⁹ (n=160)	45	55
Present study (n=168)	63.1	36.9

Juvenile polyps are focal malformations of the epithelium and lamina propria which mainly occur in the first 2 decades of life but can present at older ages as well.^{1,4} Juvenile polyp was the commonest histopathological finding comprising 42.3% of cases. This is consistent with the studies done by Kumar et al¹³(91.5%) and Mbakop et al¹⁸(54%) in which children and young adult form the major number of patients. Most patients were in the age group of 0-10 years (17.3%) followed by 11-20 years (7.7%) and 21-30 years (5.9%). This is in agreement with the findings of Tony et al where the age range was 4-28years.¹¹ Rectum(73.2%) followed by a sigmoid colon(12.7%) was the common site of occurrence which coincides with various studies.^{13,2,20} Male predominance was observed similar to Tony et al, Yousufet al and Leet al.^{10,11,20}

In contrast, neoplastic adenomatous polyp formed the commonest finding in other studies carried out by Tony et al(81.2%), Jain et

al(48.9%), Wickramasinghe et al(68.7%), and Yadav et al(63.7%) in which adult population was the predominant population.^{11,14-16} The discrepancies in the distribution of lesions among these studies are likely due to differences in the predominant age group involved in the study.

Peutz-Jeghers polyp is a hamartomatous lesion that is most often identified in patients with the Peutz-Jeghers syndrome, associated with mucocutaneous pigmentation.⁴ It comprised 7.7% of the total polyps. The finding is high in comparison to the findings by Tony et al(0.8%), Yadav et al(0.5%), Geramizadeh et al(0.3%) which can be due to the inclusion of multiple numbers of the polyp from the same patient and variation in the incidence of the disease according to place.^{11,16,21} Mean age was 38 years which is comparable to a study done by Oncel et al.²²

Hyperplastic polyps are benign epithelial proliferations located commonly in the rectum.^{1,4} In present study total of 7.1% of hyperplastic polyps was diagnosed which is similar to studies done by Fong et al and Albasri et al.^{12,23}

Inflammatory polyps are secondary to inflammatory disorders of the intestine. Inflammatory polyp consisted of 6% of cases. The finding is in concordance with Albasri et al(5.8%).²³ Most of these patients were within the age group of 51-60 years in our study. However, in studies by Patil et al, Sherpa et al and Albasri et al majority of cases were within the 5th decade of life.^{6,9,23}

Various neoplastic lesions can form a polypoid lesion in the colon. Adenomatous neoplastic polyps are clinically important as 80-90% of colorectal carcinoma originates on the background of polyp which undergoes dysplasia, adenocarcinoma in situ, and adenocarcinoma sequence.⁶ Adenomas can be traditionally divided into three types: tubular, villous, and tubulovillous.⁴ These polyps can be sessile when do not have a stalk or termed pedunculated if have stalk.¹ In our study tubular adenoma was the most common subtype (91.7%) followed by the tubulovillous

type. A similar higher incidence of tubular adenoma was observed in various studies.^{10,11,16,19,21} Similar to Tony et al¹¹, pedunculated adenomatous polyp was higher compared to sessile adenomas. The maximum number of adenomas were seen in the 51-60 years age group (11 cases; 18.3%) which is in concordance to Qureshi et al.¹⁹ Male preponderance as in our study was seen in various other studies.^{14,19,21} Adenomas were commonly located in rectum (18 cases; 30%) adenoma which is similar to Geramizadeh et al.²¹ In our study low-grade adenoma was common (93.4%) which coincides with Jain et al and Geramizadeh et al.^{14,21} Studies have shown the presence of villous component to increase the neoplastic grade of the polyp.^{11,16,24} However no such finding was observed in our study and this could be due to the small number of cases with a villous component.

Based on the size of the polyp majority of the adenomatous polyp were <1cm (48.4%), and the least number of adenomatous polyp were >2cm (13.3%). This finding is in accordance with studies of Yusuf et al, Tony et al, Fong et al., and Albasri et al.^{10-12,23} In present study 75% of high-grade adenomas were larger than 2cm and 25% were 1-2cm in. None of the adenoma <1cm had features of high-grade adenoma. Similar findings of larger adenoma with high-grade dysplasia were observed by Tony et al (76%) and Yadav et al(44.4%).^{11,16}

CONCLUSIONS

Colonoscopy is a common procedure used for the identification and removal of colorectal polyps. The present study provides a fair insight into the histomorphological patterns of polyp in our institution. Adenomatous polyps were less common compared to studies from other countries. The most common indication for colonoscopy was per-rectal bleeding. The most common histological variant was a juvenile polyp. Tubular adenoma was the most common neoplastic polyp.

REFERENCES

- Kumar V, Abbas AK, Aster JC, editor. Robbins and Cotran pathologic basis of disease. Vol 2 9th ed. Reed Elsevier: New Delhi; 2015. pp 804-14
- Ashtiani MTH, Monajemzadeh M, Motamed F, et al. Colorectal polyps: a clinical, endoscopic and pathologic study in Iranian children. *Med Princ Pract* 2009;18(1):53-6. [Crossref](#)
- Makaju R, Amatya M, Sharma S, Dhakal R, Bhandari S, Shrestha S et al. Clinico-Pathological Correlation of Colorectal Diseases by Colonoscopy and Biopsy. *Kathmandu Univ Med J* 2017;58(2):173-8. [Website](#)
- Mills SE editor. Sternberg's Diagnostic surgical pathology. 5th ed. Wolters Kluwer: Philadelphia; 2015. pp 1368-94.
- Population-based cancer registry in Nepal. Interim Analysis of data from January-May 2018 Progress Report. Ramshah Path Kathmandu, Nepal Health Research Council. November, 2018. Accessed on 2nd May 2021. Available from: [Website](#)
- Patil MV, Rathod U, Deshmukh M, Margam S, Kalgutkar AD. Spectrum of gastrointestinal polyps: A tertiary care hospital experience of five years. *Indian Journal of Pathology and Oncology* 2018;5(4):656-62. [Crossref](#)
- Chitturi R, Renuka IV, Latha PP, Vaishnavi R, Manasa BM. Morphologic spectrum of gastrointestinal polyps and polypoid lesions-a five year study. *IP Arch Cytol Histopathol Res* 2018;3:151-5. [Crossref](#)
- Gurung P, Hirachand S, Pradhanang S, Lama S. A histopathological study of gastrointestinal polyps in tertiary care hospital. *Journal of BP Koirala Institute of Health Sciences* 2014;36:64-8. [Crossref](#)
- Sherpa P, Jha A, Koirala S, Ghimire R. Polypoid lesions of the gastrointestinal tract. *Journal of Pathology of Nepal* 2020;10:1625-9. [Crossref](#)
- Bafandeh Y, Daghestani D, Esmaili H. Demographic and anatomical survey of colorectal polyps in an Iranian population. *Asian Pac J Cancer Prev*. 2005;6(4):537-40. [Website](#)
- Tony J, Harish K, Ramachandran TM, Sunilkumar K, Thomas V. Profile of colonic polyps in a southern Indian population. *Indian J Gastroenterol* 2007;26(3):127-9. [Website](#)
- Fong TV, Chuah SK, Chiou SS, et al. Correlation of the morphology and size of colonic polyps with their histology. *Chang Gung Med J* 2003;26(5):339-42. [Website](#)
- Kumar N, Anand BS, Malhotra V, Thorat VK, Misra SP, Singh SK, Chaudhary A. Colonoscopic polypectomy. North Indian experience. *J Assoc Physicians India*. 1990;38(4):272-4. [Website](#)
- Jain M, Vij M, Srinivas M, Micheal T, Venkataraman J. Spectrum of colonic polyps in a South Indian Urban cohort. *Journal of Diagnostic Endoscopy* 2017;8:119-22. [Website](#)

15. Wickramasinghe DP, Samaranyaka SF, Lakmal C, Mathotaarachchi S, Kanishka CL, Keppetiyagama C, Samarasekera DN. Types and patterns of colonic polyps encountered at a tertiary care center in a developing country in South Asia. *Anal Cell Pathol(Amst)* vol. 2014, Article ID 248142, 4 pages, 2014. [Crossref](#)
16. Yadav R, Ganesh P, Shanmuganathan S, Koushik AK. Profile of colonic polyps in a tertiary care center in South India. *Int J AdvRes(Indore)* 2019.7(10):1238-42. [Crossref](#)
17. Wisedopas N, Thirabanjasak D, Taweewisit M. A retrospective study of colonic polyps in King Chulalongkorn Memorial Hospital. *J Med Assoc Thai* 2005;88(Suppl 4):S36-41. [Website](#)
18. Mbakop A, NdjitoyapNdam EC, Pouaha J, Sosso M, Tzeuton C, Biwole SM. Anatomopathological aspects of colorectal polyps in Cameroon. *Arch AnatCytolPathol* 1991;39(4):158-61. [Website](#)
19. Qureshi A, Shihi SA, Ali Z, Shalaby A. A retrospective study of clinico-pathological characteristics of colonic polyps in adults seen at a tertiary care centre. *J Pak Med Assoc*2017;67(1):12-4. [Website](#)
20. Lee BG, Shin SH, Lee YA, Wi JH, Lee YJ, Park JH. Juvenile Polyp and Colonoscopic Polypectomy in Childhood. *Pediatr Gastroenterol Hepatol Nutr* 2012;15:250-5. [Crossref](#)
21. Geramizadeh B, Keshtkar-Jahromi M. Pathology of colorectal polyps, A study from south of Iran. *Ann Colorectal Res* 2013;1(2):60-2. [Website](#)
22. Oncel M, Remzi FH, Church JM, Goldblum JR, Zutshi M, Fazio VW. Course and follow-up of solitary Peutz-Jeghers polyps: a case series. *Int J Colorectal Dis* 2003;18(1):33-5. [Crossref](#)
23. Albari A, Yosef H, Hussainy A, Bukhari S, Alhujaily A. Profile of colorectal polyps: a retrospective study from King Fahad hospital, Madinah, Saudi Arabia. *Asian Pac J Cancer Prev* 2014;15(6):2669-73. [Crossref](#)
24. Amarpurkar AD, Nichat P, Narawane N, Amarpurkar Deepak. Frequency of colonic adenomatous polyps in a tertiary hospital in Mumbai. *Indian J Gastroenterol* 2016;35(4):299-304. [Crossref](#)