

Original Article

# Diffuse Alveolar Haemorrhage: A Single-Centre Experience

Ashesh Dhungana<sup>1</sup>, Prajowl Shrestha<sup>1</sup>

<sup>1</sup>Pulmonary Medicine, National Academy of Medical Sciences, Kathmandu, Nepal.

## ABSTRACT

**Introduction:** Diffuse alveolar hemorrhage results from an accumulation of red blood cells into the alveolar space. Symptoms of alveolar hemorrhage are dyspnea, hemoptysis, anemia, diffuse pulmonary infiltrates and hypoxemic respiratory failure. Diagnosis is established by bronchoalveolar lavage and treatment includes a combination of high dose systemic corticosteroids, immunosuppressant and plasma exchange. The aim of this study is to evaluate the clinical-radiological profile and laboratory findings and utility of bronchoalveolar lavage in the diagnosis of diffuse alveolar hemorrhage.

**Materials and Methods:** In a retrospective review between February 2017 and December 2017, medical records of patients with a diagnosis of diffuse alveolar hemorrhage presenting at the National Academy of Medical Sciences, Kathmandu, Nepal, were analyzed. Clinical, radiology and laboratory results along with bronchoalveolar lavage results were extracted. Treatment received and clinical responses were evaluated.

**Results:** A total of five patients were diagnosed to have diffuse alveolar hemorrhage based on bronchoalveolar lavage analysis. Three had hemorrhage secondary to Antineutrophil Cytoplasmic Antibody associated vasculitis, one had Systemic Lupus Erythematosus and the other Idiopathic Pulmonary Hemosiderosis. Renal involvement was present in three patients. All patients received systemic corticosteroids, three received Cyclophosphamide and one Rituximab for remission induction. Plasma exchange was done in two patients with severe hypoxemia. Of the five patients, four improved whereas one died.

**Conclusions:** Diffuse alveolar hemorrhage presents with non-specific symptoms. Bronchoalveolar lavage is extremely useful to establish the diagnosis and exclude infections. Early initiation of immunosuppressant prevents respiratory failure and death.

**Keywords:** Alveolar; ANCA; Bronchoalveolar lavage; Collagen vascular disease; Vasculitis

### Correspondence:

Dr. Ashesh Dhungana MD, DM  
Assistant Professor, Pulmonary Medicine,  
Department of Medicine,  
National Academy of Medical Sciences, Kantipath,  
Kathmandu, Nepal.  
ORCID ID: 0000-0003-2656-4405  
Email: asheshdhungana12@gmail.com

**Submitted :** 28<sup>th</sup> September 2019

**Accepted :** 15<sup>th</sup> November 2019



**Source of Support:** None

**Conflict of Interest:** No

**Citation:** Dhungana A, Shrestha P. Diffuse alveolar hemorrhage: a single-center experience. NMJ 2019;2 (2):229-33. DOI 10.3126/nmj.v2i2.25828

## INTRODUCTION

Diffuse alveolar hemorrhage (DAH) is a rare disorder resulting from an accumulation of red blood cells originating from capillaries into the alveolar space.<sup>1</sup> In immune-mediated disorders such as systemic vasculitis and collagen vascular diseases; capillaritis in pulmonary microcirculation is the characteristic feature.<sup>2,3</sup> Capillaritis is absent in DAH caused by drugs, coagulopathy, infections and anti Glomerular Basement Membrane (GBM) antibody syndrome. DAH usually presents with one or more symptoms of dyspnea, hemoptysis, anemia and diffuse pulmonary infiltrates which can rapidly progress to hypoxemic respiratory failure and death.<sup>3-5</sup> Diagnosis is established by Bronchoalveolar

Lavage (BAL) and lung biopsy.<sup>6-8</sup> Anti Nuclear Antibody (ANA), Anti double-stranded deoxyribonucleic acid (dsDNA), Anti Neutrophil Cytoplasmic Antibody (ANCA), Anti GBM antibody tests are used to establish the etiology. A kidney biopsy is required if concomitant renal involvement is present.

The aim of this study was to evaluate the clinical-radiological profile and laboratory findings and utility of bronchoalveolar lavage in the diagnosis of diffuse alveolar hemorrhage in our setting.

## MATERIAL AND METHODS

This is a retrospective study conducted at the National Academy of Medical Sciences, Kathmandu, Nepal from February 2017 to December 2017. Ethical clearance was obtained from the Institutional Ethics Committee. Outpatient and inpatient medical records of patients with a diagnosis of DAH presenting to the respiratory clinic were reviewed. Clinical, radiology and laboratory results along with Bronchoscopy and BAL results were extracted and analyzed. Treatment received and clinical responses were evaluated.

In patients with clinical suspicion of alveolar hemorrhage, HRCT chest was done to identify the affected lobes and segments. Bronchoscopies were performed in the bronchoscopy suite of the National Academy of Medical Sciences, Bir Hospital. During bronchoscopy, the bronchoscope was wedged into the involved segment(s) and serial aliquots of 20-40 ml saline were instilled. The return fluid from each aliquot was collected in separate containers and sent for cytopathology and iron staining. The presence of hemosiderin-laden macrophages in the BAL specimen was the defining criteria to diagnose DAH. Bacterial culture, fungal culture, AFB stain and Xpert MTB Rif assay for Mycobacterium tuberculosis were routinely performed on BAL fluid. Transbronchial Lung Biopsy (TBLB) was done if

feasible. ANA, Anti dsDNA, Anti Proteinase 3 (PR3) ANCA and Myeloperoxidase (MPO)ANCA tests were done in all patients. Urinalysis and renal function tests were routinely performed. Kidney biopsy was done if renal involvement was evident from laboratory results. Outcome assessment such as improvement in oxygenation, cessation of hemorrhage and improvement of renal function was done at the time of discharge and subsequent follow up at three months. A descriptive analysis was performed using Microsoft Excel.

## RESULTS

During the study period, a total of five patients were diagnosed to have DAH based on clinical, radiology, laboratory and BAL results (Table 1). Three had DAH secondary to ANCA vasculitis (Granulomatosis with Polyangiitis- 2 cases and Microscopic Polyangiitis- 1 case), 1 patient had Systemic Lupus Erythematosus (SLE) and other had Idiopathic Pulmonary Hemosiderosis (IPH). Renal involvement was present in three patients. All patients were treated with systemic corticosteroids; three received Cyclophosphamide and one Rituximab for remission induction. In two patients plasma exchange was also done as they had severe hypoxemia at presentation. Four patients had a favorable response to treatment; one required mechanical ventilation and succumbed to refractory hypoxemia.

**Table 1: Clinical, laboratory results, treatment, and outcomes in patients with Diffuse Alveolar Hemorrhage**

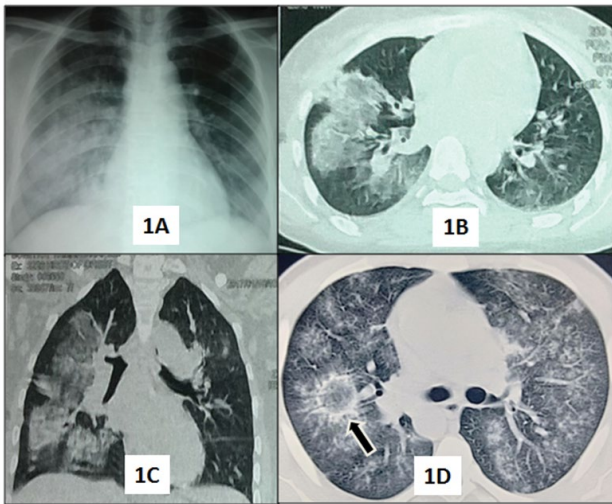
Age/ Sex	Presentation	Serological Tests	Bronchoalveolar Lavage (BAL)	Other Investigations	Final Diagnosis	Treatment	Outcome
Case 1 22/F	Exertional Dyspnea, Hemoptysis	ANA +ve Anti dsDNA +ve Low C3 MPO ANCA -ve, PR3 ANCA -ve.	Hemosiderin Laden Macrophage	Hb = 8.6 gm% Urine Albumin 2+ Kidney Biopsy: Class III A/C lupus nephritis	Systemic Lupus Erythematosus	I.V. Methylprednisolone, Cyclophosphamide, Plasma Exchange	Improved
Case 2 35/F	Exertional Dyspnea, Dry cough	ANA -ve, Anti dsDNA -ve, MPO ANCA -ve, PR3 ANCA -ve.	Hemosiderin Laden Macrophage	Hb = 9.2 gm%, Low Ferritin, Raised TIBC TBLB: Bland hemorrhage, no capillaritis.	Idiopathic Pulmonary Hemosiderosis	Oral Corticosteroids	Improved
Case 3 17/F	Exertional Dyspnea, Fever, Hemoptysis	ANA -ve, Anti dsDNA -ve, PR3 ANCA +ve MPO ANCA -ve.	Hemosiderin laden Macrophage	Hb = 6.2 gm%, Urine Albumin nil, No active sediments.	Granulomatosis with Polyangiitis (Lung limited)	I.V. Methylprednisolone, Rituximab, Oral Corticosteroids	Improved
Case 4 27/M	Exertional Dyspnea, Hemoptysis	ANA -ve, Anti dsDNA -ve PR3 ANCA +ve, MPO ANCA -ve.	Hemosiderin laden Macrophage	Hb = 7 gm%, Serum creatinine 2 mg%, Urine Albumin 1+, No active sediments	Granulomatosis with Polyangiitis	I.V. Methylprednisolone, Cyclophosphamide, Plasma Exchange, Mechanical Ventilation	Deceased
Case 5 28/F	Exertional Dyspnea, Cough	ANA -ve, Anti dsDNA -ve, MPO ANCA +ve, PR3 ANCA -ve.	Hemosiderin laden Macrophage	Hb = 10.4 gm%. Urine Albumin 1+ Kidney Biopsy: 30% Crescent	Microscopic Polyangiitis	I.V. Methylprednisolone, Cyclophosphamide, Oral Corticosteroids	Improved

C3: Complement 3, Hb: Hemoglobin, TIBC: Total Iron Binding Capacity

### # CASE 1


A 22 years-lady presented with dyspnea on exertion and hemoptysis of a two-week duration. Oxygen saturation on room air was 89% and bilateral crepitations were heard on auscultation. On chest X-ray fluffy alveolar opacities were present in the

bilateral middle and lower zones (fig. 1A). HRCT revealed patchy areas of consolidation and ground-glass opacities (Fig. 1B,C).

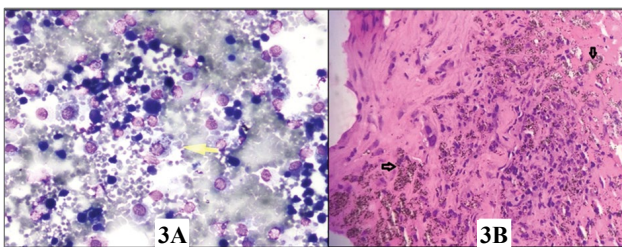


**Figure 1A:** Chest X-ray showing bilateral alveolar opacities. **1B, C:** HRCT showing bilateral areas of consolidation and ground-glass opacities. **1D:** HRCT with areas of central ground-glass opacity surrounded by crescentic areas of consolidation, the 'reverse halo sign' (arrow)

Her Hb was 8.6 gm % and titers of ANA and Anti dsDNA were raised. The serum complement level was low (22 mg/dL). Anti GBM antibody, Anti MPO and Anti PR3 ANCA tests were negative. Urine routine examination revealed 2+ proteinuria with the absence of dysmorphic RBC's. The serum creatinine was 3.2 mg/dL. Bronchoscopic BAL was performed which revealed a progressive increase in the hemorrhagic return in serial aliquots (fig. 2).



**Figure 2:** Bronchoalveolar Lavage in a patient with Diffuse Alveolar Hemorrhage. Serial aliquots (labeled 1 to 5) show increasing hemorrhagic return.



**Figure 3:** Cytopathology and Histopathology in Diffuse Alveolar Hemorrhage in the same patient. **3A:** BAL cytology reveals plenty of RBC's and hemosiderin-laden macrophage. **3B:** Bronchoscopic lung biopsy shows mild fibrosis with numerous siderophages filling the alveolar space (arrow).

Cytology revealed the presence of plenty of haemosiderin laden alveolar macrophages (fig. 4A). Bacterial cultures, fungal cultures, and Xpert MTB Rif assay tests were negative. Renal biopsy showed focal segmental necrotizing vasculitis with the presence of granular immune deposits of IgG, IgM, C3 and C1q. A final diagnosis of SLE with Class III A/C lupus nephritis and DAH was made.

She was treated with intravenous Methylprednisolone 1gm for 3 days followed by oral Prednisolone. Cyclophosphamide was started at a dose of 2mg/kg. Plasma exchange was done on alternate days. After six sessions of plasma exchange, there was a significant clinical resolution of dyspnea and hemoptysis. The patient was discharged on Prednisolone and Cyclophosphamide. At three months follow up, renal functions normalized and chest infiltrates disappeared.

### # CASE 2

A 35 years-lady presented with a six-month history of progressive dyspnea and dry cough. There was no fever, weight loss or hemoptysis. She did not have any skin lesions or joint symptoms. Oxygen saturation on room air was 94 percent. She had a hemoglobin of 9.2 gm% and peripheral blood smear revealed microcytic and hypochromic RBCs. Serum ferritin was low and total iron-binding capacity was raised. Antigliadin antibodies were absent. Kidney function tests were normal and there was no proteinuria or dysmorphic RBC's in the urine. ANA, Anti dsDNA, Rheumatoid factor, ANCA and ENA tests were negative. The anti-GBM antibody was negative. Transthoracic echocardiography revealed no cardiac pathology. HRCT thorax revealed bilateral areas of ground-glass opacities and consolidation with air bronchogram. BAL was performed from bilateral lower lobes which revealed the presence of hemosiderin-laden macrophages. BAL fluid cultures, AFB stain and Xpert MTB Rif assay were negative. Transbronchial lung biopsy revealed normal alveolar lining epithelium with numerous siderophages filling the alveolar space (fig 3B). Biopsy showed no evidence of inflammation, granuloma or vasculitis. Since the patient had an alveolar hemorrhage in the absence of pulmonary capillaritis, serological evidence of vasculitis or renal involvement, a diagnosis of Idiopathic Pulmonary Hemosiderosis was made. She was initiated on oral Prednisolone and iron supplements. Prednisolone was started at a dose of 1mg/kg/day tapered over 6 weeks to a maintenance dose of 10mg/day. There was a significant improvement in dyspnea and resolution of chest infiltrates on radiology.

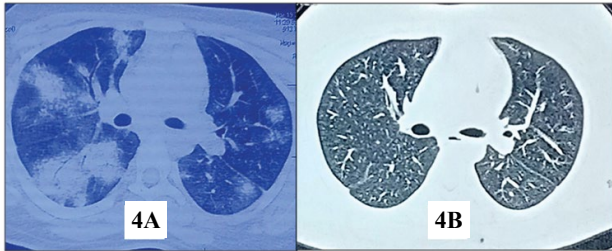
### # CASE 3

A 17 years-female presented with dyspnea, hemoptysis and fever of 10-day duration. She had resting hypoxemia (SaO<sub>2</sub> = 88%) and required oxygen supplementation. Chest auscultation revealed bilateral crackles. Hemoglobin was 6.2gm%, kidney function tests and urinalyses were normal. A chest X-ray showed bilateral consolidation. HRCT chest revealed bilateral areas of patchy consolidation and air bronchogram (fig. 4A). BAL performed from the right lower lobe showed increasing hemorrhage in subsequent aliquots. BAL fluid cytology revealed plenty of RBC's and hemosiderin-laden macrophages. Bacterial, fungal cultures, AFB stain and Gene Xpert tests were negative in BAL fluid. ANA and Anti dsDNA titers were normal. The titers of Anti PR3-ANCA were raised whereas Anti MPO-ANCA was



normal. A diagnosis of lung limited Granulomatous Polyangiitis (GPA) with DAH was made.

Intravenous Methylprednisolone 1 gm/day and plasma exchange were started immediately. Remission induction was achieved with Rituximab at a dose of 500mg weekly for 4 weeks. Hypoxia improved and the patient was discharged on a maintenance regimen of oral Prednisolone and 6 monthly Rituximab. HRCT repeated at 3 months showed complete resolution of lung lesions (fig. 4B)



**Figure 4:** Radiological response to treatment in DAH. HRCT images pre-treatment (4A) and post-treatment (4B) in a patient with Granulomatous Polyangiitis and DAH.

#### # CASE 4

A 27 years-male presented with dyspnea, cough and hemoptysis of 28 days duration. Room air saturation was 80%, hence required high flow oxygen supplementation. Hemoglobin was 7.0 gm% and serum creatinine was 2 mg/dL. Urine examination showed 1+ proteinuria. HIV serology was negative. CT chest showed bilateral areas of ground-glass opacities and consolidation and at areas the central ground-glass opacity surrounded by crescentic areas of consolidation; 'reverse halo sign' (fig.1D). Bronchoscopy could not be performed as the patient had severe hypoxia. A kidney biopsy was planned after the correction of anemia. Anti PR-3 ANCA titers were raised, anti-MPO-ANCA, ANA and dsDNA were negative. The patient's hypoxemia continued to worsen and was intubated on day 3 of admission. A non-bronchoscopic BAL was performed after intubation which revealed plenty of hemosiderin-laden macrophages on the iron stain. A diagnosis of Granulomatous Polyangiitis with pulmonary and renal involvement and DAH was made. He was started on pulse Methylprednisolone, Cyclophosphamide and plasma exchange. The patient developed refractory hypoxemia and succumbed to his illness on day 6 of admission.

#### # CASE 5

A 28 year-female presented with exertional dyspnea and cough for 3 weeks. Her hemoglobin was 10.4 gm%. Urinalysis revealed 1+ proteinuria and 3-5 RBC's per high power field. Serum creatinine was 1.8 mg%. HRCT chest showed bilateral multifocal consolidation and ground-glass opacities. Bronchoscopic lavage showed increasing hemorrhagic returns of aliquots and cytology revealed plenty of hemosiderin-laden macrophage on the iron stain. ANA and Anti dsDNA titers were normal whereas antiMPO-ANCA was raised and antiPR3-ANCA negative. Kidney biopsy was done which showed crescentic glomerulonephritis. A diagnosis of Microscopic Polyangiitis (MPA) with DAH was made and the patient was given i.v. Methylprednisolone and Cyclophosphamide 15mg/kg. The patient had a favorable response to immunosuppressants and was

discharged on oral corticosteroids and monthly maintenance of iv. Cyclophosphamide. She remained on remission at 3 months of Cyclophosphamide therapy.

## DISCUSSION

The diagnosis of DAH is often challenging. In an appropriate clinical setting, DAH should be suspected in all patients presenting with dyspnea, hemoptysis, chest infiltrates and anemia.<sup>1</sup> Dyspnea, which is a nonspecific symptom in DAH, was present in all our patients. In severe cases, hypoxemia and respiratory failure may occur. Three of our patients had hypoxemia requiring oxygen supplementation and one required mechanical ventilation. Although hemoptysis is a more specific symptom, it may be absent in a third of patients with DAH.<sup>5</sup> In our series, two of the five (40%) patients did not have hemoptysis. Fever and chest pain are other nonspecific and uncommon symptoms.

ANCA vasculitis and collagen vascular disorders are the commonest cause of DAH and should be tested in all cases. The reported incidence of ANCA vasculitis in DAH is 40%.<sup>9</sup> In our series three (60%) had raised titers of ANCA. Granulomatosis with Polyangiitis (GPA) usually demonstrates raised titers of ANCA directed against cytoplasmic proteinase 3 (antiPR3-ANCA) whereas Microscopic Polyangiitis is characterized by the presence of perinuclear ANCA directed against neutrophil myeloperoxidase (antiMPO-ANCA). Idiopathic Pulmonary Hemosiderosis is a rare genetic disorder that causes recurrent alveolar hemorrhage and iron deficiency anemia. It should be suspected in the absence of other system involvement, negative serological tests for collagen vascular diseases, vasculitis and anti-GBM Antibody.

Bronchoalveolar lavage is essential in all cases of DAH.<sup>8</sup> It can establish the diagnosis of alveolar hemorrhage and also exclude other causes of chest infiltrate. When sequential lavage is performed in patients with DAH, the subsequent aliquots are more hemorrhagic as the return from the distal and the number of alveoli increases. Cytopathology reveals hemosiderin on iron stain as RBC's in the alveoli are engulfed by the resident alveolar macrophage. Hemosiderin laden macrophage may be demonstrated 48-72 hours after the onset of hemorrhage and a cutoff of more than 20% has high sensitivity and specificity for the diagnosis of DAH.<sup>5,6</sup> In our series; lavage was performed in all cases. In four patients bronchoscopy was performed, whereas in one severe hypoxia precluded bronchoscopy. Hence a non-bronchoscopic lavage was performed after intubation. Bronchoscopy can also be used to obtain lung biopsy which may or may not show the presence of capillaritis depending on the underlying cause of DAH.<sup>10</sup> Bronchoscopic lung biopsy was performed in one of our patients.

Acute pulmonary edema and opportunistic infections closely resemble the radiological appearance of DAH. Bacterial, fungal and tubercular infections need to be excluded by BAL fluid analysis in all cases. Bacterial, fungal cultures and MTB Xpert/Rif assay were negative in all our patients. Treatment of DAH depends on the severity of hemorrhage and underlying etiology. When capillaritis is present or evidence of underlying systemic vasculitis or collagen vascular disorder is documented, immediate treatment with immunosuppressive agents is imperative. The standard treatment is a combination of intravenous

Methylprednisolone and Cyclophosphamide.<sup>11,12</sup> Rituximab, a monoclonal antibody against CD20 positive B lymphocytes, can also be used in systemic vasculitis and unlike Cyclophosphamide does not cause ovarian failure or infertility.<sup>13</sup> We used pulse corticosteroids in four of our patients who had immune-mediated injury with DAH. In addition, Cyclophosphamide was given to three patients and Rituximab to one for induction of remission. Plasma exchange is an adjunctive treatment of DAH in immune-mediated injury if severe hypoxemia is present.<sup>14</sup> It rapidly clears the immune complexes from the circulation and improves hypoxia. Two of our patients received plasma exchange. Idiopathic Pulmonary Hemosiderosis is treated with systemic corticosteroids with or without other immunosuppressant.<sup>15</sup>

DAH is often misdiagnosed as radiology mimics other alveolar filling processes such as infection and pulmonary edema. The low index of suspicion is another cause of delayed diagnosis. In all our patients, BAL cytology was promptly performed to confirm the presence of alveolar hemorrhage. The underlying cause of DAH was extensively evaluated. Serological tests for vasculitis, collagen vascular disorders, Anti GBM antibody syndrome were done in all patients. Lung and kidney biopsy was performed when indicated. All alternate diagnoses were excluded after microbiology and cytology tests of lavage fluid.

## REFERENCES

- Lara AR, Schwarz MI. Diffuse alveolar hemorrhage. *Chest*. 2010;137(5):1164–71. [Crossref](#)
- Ioachimescu OC, Stoller JK. Diffuse alveolar hemorrhage: diagnosing it and finding the cause. *Cleve Clin J Med*. 2008;75(4):264–5. [Crossref](#)
- Lauque D, Cadranel J, Lazor R, Pourrat J, Ronco P, Guillevin L, et al. Microscopic polyangiitis with alveolar hemorrhage. A study of 29 cases and review of the literature. *Grouped'Etudeset de Recherchesur les Maladies "Orphelines" Pulmonaires (GERM"O"P)*. *Medicine (Baltimore)* 2000; 79:222-33. [Crossref](#)
- De Prost N, Parrot A, Picard C, Ancel P-Y, Mayaud C, Fartoukh M, et al. Diffuse alveolar haemorrhage: factors associated with in-hospital and long-term mortality. *Eur Respir J*. 2010 Jun;35(6):1303–11. [Crossref](#)
- Quadrelli S, Dubinsky D, Solis M, Yucra D, Hernandez M, Karlen H, et al. Immune diffuse alveolar hemorrhage: clinical presentation and outcome. *Respir Med* 2017;129:59–62. [Crossref](#)
- Pérez-Arellano JL, LosaGarcía JE, GarcíaMacías MC, Gómez Gómez F, Jiménez López A, de Castro S. Hemosiderin-laden macrophages in bronchoalveolar lavage fluid. *Acta Cytol*. 1992;36(1):26–30. [Crossref](#)
- De Lassence A, Fleury-Feith J, Escudier E, Beaune J, Bernaudin JF, Cordonnier C. Alveolar hemorrhage. Diagnostic criteria and results in 194 immunocompromised hosts. *Am J Respir Crit Care Med* 1995;151(1):157–63. [Crossref](#)
- Meyer KC. Bronchoalveolar lavage as a diagnostic tool. *SeminRespirCrit Care Med*. 2007 Oct;28(5):546–60. [Crossref](#)
- Travis WD, Colby TV, Lombard C, Carpenter HA. A clinicopathologic study of 34 cases of diffuse pulmonary hemorrhage with lung biopsy confirmation. *Am J SurgPathol*. 1990 ; 14 ( 12 ): 1112 - 1125. [Crossref](#)
- Schnabel A, Holl-Ulrich K, Dalhoff K, Reuter M, Gross WL. Efficacy of transbronchial biopsy in pulmonary vasculitides. *Eur Respir J*. 1997;10:2738–2743. [Crossref](#)
- Yates M, Watts RA, Bajema IM, Cid MC, Crestani B, Hauser T, et al. EULAR/ERA-EDTA recommendations for the management of ANCA-associated vasculitis. *Ann Rheum Dis* 2016;75: 1583–1594. [Crossref](#)
- Kazzaz NM, Coit P, Lewis EE, McCune WJ, Sawalha AH, Knight JS. Systemic lupus erythematosus complicated by diffuse alveolar haemorrhage: risk factors, therapy and survival. *Lupus Sci Med*. 2015;2(1):e000117. [Crossref](#)
- Stone JH, Merkel PA, Spiera R, Seo P, Langford CA, Hoffman GS, et al; RAVE-ITN Research Group. Rituximab versus cyclophosphamide for ANCA-associated vasculitis. *N Engl J Med* 2010;363(03):221–32. [Crossref](#)
- Klemmer PJ, Chalermkulrat W, Reif MS, Hogan SL, Henke DC, Falk RJ. Plasmapheresis therapy for diffuse alveolar hemorrhage in patients with small-vessel vasculitis. *Am J Kidney Dis* 2003 42(06):1149–53. [Crossref](#)
- Chen XY, Sun JM, Huang XJ. Idiopathic pulmonary hemosiderosis in adults: review of cases reported in the latest 15 years. *ClinRespir J* 2017; 11:677. [Crossref](#)

## CONCLUSIONS

DAH usually presents with nonspecific symptoms. It should be suspected and evaluated promptly in patients with systemic vasculitis and collagen vascular disorders. BAL is extremely useful to establish a diagnosis of DAH and exclude infections. Early initiation of systemic corticosteroids, immunosuppressant and plasma exchange in severe cases can prevent the devastating complications associated with this condition.

Acknowledgment: We would like to thank Dr. Pratikchya Karki and the Department of Pathology at the National Academy of Medical Sciences, Bir hospital for helping us extract pathology images of the cases included in the study.