

Case Reports

Mesenchymal Chondrosarcoma: A Rare Aggressive Variant of Chondrosarcoma

Adarsh Kumar Jhunjhunwala¹, Arnab Ghosh¹, Manish Kiran Shrestha², Dilashma Ghartimagar¹, Binod Dhakal³, Sushma Thapa¹, Sudeep Regmi¹

¹Department of Pathology, Manipal College Of Medical Sciences, Pokhara, Nepal

²Department of Radiology, Charak Memorial Hospital, Pokhara, Nepal.

³Department of Pathology, Kathmandu University School Of Medical Sciences, Dhulikhel, Nepal

ABSTRACT

A 15-year-old boy reported a 2-month history of severe left thigh pain. Physical examination revealed left thigh swelling measuring 6x5 cm. X-ray of the region showed mixed lytic and sclerotic lesion involving the femoral head and neck. A Computed Tomography scan showed mixed lytic and sclerotic lesion involving the femoral head and neck with cortical irregularity and mild periosteal reaction with associated soft tissue in the anterior aspect. Magnetic resonance imaging demonstrated heterogeneous signal intensity lesion with areas of sclerosis involving the femoral head and neck. The large associated soft tissue in the anterior aspect appears predominantly hyperintense on T2W images. On post-contrast axial and sagittal images, heterogeneous enhancement with areas of necrosis involving soft tissue was seen. A presumptive radiological differential diagnosis of Ewing Sarcoma and Osteosarcoma was made. However, on histopathology, it was a case of mesenchymal chondrosarcoma.

Keywords: Chondrosarcoma; Ewing sarcoma; Heterogenous enhancement; Mesenchymal chondrosarcoma; Osteosarcoma

Correspondence:

Dr. Adarsh Kumar Jhunjhunwala, MD
Lecturer, Department of Pathology
Manipal College of Medical Sciences, Pokhara, Nepal
ORCID ID: 0000-0001-5501-5849
Email: dr.adarshjhunjhunwala@gmail.com

Submitted: 5th November 2020

Accepted: 18th December 2020

Source of Support: None
Conflict of Interest: None



Citation: Jhunjhunwala AK, GhoshA, Shrestha MK, Ghartimagar D, Dhakal B, Thapa S, Regmi S. Mesenchymal chondrosarcoma: a rare aggressive variant of chondrosarcoma. *NMJ* 2020;3(2):388-91. DOI 10.3126/nmj.v3i2.35048

INTRODUCTION

Mesenchymal Chondrosarcoma (MCS), first described by Lichtenstein and Bernstein¹ in 1959 is a rare tumor representing less than 4% of all chondrosarcomas.²⁻⁵ Mesenchymal chondrosarcoma is a poorly understood entity and the only consistently described features of MCS are the unique, biphasic histology and the poor prognosis, despite variable lengths of disease-free survival.⁴

The rarity of this tumor leads to substantial diagnostic, prognostic, and management challenges. In this case report, we present the characteristic clinical, radiographic, and histopathologic features of MCS seen in a 15 years old patient.

CASE REPORT

A 15 years-old male patient presented in March 2014 with a complaint of a painful left hip joint and upper thigh for the past 2 months. On examination, a firm vertically hemi-ellipsoid swelling in the upper left thigh involving the left hip was observed. There was no regional lymphadenopathy or neurovascular deficit. Complete blood count and routine biochemical analysis were normal. X-ray of the region showed mixed lytic and sclerotic lesion involving the femoral head and neck (fig.1A). A Computed Tomography (CT) scan showed mixed lytic and sclerotic lesion involving the femoral head and neck with cortical irregularity and mild periosteal reaction with associated soft tissue in the anterior aspect

(fig. 1B). Magnetic Resonance Imaging (MRI) demonstrated heterogeneous signal intensity lesion with areas of sclerosis involving the femoral head and neck. The large associated soft tissue in the anterior aspect appears predominantly hyperintense on T2W images (fig. 2A). On the post-contrast axial (2B) and sagittal (2C) image, heterogeneous enhancement with areas of necrosis involving soft tissue was seen.

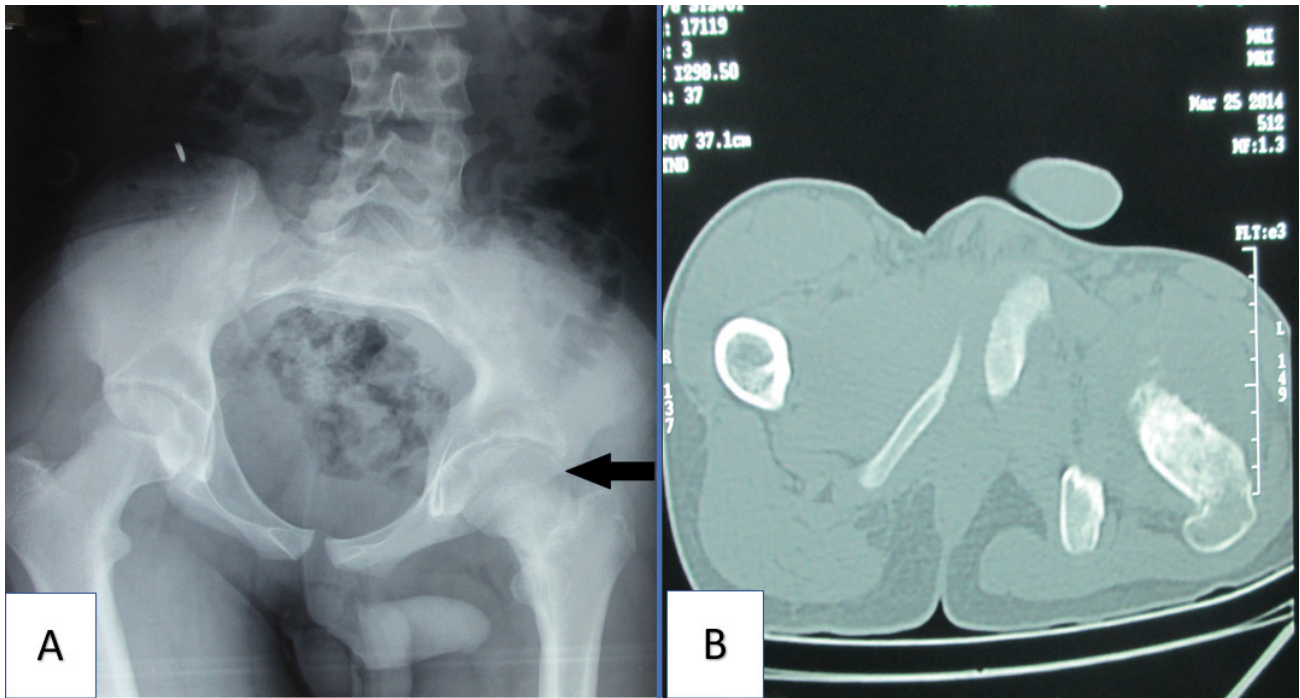


Figure 1A: Radiograph of hip joint shows mixed lytic and sclerotic lesion involving the femoral head and neck.

Figure 1B: CT scan shows mixed lytic and sclerotic lesion involving the femoral head and neck with cortical irregularity and mild periosteal reaction with associated soft tissue in anterior aspect. No calcification and ossification were seen.

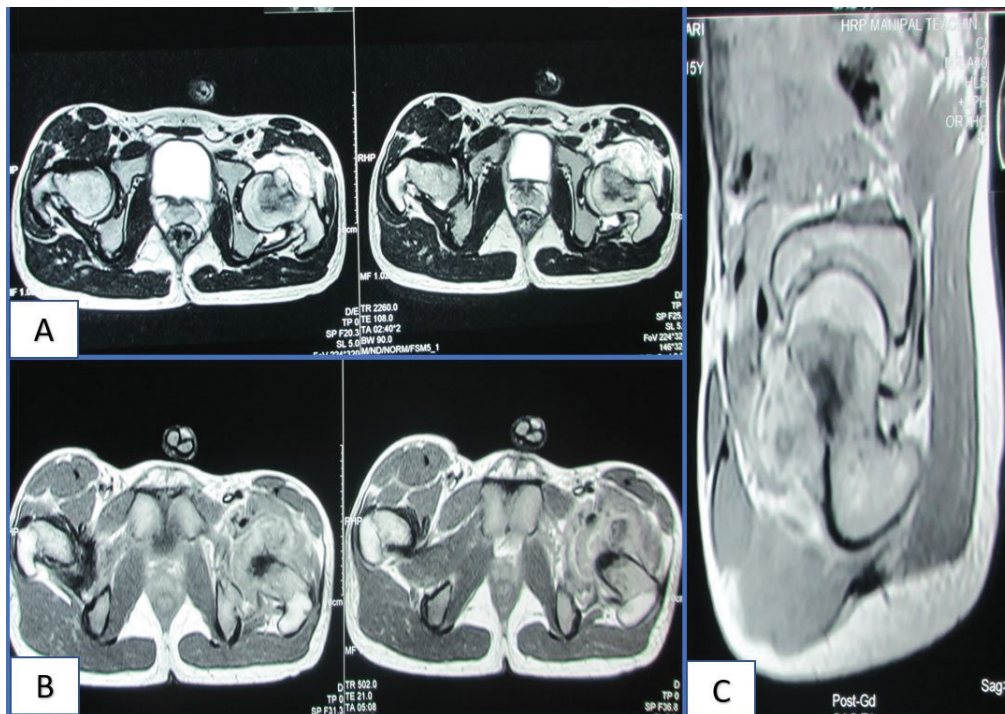


Figure 2: MRI T2W images show heterogeneous signal intensity lesion with areas of sclerosis involving the femoral head and neck. The large associated soft tissue in the anterior aspect appears predominantly hyperintense on T2W images (A). Post-contrast axial (B) and sagittal (C) images show heterogeneous enhancement with areas of necrosis involving soft tissue.

The patient underwent surgical excision. Multiple bits of pale white to dark white tissue altogether measuring 4.5 cm was received for histopathology. On microscopic examination of Hematoxylin and Eosin stained slides, a tumor was observed composed of islands of cartilage containing malignant chondrocytes and juxtaposed with a small round to oval tumor cells arranged in sheets. Tumor cells were small and had mild to moderate pleomorphism, a scant amount of cytoplasm, and round to oval hyperchromatic nuclei. Hemangiopericytoma-like vascular proliferation was seen admixed with tumor cells. The chondroid islands were also noted with multinucleated tumor giant cells, occasional areas of osteoid matrix, and calcification. A histopathological diagnosis of MCS was given. (fig3 A- D)

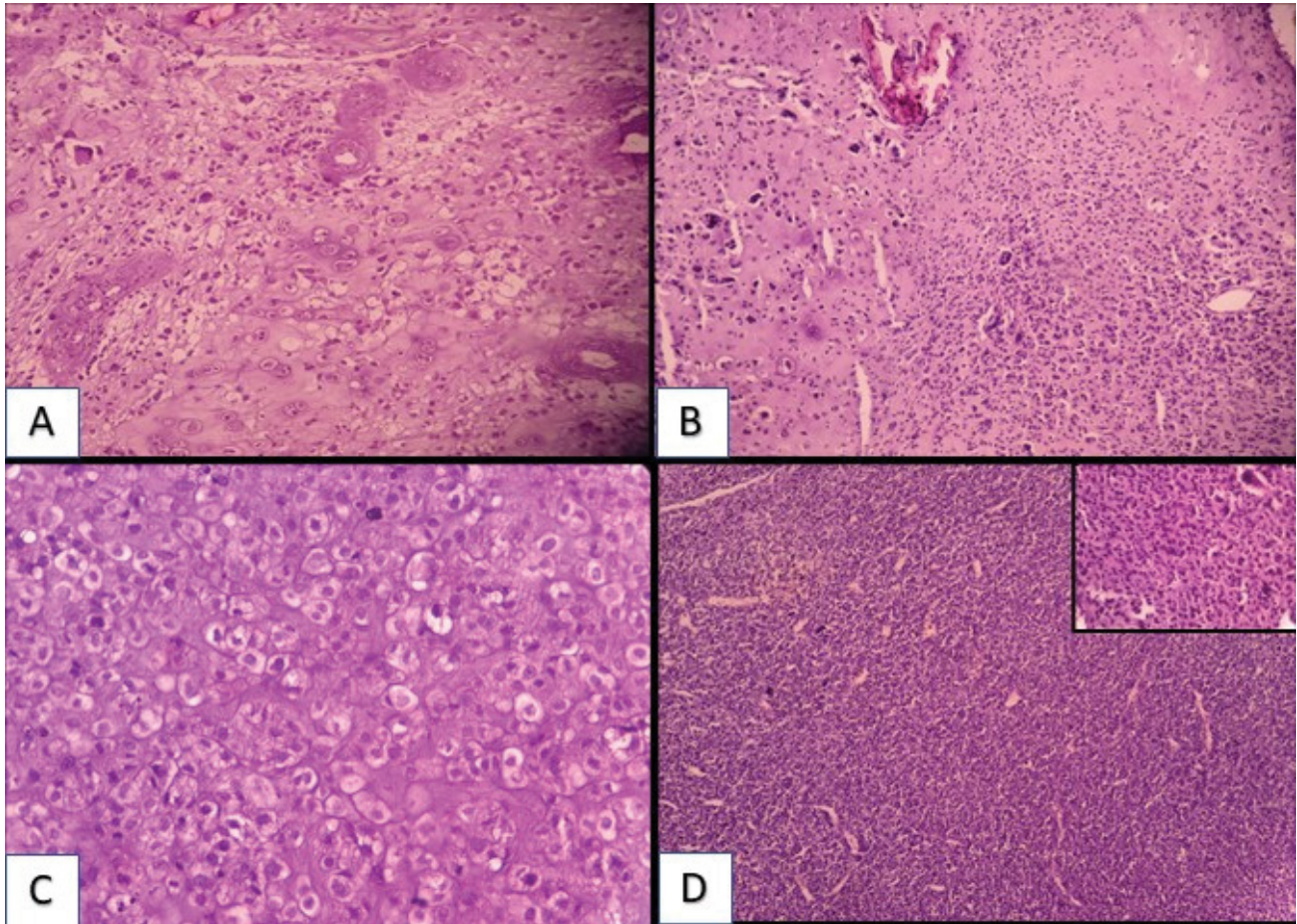


Figure 3: A) Lobules of malignant cartilage with areas with vascular proliferation B) Lobule of cartilage containing malignant chondrocytes surrounded by malignant tumor cells with areas of vascular proliferation. Also seen are multinucleated giant cells and coarse calcification of cartilaginous lobule. C) Malignant chondrocytes on high power. D) Small malignant cells with areas of hemangiopericytoma like vascular proliferation. An inset on top shows high power image of malignant tumor cells

After the histopathological diagnosis was given, the patient underwent chemotherapy and radiotherapy. Though the patient had pulmonary metastasis three years back for which the patient underwent surgical excision, the patient is doing well as of October 2020.

DISCUSSION

Classical Chondrosarcoma (CC) is the second most common sarcoma of bone.² It includes a heterogeneous group of neoplasms characterized by the production of a cartilage matrix. Chondrosarcoma has a classic intramedullary origin, however extra skeletal origin is not uncommon. MCS differs from CC as to its rarity, age distribution, aggressiveness, and a higher percentage of extraskeletal tumors. The MCS is a rare tumor and accounts for only 2% to 4% of all chondrosarcomas.²⁻⁵ MCS classically occurs in young adults i.e in second and third decades of life,⁴ whereas

most CC patients are >50 years old. MCS has a 10-year survival rate far below 50%,³⁻⁸ while most CC has a more favorable prognosis. About 1/3 of MCS occur in soft tissues, whereas extraskeletal CC account for <1% of all CC.⁹⁻¹¹ In the case series by Nakashima Y. et al. of 111 cases of MCS 72(64.86%) tumors were in bone, 38(34.23%) in nonskeletal tissues, and 1(0.01%) in both bone and soft tissue. Amongst the skeletal sites most common site for MCS is pelvic bones followed by femur, humerus, vertebra, mandible, and skull.⁴ The radiographic appearance is largely not specific and is, at times, variable. Lesions are characteristically osteolytic and locally destructive, with soft tissue extension and finely stippled calcification.³ The radiological findings of this case showed similar features.

The histology of MCS shows a paradoxical histological picture of highly cellular zones composed of anaplastic small cells along with islands of relatively hypocellular chondroid areas. These islands may be calcified or even ossified. The cellular

areas with anaplastic small cells may show vascular proliferation with a hemangiopericytoma-like pattern. The diagnosis is more readily apparent if both components are present. The current case showed the classical findings of both the components. The absence of cartilage in the biopsy sample can cause this tumor to be confused with other small, round, blue-cell tumors. Furthermore, the cartilage can be the predominant pattern with small malignant cells between the lobules leading to an erroneous diagnosis of conventional chondrosarcoma. A differential diagnosis of small cell osteosarcoma can be made erroneously if the chondroid islands have undergone ossification however, the very characteristic low-grade appearing cartilaginous foci and typical nuclear morphology should suggest MCS. The other histologic differential diagnosis for MCS includes Ewing sarcoma, lymphoma, neuroblastoma, desmoplastic small round cell tumor and small cell osteosarcoma.^{6,12,13}

Prognosis and grading

Although there are typically no tumor necrosis and the mitotic count is relatively low, MCS is classified as grade 3 in the

grading systems of the French Federation of Cancer Centers Sarcoma Group (FNCLCC) and the National Cancer Institute.¹⁴ This classification is based on its highly malignant clinical behavior, and frequent but late local and metastatic recurrences leading to poor long-term outcomes. Much of the current knowledge about the clinical course of MCS was gained from the largest retrospective series published in 1986, which included information on the treatment of 78 patients with adequate follow-up. Thirty-seven of these patients had been treated with radiation, chemotherapy, or both after the initial surgery.⁴

CONCLUSIONS

The current case report highlights that MCS is an entity to be considered in young patients presenting with tumors mimicking chondrosarcoma or osteosarcoma as MCS has a worse prognosis compared to both.

REFERENCES

- Lichtenstein L, Bernstein D. Unusual benign and malignant chondroid tumors of bone. A survey of some mesenchymal cartilage tumors and malignant chondroblastic tumors, including a few multicentric ones, as well as many atypical benign chondroblastomas and chondromyxoid fibromas. *Cancer*. 1959;12(6):1142-57. [Crossref](#)
- Larsson SE, Lorentzon R. The geographic variation of the incidence of malignant primary bone tumors in Sweden. *J Bone Joint Surg Am*. 1974;56(3):592-600. [Website](#)
- Huvos AG, Rosen G, Dabska M, Marcove RC. Mesenchymal chondrosarcoma: a clinicopathologic analysis of 35 patients with emphasis on treatment. *Cancer*. 1983;51(7):1230 - 7. [Crossref](#)
- Nakashima Y, Unni KK, Shives TC, Swee RG, Dahlin DC. Mesenchymal chondrosarcoma of bone and soft tissue. A review of 111 cases. *Cancer*. 1986;57(12):2444-53. [Crossref](#)
- Fanburg-Smith JC, Auerbach A, Marwaha JS, Wang Z, Santi M, et al. Immunoprofile of mesenchymal chondrosarcoma: aberrant desmin and EMA expression, retention of INI1, and negative estrogen receptor in 22 female-predominant central nervous system and musculoskeletal cases. *Ann Diagn Pathol*. 2010;14(1):8-14. [Crossref](#)
- Dahlin, D., Unni, K. and Inwards, C., Bone tumors. 6th ed. Chapter 7: Mesenchymal Chondrosarcoma. Philadelphia: Wollters Kluwer/ Lippincott Williams & Wilkins;2010. pp.92-7.
- Dahlin DC, Henderson ED. Mesenchymal chondrosarcoma. Further observations on a new entity. *Cancer*. 1962;15:410-7. [Crossref](#)
- Bertoni F, Picci P, Bacchini P, Capanna R, Innao V, Bacci G, et al. Mesenchymal chondrosarcoma of bone and soft tissues. *Cancer*. 1983;52(3):533-41. [Crossref](#)
- Fletcher DM, Unni KK, Mertens F. World Health Organization Classification of Tumours. Pathology and Genetics of Tumours of Soft Tissue and Bone. Lyon: IARC Press; 2002:14–18, 247–57.
- Guccion JG, Font RL, Enzinger FM, Zimmerman LE. Extraskelletal mesenchymal chondrosarcoma. *ArchPathol*. 1973;95(5):336-40. [Website](#)
- Dowling EA. Mesenchymal chondrosarcoma, *J Bone Joint Surg Am*. 1964;46:747-54. [Website](#)
- Scheithauer BW, Rubinstein LJ. Meningeal mesenchymal chondrosarcoma: report of 8 cases with review of the literature. *Cancer*. 1978;42(6):2744-52. [Crossref](#)
- Dorfman HD, Czerniak B. Bone Tumors. St. Louis, MO: CV Mosby Co;1998:421–35.
- Guillou L, Coindre JM, Bonichon F, Nguyen BB, Terrier P, Collin F, et al. Comparative study of the National Cancer Institute and French Federation of Cancer Centers Sarcoma Group grading systems in a population of 410 adult patients with soft tissue sarcoma. *Journal of clinical oncology*. 1997;15(1):350-62. [Crossref](#)