

# ROLE OF COLOUR DOPPLER ULTRASONOGRAPHY IN THE EVALUATION OF DEEP VEIN THROMBOSIS OF PERIPHERAL LIMBS AT A TERTIARY CARE CENTRE IN KATHMANDU

*Abhushan Siddhi Tuladhar, Pingala Khadka, Sammi Joshi, Keshika Koirala, Sunil Pradhan, Amit Shrestha*

Department of Radiology, Nepal Medical College Teaching Hospital, Attarkhel, Gokarneshwor-8, Kathmandu, Nepal

## ABSTRACT

Deep venous thrombosis is the development of blood clots in the deep veins. The management of deep venous thrombosis has been irreversibly altered after the introduction of Doppler ultrasound. This study aims to find out the prevalence of deep vein thrombosis of lower limbs diagnosed with colour Doppler ultrasonography at a tertiary care centre. A descriptive cross-sectional study was conducted in the Department of Radiology at a tertiary care hospital from October, 2021 to March, 2022. The study was conducted among 100 patients with clinically suspected deep venous thrombosis. Data were entered and analyzed using Microsoft Excel. Point estimate at 95.0% confidence limits was calculated and results were expressed in frequency and proportion for binary data. Among 100 patients, deep venous thrombosis was diagnosed in 88 (88.0%) patients (95% CL: 81.63-94.37). The patients had a mean age of  $48.4 \pm 1.6$  years. Out of 88 patients, 46 (52.3%) were male and 42 (47.7%) were female. Seventy-three (82.9%) patients had acute DVT. Multiple contiguous veins were predominantly involved (75.0%) than isolated veins (25.0%). Coexisting pathological conditions were seen in 41 cases (46.6%). The prevalence of deep vein thrombosis of lower limbs diagnosed with colour Doppler ultrasonography was higher when compared to other similar reported literatures.

## KEYWORDS

Lower extremity, ultrasonography, venous thrombosis

*Received on:* April 20, 2022

*Accepted for publication:* May 30, 2022

## CORRESPONDING AUTHOR

Dr. Abhushan Siddhi Tuladhar,  
Associate Professor,  
Department of Radiology,  
Nepal Medical College Teaching Hospital,  
Attarkhel, Gokarneshwor-8, Kathmandu, Nepal  
Email: abhushant@gmail.com  
Orcid No: <https://orcid.org/0000-0003-3390-7277>  
DOI: <https://doi.org/10.3126/nmcj.v24i2.46046>

## INTRODUCTION

Deep venous thrombosis (DVT) is the development of blood clots in the deep veins.<sup>1,2</sup> It has an incidence of 67 per 100,000 per year in the general population. DVT is suspected in patients with acute pain, swelling, redness, and/or warmth in the affected lower extremity. Accurate diagnosis of DVT is important because patients falsely diagnosed with DVT are treated with anticoagulation and are exposed to risk of bleeding.<sup>3</sup> The principle used is that the venous flow pattern of the vein gets distorted due to thrombotic obstruction which is easily detected by the Doppler. Doppler USG is a non-invasive, safe, sensitive, inexpensive, repeatedly and rapidly used technique that detects many thrombi at a stage when no major changes have occurred in the venous hemodynamic.<sup>4,5</sup>

In clinically symptomatic patients, Colour Doppler sonography has high sensitivity (92.8%) and specificity (98.0%) in detecting and diagnosing DVT of lower limbs.<sup>6</sup> In experienced hands, colour Doppler study is as accurate as venography in detecting and diagnosing DVT, with accuracy of 99.4% for proximal lower limb and 93.1% for distal lower limb. The average time required for the study is 15 to 20 minutes which is again less as compared to venography.<sup>7</sup> Furthermore, the scan time can be reduced to 9.7 minutes (54%), when scan is done by limited ultrasound compression method.<sup>8</sup>

Other causes of painful and swollen legs can also be diagnosed with ultrasound during the same scan, who are found not to have DVT, and this accounts to 20% of patients clinically suspected of DVT.<sup>7</sup> Besides colour Doppler study having high sensitivity, specificity, positive and negative predictive values in detection of acute DVT, it can also easily differentiate acute from subacute and chronic DVT.<sup>9</sup> Colour Doppler study in every aspect is superior to conventional studies and is primary investigation of choice in evaluating the patients suspected of DVT.<sup>10</sup> This study aims to find out the prevalence, chronicity and spectrum of deep vein thrombosis of lower limbs diagnosed with colour Doppler ultrasonography at a tertiary care centre.

## MATERIALS AND METHODS

This was a descriptive cross-sectional study conducted among patients presenting to the Department of Radiology of Nepal Medical College and Teaching Hospital between October, 2021 to March, 2022 after receiving

ethical approval from the Institutional Review Committee of Nepal Medical College Teaching Hospital (Reference number: 024-078/079). One hundred clinically suspected patients of DVT referred to the Department of Radiology of Nepal Medical College Teaching Hospital were subjected to color Doppler examination using a Toshiba Xario 100 USG Unit, with a 7.5 MHz linear array 56 mm footprint transducer. A 3.5 MHz convex transducer was used for evaluation of iliac veins and inferior vena cava.

Analysis of positive cases of DVT was done in terms of age, sex, nature and chronicity, pattern of involvement of veins, and coexisting pathological conditions. The patient was examined in supine position with legs abducted and externally rotated with slight flexion of the knee for evaluation of femoral venous segment. The patient was kept in a prone position for evaluation of the popliteal vein. Calf veins were evaluated in a supine position and the knee slightly flexed, internally rotated for the anterior tibial veins, and externally rotated for the posterior tibial and peroneal veins.

Sample size was calculated using the formula  $n = z^2 p (100-p) d^2$ , with expected prevalence of deep venous thrombosis of 85% and with margin of error 7%. A sample size of 100 was taken to include patients referred to the Department of Radiology with clinically suspected DVT. Data was entered and analyzed using Microsoft Excel. Point estimate at 95.0% confidence limits was calculated and results were expressed in frequency and percentages.

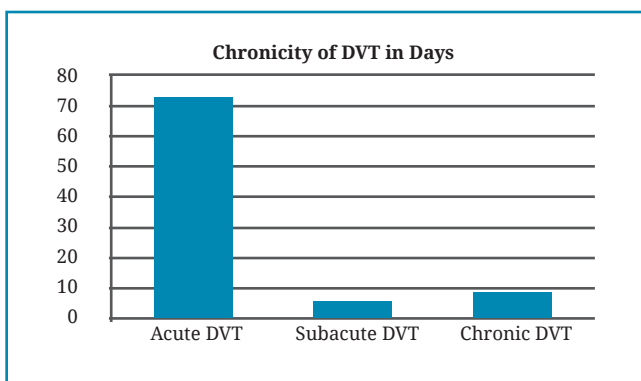
## RESULTS

Among 100 patients enrolled in the study, DVT was diagnosed in 88 patients (88.0%). (95% CL: 81.6-94.4). The age of patients ranged from 18 to 85 years with a mean age of  $48.4 \pm 1.6$  years. The incidence was highest in the fifth decade. Out of these patients, 46 (52.3%) were male and 42 (47.7%) were female. The predominant stage of DVT was that of acute stage (83.0%), followed by chronic stage (10.2%) and subacute stage (6.8%).

Multiple contiguous veins were predominantly involved in 66 patients (75.0%) than isolated veins in 22 (25.0%). Out of the 22 cases of isolated DVT, the popliteal vein was predominantly involved in 9 (10.2%) cases followed by 8 cases (9.1%) of femoral vein. All the veins were involved in 40 cases (45.4%) and 2 of them had extension to inferior vena cava.

**Table 1: Age distribution of patients with DVT**

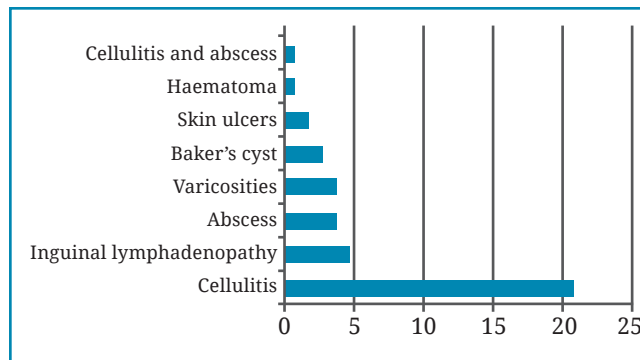
Age group in year	Cases diagnosed of DVT (n=88) (%)
11-20	2 (2.3)
21-30	14 (15.9)
31-40	14 (15.9)
41-50	17 (19.3)
51-60	18 (20.5)
61-70	13 (14.8)
>71	10 (11.3)
<b>Total</b>	<b>88 (100.0)</b>



**Fig. 1:** Bar diagram showing patients in different stages of DVT (in days)

**Table 2: Table showing different veins of lower limbs involved by DVT**

Veins Involved	No of cases showing involvement (%)
External iliac vein	1 (1.1)
Femoral vein	8 (9.1)
Popliteal vein	9 (10.2)
Peroneal and tibial veins	4 (4.5)
External iliac and femoral veins	2 (2.2)
External iliac, femoral and popliteal veins	3 (3.4)
Femoral and popliteal veins	8 (9.1)
Femoral, popliteal, peroneal and tibial veins	2 (2.3)
Popliteal, peroneal and tibial veins	11 (12.5)
All veins	40 (45.4)
<b>Total</b>	<b>88</b>



**Fig. 2:** Bar diagram showing different coexisting pathological conditions in patients having DVT

Coexisting pathological conditions were seen in 41 cases (46.6%). Out of which, cellulitis was the most common, seen in 21 cases followed by inguinal lymphadenopathy.

## DISCUSSION

The introduction of Doppler ultrasound has greatly improved the assessment of the vascular system in health care worldwide. The ripple impact may be visible with the assessment and management of acute unilateral lower limb swelling, that is typically encountered in medical practice, with DVT frequently raised as the primary diagnosis.<sup>11</sup> It has been recognized that, as clinical signs and symptoms of DVT are not specific for the diagnosis, objective diagnosis in patients presenting with leg symptoms is crucial.<sup>12</sup> DVT occurs along a continuum with progression, extension, and propagation.<sup>13</sup>

In our study, the age group of patients with DVT ranged from 18 to 85 years with a mean age of 48.43 years and the majority of them belonged to the fifth decade (20.4%). This is similar to the study conducted in 2014 that showed age ranged from 21 to 83 years with mean age of 47 years and predominance in fifth decade.<sup>4</sup> In a 2016 study done in Benin, Nigeria, the highest incidence was recorded in the third decade of life which differs from our study.<sup>14</sup> The youngest patient in our study was 18 years old which is in tandem with the above studies.<sup>4,14</sup> Few cases of the younger age group in our study, were also contributed by young intravenous drug abusers, predisposing to DVT, which is not very rare in our country.

DVT is found to be more common in women than men.<sup>15,16</sup> Women are more predisposed than men to DVT due to few gender-specific risk factors (such as pregnancy, oral contraceptive pills, hormone replacement therapies, and pelvic masses).<sup>17</sup> Our study showed 52.3% males

and 47.7% females. Thus males dominated the study group which is similar to the studies done in Pune, India in 2014 and in Sudan in 2015.<sup>4,18</sup> This does not correlate well with the study done in Benin, Nigeria in 2021 which showed female predominance (59.6%).<sup>14</sup>

The most common stage of DVT in our study was that of the acute type seen in 73 cases (82.9%) as compared to the chronic type seen in 9 cases (10.2%) and subacute type seen in 6 cases (6.8%). These findings are in contrast with studies conducted in 2014 and 2020 that found subacute stage and chronic stage as the predominant stage of DVT respectively.<sup>4,14</sup> In this study, there were a lesser number of cases of chronic DVT, which might be because of failure to come for follow-up, and also because of negligence and /or ignorance by the patients on achieving some significant improvements in symptoms after initial treatment for acute DVT.

In our study, thrombosis was localized to external iliac vein in 1.1%, femoral vein in 9.1%, popliteal vein in 10.2%, peroneal and tibial veins in 4.5%, external iliac and femoral veins in 2.3%, external iliac and femoral and popliteal veins in 3.4%, femoral and popliteal veins in 9.1%, femoral, popliteal, peroneal and tibial in 2.3%, popliteal, peroneal and tibial veins in 12.5% and all veins in 45.4%. Out of 88 patients, 2 had extension of DVT to Inferior vena cava. Thus, multiple contiguous veins were predominantly involved (75.0%) than isolated veins (25.0%), a finding that is similar to the study reported in 2014.<sup>11</sup>

This study further showed 46.6% patients with coexisting conditions and among them cellulitis (51.2%) and inguinal lymphadenopathy (12.2%) being the two most common coexisting conditions. This collaborated well with the study done in 2021 that showed multiple inguinal lymphadenopathy and cellulitis as

the most common features observed with frequencies of 35.7% and 29.1%, respectively.<sup>11</sup> The co-existence of DVT and cellulitis can be explained by the fact that cellulitis could be a manifestation of acute DVT and could also be attributed to thrombophlebitis of superficial veins, which may be occurring simultaneously with DVT.

In a study conducted in Serbia in 2006, a prospective study was carried out on 810 patients to evaluate the role of Duplex sonography in clinically suspected patients of deep venous thrombosis of lower extremities, concluded that various vascular and nonvascular diseases may mimic deep venous thrombosis, and that is why ultrasonography should be used whenever possible to avoid unnecessary anticoagulant therapy.<sup>19</sup>

In conclusion, DVT of lower limbs is one of the most common causes for the majority of deaths due to pulmonary embolism which can be detected non-invasively, readily and rapidly by the use of colour Doppler USG.<sup>20</sup> It has become the investigation of choice for DVT in our parts of the world. The pattern of DVT in our setting showed greater male preponderance, multiple contiguous veins being involved, mostly in acute stage and with cellulitis present as a coexisting condition in most of the cases. Therefore, Doppler sonography is recommended for all clinically suspected cases of DVT because it detects many thrombi at a stage when no major changes have occurred in the venous hemodynamics. It will prevent unnecessary anticoagulation in patients with clinical suspicion of DVT. The results of the study cannot be generalized as the population under study is limited to patients attending to the tertiary care hospital only.

**Conflict of interest:** None

**Source of research fund:** None

## REFERENCES

1. Kesieme E, Kesieme C, Jebbin N, Irekpita E, Dongo A. Deep vein thrombosis: a clinical review. *J Blood Med* 2011; 2: 59-69.
2. Shapiro N, Versaggi SL. Doppler Peripheral Venous Duplex Assessment, Protocols, and Interpretation. 2021. In: StatPearls [Internet]. Treasure Island (FL): StatPearls Publishing; 2022 Jan-.
3. Bhatt M, Braun C, Patel P et al. Diagnosis of deep vein thrombosis of the lower extremity: a systematic review and meta-analysis of test accuracy. *Blood Adv* 2020; 4: 1250-64.
4. Khaladkar SM, Thakkar DK, Shinde K, Thakkar DK, Shrotri H, Kulkarni VM. Deep vein thrombosis of the lower limbs: A retrospective analysis of Doppler ultrasound findings. *Med JDY Patil Univ* 2014; 7: 612-9.
5. Swanson E. Doppler ultrasound imaging for detection of deep vein thrombosis in plastic surgery outpatients: a prospective controlled study. *Aesthet Surg J* 2015; 35: 204-14.
6. Theodorou SJ, Theodorou DJ, Kakitsubata Y. Sonography and venography of the lower extremities for diagnosing deep vein thrombosis in symptomatic patients: *Clin Imaging* 2003; 27: 180-3.



7. Labropoulos N, Leon N, Kalodiki E, Al Kutoubi A, Chan P, Nicolaides AN. Color flow duplex scanning in suspected acute deep vein thrombosis; experience with routine use. *Eur J Endo Vasc Surg* 1995; 9: 49-52.
8. Pezzullo JA, Perkins AB, Cronan JJ. Symptomatic deep vein thrombosis: diagnosis with limited compression US. *Radiol* 1996; 198: 67-70.
9. Lewis BD, James EM, Welch TJ, Joyce JW, Hallet JW, Weaver AL. Diagnosis of acute deep venous thrombosis of lower extremities: prospective evaluation of color Doppler flow imaging versus venography. *Radiol* 1994; 192: 651-5.
10. Bomhard T, Oellinger H, Bottcher H, Flesch U. The role of color-coded Doppler sonography in the diagnosis of the veins in the lower extremities in comparison with conventional phlebography. *Aktuelle Radiol* 1993; 3: 279-82.
11. Edzie EKM, Dzeft-Tetty K, Brakohiapa EK *et al.* Assessment of venous Doppler ultrasound findings of acute unilateral lower limb swelling in a tertiary facility in central Ghana: a retrospective analytical study. *Egypt J Radiol Nucl Med* 2021; 52: 288.
12. Huisman MV, Klok FA. Diagnostic management of acute deep vein thrombosis and pulmonary embolism. *J Thromb Haemost* 2013; 11: 412-22.
13. Hill SL, Holtzman GI, Martin D, Evans P, Toler W, Goad K. Selective use of the duplex scan in diagnosis of deep venous thrombosis. *Am J Surg* 1995; 170: 201-5.
14. Ose-Emenim IB, Oghanina EF. Doppler scans of lower limbs' DVT: Experience at university of Benin Teaching Hospital, Nigeria. *East Afr Med J* 2016; 93: 684-90.
15. Chinglensana, L, Rudrappa, S, Anupama, K, Gojendra, T, Singh KK, Chandra, ST. Clinical profile and management of deep vein thrombosis of lower limb. *J Med Soc* 2013; 27: 10-4.
16. Naess IA, Christiansen SC, Romundstad P, Cannegieter SC, Rosendaal FR, Hammerstrøm J. Incidence and mortality of venous thrombosis: a population-based study. *J Thromb Haemost* 2007; 5: 692-9.
17. Ismail A, Tabari AM, Isyaku K. Doppler sonographic evaluation of venogenic extremity swellings: Analysis of 170 patients from Kano, Nigeria. *Niger J Clin Pract* 2017; 20: 930-5.
18. Gameraddin MB, Abdelmaboud S, Alshoabi SA, Alagab F, Yousef M, Gibreel T. The Role of Color Doppler Ultrasound in Evaluation of Deep Veins Thrombosis of Lower Extremities. *J American Soc* 2015; 11: 124-8.
19. Vucaj-Cirilović V, Petrović K, Nikolić O, Til V, Nićiforović D, Hadnadev D. Duplex Doppler ultrasonography in the diagnosis of deep venous thrombosis of the lower extremities. *Med Pregl* 2006; 59: 11-4.
20. Fraser JD, Anderson DR. Deep venous thrombosis: recent advances and optimal investigation with US. *Radiol* 1999; 211: 9-24.