

THE SPECTRUM OF SONOGRAPHIC FINDINGS IN ENTERIC FEVER CASES OF PAEDIATRICS AGE GROUP IN GURUGRAM REGION OF HARYANA, INDIA

Shashi Sharma,¹ Lakshay Rana,¹ Natasha Nargotra,² Priyanka Kadian,¹ Abhivind Bhutani,² Surbhi Lathwal,² Aman Arora,¹ Bharat Bhushan Sharma²

¹Department of Paediatrics, ²Department of Radio-Diagnosis, SGT Medical Collage and Research Institute, Gurugram, Haryana, India

ABSTRACT

There is always need for the earliest diagnosis of enteric fever to start the appropriate treatment for this life threatening illness. The diagnosis becomes difficult because of inherent limitation due to the long standing vague complaints. Some findings like acalculus cholecystitis, hepatosplenomegaly, enlarged mesenteric lymph nodes (MLN) and free fluid can easily be picked up by ultrasonography (USG). USG is easily available, without any ionizing radiation, non-invasive and economical. Hemoculture and Widal tests are time consuming and the cost is quite high. The study was conducted with 100 paediatric patients aged 1-year to 15-year. All were having enteric fever based on typhi dot-IgM presented to the paediatric department of the hospital. USG was conducted for the evaluation of the various relevant findings. Blood samples for CBC, LFT and blood culture were taken on the same day as that of USG evaluation. USG evaluation of confirmed enteric fever cases revealed that 25% had gall bladder findings, 23% had hepatosplenomegaly, 11% had hepatomegaly, 1% had enlarged mesenteric lymph nodes (MLN) and 3% had thickened caecum wall and ileocaecal junction. USG can diagnose many findings which are related to enteric fever and are helpful in starting the early management. Hemoculture and other investigations may delay the treatment which can lead to various complications.

KEYWORDS

Enteric fever, acalculus cholecystitis, MLN, USG, hemoculture, Widal test

Received on: April 12, 2021

Accepted for publication: September 24, 2021

CORRESPONDING AUTHOR

Dr. Bharat Bhushan Sharma
Professor & HOD,
Department of Radio-Diagnosis,
SGT Medical Collage and Research Institute,
Gurugram, Haryana (India)
Email: bbhushan986@gmail.com
Orcid No (1st Author): <https://orcid.org/0000-0002-6865-2350>
DOI: <https://doi.org/10.3126/nmcj.v24i1.44143>

INTRODUCTION

Enteric fever caused by salmonella typhi is endemic in many countries with remarkable predominance in India. Indeed an early diagnosis is difficult because of several spectra of clinical features of the disease.^{1,2} The hemoculture are the confirmatory tests which takes around 4-5 days to become evident.³ An improper/inadequate use of antibiotics by the patient prior to any medical consultation further adds to the failure of proper diagnosis. Systemic manifestations such as enlarged mesenteric lymph nodes (MLNs) and mural thickening of the terminal ileum are seen in enteric patients. These manifestations are also accompanied by other findings such as hepatosplenomegaly, cholecystitis, hepatomegaly, gall bladder wall oedema, pericholecystic fluid collection which are confirmed by using the ultrasonography (USG). USG was the most accepted imaging modality for the evaluation of enteric fever because of quick, easily availability, non-invasive and of non-ionizing in nature. So it was considered very safe modality for children in the flow chart of diagnosis. There is emphasis on the usefulness of detecting MLNs with USG as a diagnostic method in the early stage of enteric fever.⁴ MLNs are considered vital barriers against the systemic dissemination of *S. typhi* in a mouse model.⁵ The important goal remains for the early diagnosis which is very difficult in the initial stages. USG examination of the abdomen is helpful in the diagnosis of enteric fever during the 1st week of onset of fever. The bowel wall thickening of the ileocaecal region with MLNs is not specific for any one causative organism

for bacterial enteritis. The proper diagnosis of enteric fever could be possible along with the typical USG features as described above. The present study was aimed at elucidating the usefulness of USG over the routine Widal test, typhi dot IgM and hemoculture in the diagnosis of enteric fever.⁶

MATERIALS AND METHODS

This eighteen months study was conducted with 100 pediatric patients of 1-15-year age group

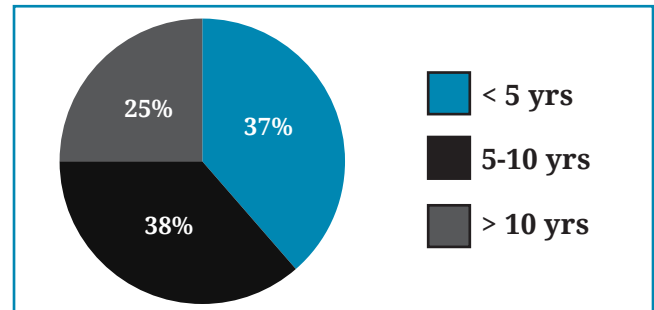


Fig. 1: Distribution of the cases as per the age group

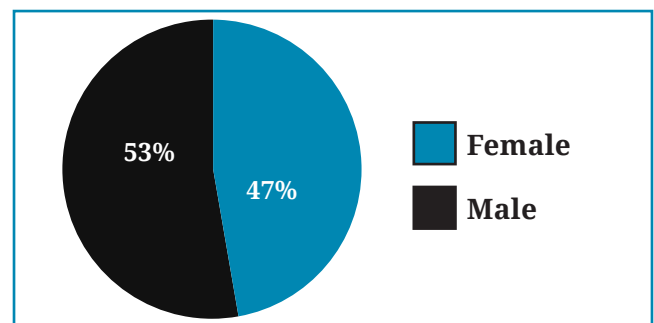


Fig. 2: Case distribution as per the gender.

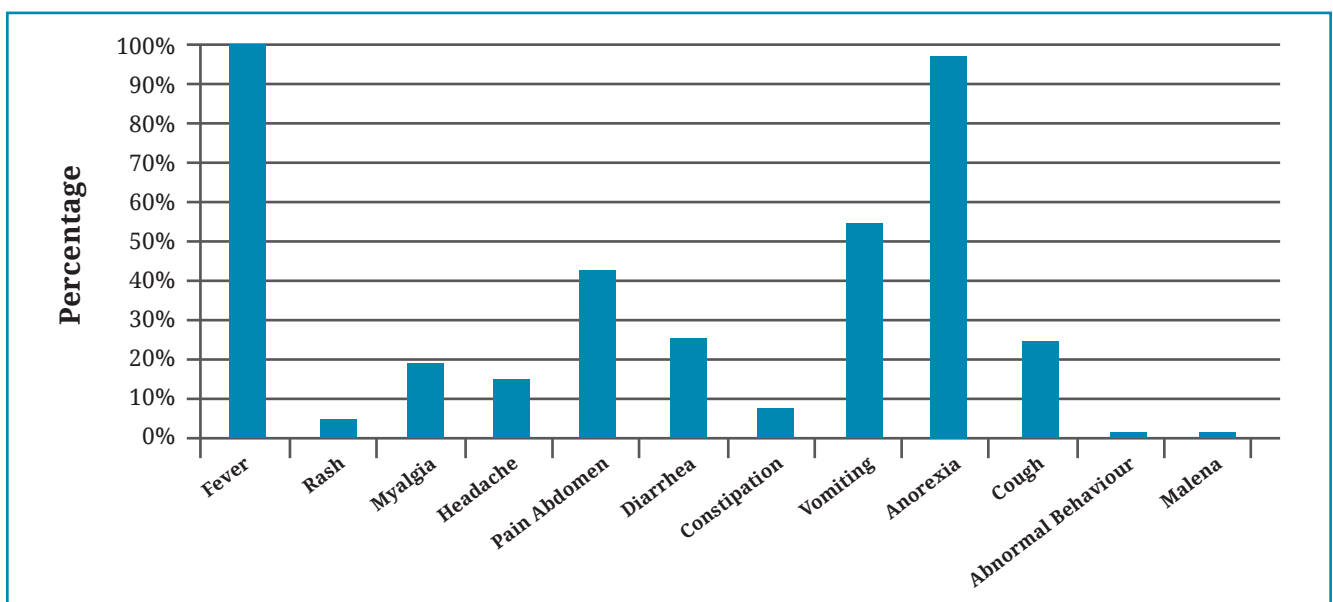


Fig. 3: Distribution of the cases as per the complaints.

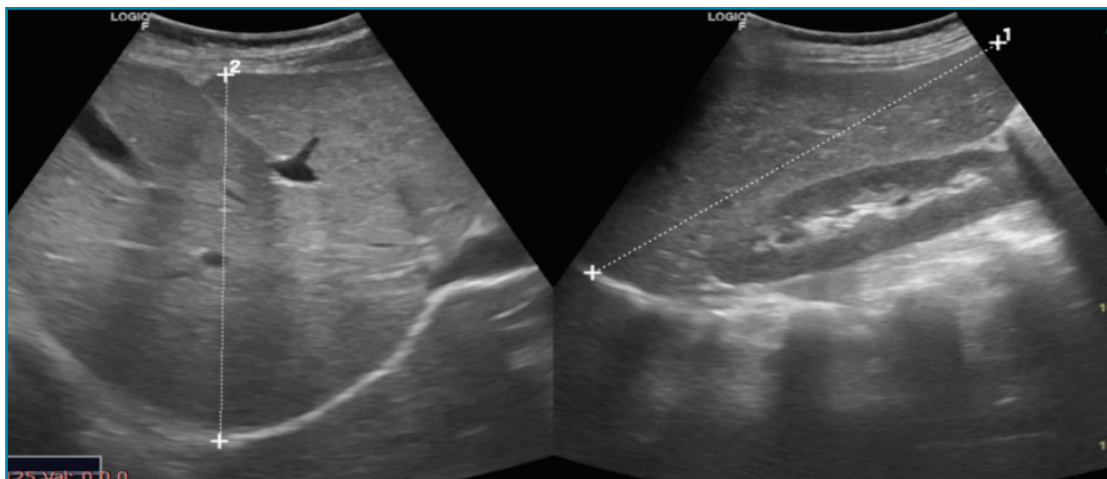


Fig. 4: Sonographic measurements of liver and spleen.

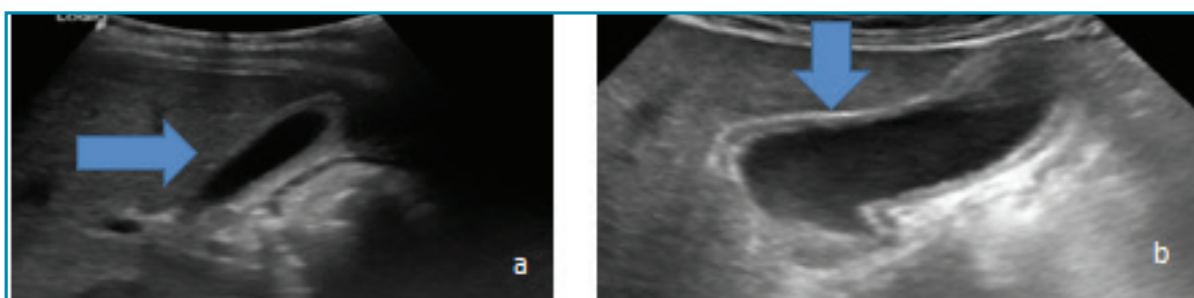


Fig. 5: Gall bladder evaluation by ultrasonography.a) oedematous gall bladder wall (horizontal arrow).b). pericholecystic fluid collection (vertical arrow).

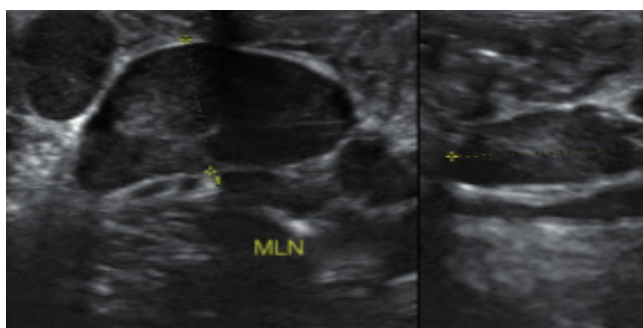


Fig. 6: Mesenteric lymph node measurement in short axis in abdominal sonographic evaluation.

used for the evaluation of whole abdomen with special focus on gall bladder, mesenteric lymph nodes and ileocaecal junction. A gall bladder wall thickness of more than 3 mm was considered abnormal. The average duration of the USG examination was 10-20 minute and no patient required analgesia. The measurement of liver and spleen were taken on the long axis and compared with the standard (Figure 4).Gall bladder was evaluated for the wall oedema in the form of thickness and for any pericholecystic collection (Fig. 4, 5a, 5b). Mesenteric lymph nodes were evaluated as per the protocol and measured in the short axis for the size (Fig. 6).

RESULTS

It was evident from USG studies that 25 out of 100 children (25%) had gall bladder finding in one or the other way (Fig. 7). The remaining 75 children (75%) had USG spectrum as splenomegaly (23%), hepatomegaly (11%), mesenteric lymph nodes (17%) and thickened cecal wall or ileocecal junction (3%). Two patients were having cholecystitis findings in the form of wall oedema or pericholecystic

(Fig. 1). There were fifty three male and forty seven female children in this study (Fig. 2). They reported with the common complaints such as fever, pain abdomen, anorexia, vomiting, headache etc. (Fig. 3). They were diagnosed as enteric fever cases based on Typhi dot-IgM as they presented to the pediatric department of our tertiary hospital. Blood samples were taken on the same day for CBC, LFT and blood culture. A convex transducer with a frequency of 4-7 MHz and a linear transducer with a frequency of 12 MHz on the ultrasound machine were

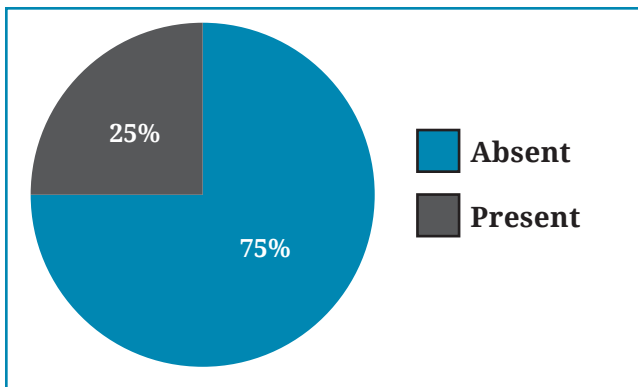


Fig. 7: Incidence of sonographic findings.

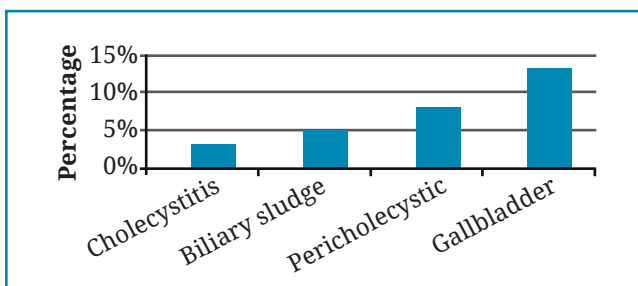


Fig. 8: Types of sonographic findings.

collection. We also noted that in 17 cases with enlarged MLNs with the size ranging from 12 mm to 32 mm (mean, 16mm) in short axis diameter. Lymph nodes were oval or rounded hypoechoic structures with well-defined margins seen. However, MLNs continued to be observed in 12 (40%) cases in 15 days had shown significant diminution in size on review USG studies. Three cases with bowel wall thickening were noticed due to oedema of mucosa and sub-mucosa with preserved layered structure of the intestinal wall. Furthermore, 3 cases has increased wall thickness of 9 mm at the terminal ileum and caecum. Other 11 cases had shown mixed findings of cholecystitis, biliary sludge and pericholecystic collection (Fig. 8).

DISCUSSION

Enteric fever is an acute systemic disease consisting of malaise, fever, abdominal discomfort and other associated complaints. Fever is caused by *S.typhi* and so it is called as enteric fever.⁷ There is global burden in dealing this entity as this causes great morbidity and mortality in pediatric population. The scenario is different in Indian set up due to the meagre resources and economically less compatible for the disease. The paramount importance lies in the early diagnosis and to start the management before life threatening complications overtake.⁸⁻¹⁰ Widal test is the mainstay for the confirmation of the diagnosis

before the appropriate treatment is started.¹¹ Biliary infections are usually asymptomatic but USG picks up early findings of gall bladder and bile ducts being getting infected initially. Infecting bacilli multiply in the small intestine and further invade the intestinal lymphatic system leading to the enlargement of mesenteric lymph nodes (MLNs). Sonography had a great role to play in picking up these types of subtle findings in typhoid fever cases. Routine initial USG screening of these cases may prove to be wonderful for any clue for the suspicion of enteric fever.¹² These are assessed as a routine by computed tomography if USG studies are equivocal.¹³ Consequently bacilli occupying the liver and biliary ducts causes bacteraemia and gets excreted into the bile. This remains concentrated in GB in high titres during the progress of the infection.

Thus, enlarged MLNs, bowel wall thickening, cholecystitis, gall bladder wall oedema and hepato-splenomegaly are the typical pathophysiological changes seen during USG evaluation in these type of infections. Two case reports have been recorded of dilated hydropic GB from USG studies owing to *S.typhi* infections.¹⁴ Furthermore, VI capsular polysaccharide was first identified as a virulence in *S.typhi* and it regulates the early inflammatory response from intestinal epithelial cells during *S.typhi* infection.¹⁵

This is in marked contrast to the findings in other forms of salmonellosis involving severe intestinal inflammation. An early diagnosis of enteric fever in endemic areas by USG-based detection of enlarged MLNs should have given rise of the described systemic manifestations in patient with enteric fever. Lee *et al* conducted the study and found that there are wide range of extra cholecystic conditions causing cholecystitis which can resolve spontaneously. This can avoid the surgical contemplations.¹⁶ Shetty and Broome (1998) used sonographic findings were also used for assessing the severity score of the gall bladder changes.¹⁷ Though the early diagnosis in enteric fever is of paramount important but the non specific nature of clinical symptomatology adds more problems to the justification and confirmation of the diagnosis. The most difficult is the febrile nature of malaria which can confuse this entity. Extra-pulmonary tuberculosis and viral enteritis are often found in developing countries so specific finding typical for these diseases can be taken as exclusion criteria.¹⁸ MLNs in tubercular enteritis can easily be differentiated from other aetiologies as being more hypoechoic and with evidence of central necrosis.¹⁹ Splenomegaly and hepatomegaly are the main USG features

for the diagnosis of malaria. Blood test has got 85-95% sensitivity and 95-100% specificity in malaria parasite depending upon microscopic test or with fluorescent microscopy. In cases of enteric fever with delayed diagnosis and lack of proper clinical management, the patient may experience complications like bleeding gut, and peritonitis. In severe cases renal impairment, retinopathy and encephalitis with convulsions may occur. In this study in enteric fever cases enlarged MLNs appeared shortly after onset. The use of USG to assess enteric fever pathogenesis would help febrile children with long standing morbidity. Urgent attentions are needed in comparison to adults in diagnosis of this life threatening infection. Malik AS and Malik RH conducted study (2001) in 102 Malaysian children with confirmed enteric fever diagnosis and were found to be having hepatitis (nineteen) and paralytic ileus (seven). All these findings were confirmed sonographically also.²⁰ There is lot of debate regarding the role of USG in evaluation of ileitis in enteric fever in children, but the proper protocol helps in correctly diagnosing the thickened bowel. The role of compression is very important to delineate the structures like MLNs and terminal ileum. This displaces

the air and other artifacts.²¹⁻²³ The emphasis still encompasses the benefit of sonography in evaluation of suspected typhoid fever cases. This is quick and without any radiation hazards to children.²⁴

In conclusion, sonographic features specific for enteric fever like hepato-splenomegaly, enlarged MLNs, bowel wall thickening and acalculus cholecystitis were evaluated. These were quite helpful in coming closer to the diagnosis at the earliest possible time. Thus sonography is an important early diagnostic tool for enteric fever diagnosis due to the above mentioned reasons.

ACKNOWLEDGEMENT

We are grateful to Mr. Arshad, Miss Ashita Jain, Assistant professors of FAHS of SGT University Gurugram (Haryana) for providing radiological inputs. We are thankful to Mr. Brijesh Kumar, computer assistant for extending necessary input.

Conflict of interest: None

Source of research fund: None

REFERENCES

- Mukhopadhyay B, Sur D, Gupta SS, Ganguly NK. Typhoid fever: Control and challenges in India. *Indian J Med Res* 2019; 150: 437-47. DOI:10.4103/ijmr.IJMR_411_18
- Chitkara AJ, Chitkara S, Narang PS, Sundharam M, Goyal M. Clinico-bacteriological profile of typhoid fever in a private sector hospital in New Delhi. *Indian Pediatr* 2019, 56: 1033-6. PMID: 31884434.
- Richter J, Hartz C, Haussinger D. Ultrasound in tropical and parasitic diseases. *Lancet* 2003; 362: 900e2. DOI: 10.1016/S0140-6736(03)14334-6.
- Mateen MA, Saleem S, Rao PC *et al.* Ultrasound in the diagnosis of typhoid fever. *Indian J Pediatr* 2006; 73: 681e5. DOI: 10.1007/BF02898444
- Nakashi S, Nakamura T, Agha N, *et al.* Clinical features and early diagnosis of typhoid fever emphasizing usefulness of detecting mesenteric lymphadenopathy with ultrasound as diagnostic method. *Southeast Asian J Trop Med Public Health* 2003; 34: 153e7. PMID19230587
- Germainer R, Furer E. Isolation and characterization of gal E mutant Ty 21a of *Salmonella typhi*: a candidate strain for a live, oral typhoid vaccine. *J Infect Dis* 1975; 131: 553e8. DOI: 10.1093/infdis/131.5.553
- Kobayashi A, Adachi Y, Iwata Y *et al.* Abdominal ultrasonographic findings in typhoid fever: a comparison between typhoid patients and those with non-typhoidal *Salmonella* and *Campylobacter jejuni* enterocolitis. *Southeast Asian J Trop Med Public Health* 2012; 43: 423-30. PMID:23082592.
- Crump JA, Luby SP, Mintz ED. The global burden of typhoid fever. *Bull World Health Organ* 2004; 82: 346-53. PMID:15298225.PMCID:PMC2622843
- Parry CM, Hien TT, Dougan G, White NJ, Farrar JJ. Typhoid fever. *N Engl J Med* 2002; 28; 347: 1770-82. Doi:10.1056/NEJMra020201. PMID:12456854
- Wain J, Hendriksen RS, Mikoleit ML *et al.* Typhoid fever. *Lancet* 2016; 385: 1136-45. DOI: 10.1016/S0140-6736(13)62708-7
- Chow CB, Wang PS, Cheung MW, Yan WW, Leung NK. Diagnostic value of the Widal test in childhood typhoid fever. *Pediatr Infect Dis J* 1987; 6: 914-7. Doi:10.1097/00006454-198710000-00011. PMID:3696823.
- Hafeez W, Rajalakshmi S, Sripriya S *et al.* Role of computed tomography of abdomen in difficult to diagnose typhoid fever: a case series. *Trop Doct* 2018; 48: 116-22. Doi:10.1177/0049475517740311. Epub 2017 Nov 16. Trop Doct.2018PMID:29145776.
- Younis SN, Younis SN. The role of abdominal ultrasound in the diagnosis of typhoid fever: an observational study. *Travel Med Infect Dis* 2014;

- 12: 179-82. Doi:10.1016/j.tmaid.2013.09.004. Epub 2013 Oct 9. *Travel Med Infect Dis.* 2014. PMID:24144458.
14. Cohen EK, Stringer DA, Smith CR *et al.* Hydrops of the gall bladder in typhoid fever as demonstrated by sonography. *J Clin Ultrasound* 1986; 14: 633. DOI:1093/jcu.1870140811
15. Sharma A, Quadri A. Vi polysaccharide of *Salmonella typhi* targets the prohibitin family of molecules in intestinal epithelium cells and supresses early inflammatory responses. *Proc Nati Acad Sci USA* 2004; 101: 17492e7. DOI: 10.1073/pnas.0407536101
16. Lee JH, No YE, Lee YJ, Hwang JY, Lee JW, Park JH. Acalculous diffuse gallbladder wall thickening in children. *Pediatr Gastroenterol Hepatol Nutr* 2014; 17: 98-103. Doi: 10.5223/pghn.2014.17.2.98. Epub 2014 Jun 30. PMID:25061585; PMCID:PMC4107227
17. Shetty PB, Broome DR. Sonographic analysis of gallbladder findings in *Salmonella* enteric fever. *J Ultrasound Med* 1998; 17: 231-7. Doi: 10.7863/jum.1998.17.4231. PMID: 9544606
18. Johnson AO, Aderele WI. Enteric fever in childhood. *J Trop Med Hyg* 1981; 84: 29e35. PMID:7206018
19. Lee DH, *et al.* Sonographic findings in intestinal tuberculosis. *J Ultrasound Med* 1993; 12: 537-40. Doi:10.7863/jum.1993.12.9.537. PMID:8107186
20. Malik AS, Malik RH. Typhoid fever in Malaysian children. *Med J Malaysia* 2001; 56: 478-90. PMID:12014769
21. Puylaert JB. Mesenteric adenitis and acute terminal ileitis: US evaluation using graded compression. *Radiology* 1986; 161: 691-5. DOI:10.1148/radiology.161.3.3538138.
22. Lim JH, Ko YT, Lee DH, Lim JW, Kim TH. Sonography of inflammatory bowel disease: findings and value in differential diagnosis. *Am J Roentgenol* 1994; 163: 343-7. Doi:10.2214/ajr.163.2.8037027. PMID:8037027
23. Puylaert JB, Lalisang RI, Werf SD van der, Doonbos L. *Campylobacter ileocolitis* mimicking acute appendicitis: differentiation with graded-compression US. *Radiology* 1988; 166: 737-40. Doi: 10.1148/radiology.166.3.3277242. PMID:3277242
24. Puylaert JB, Kristjansdottir S, Golterman KL, de Jong GM, Knecht NM. Typhoid fever: diagnosis by using sonography. *Am J Roengenol* 1989; 153: 745-6. DOI:10.2214/ajr.153.4.745. PMID: 2672734