

# FOREIGN BODIES IN EAR, NOSE AND THROAT: AN EXPERIENCE FROM A TERTIARY CARE HOSPITAL IN CENTRAL NEPAL

*Pokharel A*

Department of Otorhinolaryngology and Head and Neck Surgery, College of Medical Sciences, Chitwan, Nepal

## ABSTRACT

Foreign bodies are frequently encountered otorhinolaryngology emergency. The objective of this research paper is to analyze different foreign bodies in terms of type, site, age, and gender distribution and methods of removal. A retrospective study was performed from March, 2018 to March, 2019 in a tertiary care hospital in the central part of Nepal. The information was obtained from hospital record books. A total of 315 patients visited the hospital with a foreign body in either of their ear, nose or throat. It comprised of approximately 12% of all the ENT emergencies in the hospital in the last one year of study. Foreign bodies in ear, nose and throat region were found in all age groups, although it was more prevalent among children of age group less than 10 years.

## KEYWORDS

Foreign bodies, ENT emergency

## CORRESPONDING AUTHOR

Dr. Apar Pokharel,  
Department of Otorhinolaryngology and Head and Neck  
Surgery, College of Medical Sciences, Chitwan, Nepal  
Email: [aparpokharel@hotmail.com](mailto:aparpokharel@hotmail.com)  
ORCID ID: 0000-0002-4981-1950  
DOI: <https://doi.org/10.3126/nmcj.v21i4.27616>

## INTRODUCTION

Foreign bodies (FB) in otorhinolaryngology are any objects present in ear, nose and throat that are not meant to be there and can cause harm by their presence if immediate medical or surgical attention is not sought.<sup>1</sup> According to the nature of foreign bodies, they can be classified in many ways like organic–inorganic, animate–inanimate, metallic–nonmetallic, hygroscopic–non hygroscopic, regular or irregular, soft or hard, etc., in ear, nose and throat region.<sup>2</sup> Amongst the various foreign bodies, sharp and inaccessible foreign bodies are considered dangerous. Vegetable foreign bodies if left untreated for a long time have a potential to disintegrate and release irritant vegetable oil leading to inflammation.<sup>3</sup>

It is one of the most common otolaryngological emergencies. FBs in ear, nose and throat region can happen spontaneously or accidentally in both adults and children. However, the problem is more frequent among younger children. The reason might be due to various factors such as curiosity to explore orifices, boredom, imitation, playing, mental retardation, insanity, and attention deficit hyperactivity disorder.<sup>4</sup>

Tracheobronchial foreign body (TFB) is another ENT emergency. It is more common in children under the age of five. Such children have an inefficient airway protection reflex, decreased chewing ability, and bad habit of exploring objects with mouth as well as eating while playing or crying. It can lead to life threatening complications such as airway inflammation, bronchiectasis, hemoptysis, pulmonary atelectasis, and even asphyxia and death. Absence of watchful caregivers and easy availability of the objects can lead to increased incidence of this problem among children.<sup>5</sup>

Developed countries have established and continually evolving protocols for the management of this ENT emergency. The aid of a good endoscope and microscope makes the procedure of foreign body removal easier and safer in patients. In the developing countries, however, such established protocols and surgical equipments are difficult to find. Without contacting professional health care workers, many people resort to self-treatment to save time and money as they consider it to be a minor ailment. These practices lead to complications. The removal of foreign bodies require sound anatomical knowledge of ear, nose and throat region along with specialized skills and techniques depending on their location. Any procedure done without having a good anatomical knowledge can lead to complications.<sup>6</sup>

The aim of this study is to report our experience in the diagnosis and treatment of foreign bodies in ear, nose and throat and to evaluate the location

and type of FBs, anesthesia methods, outcomes and complications.

## MATERIALS AND METHODS

This was an observational retrospective study done in the Department of ENT, Head and Neck Surgery in the College of Medical Sciences, Chitwan, Nepal. Ethical clearance was obtained from the institutional review committee for this study. The study population included all the patients who came to outpatient or emergency department of the institution with the history of foreign body (FB) lodgement in the ear, nose, oesophagus or airway. Past hospital records of last 1 year from March, 2018 to March, 2019 were considered for the study. Otoscope examination was used for the diagnosis of foreign body of the ear. Sometimes examination under microscope was done, which was a better method for both diagnosis and removal of foreign body from the ear. To diagnose foreign body of the nose, anterior rhinoscopy was done. If anterior rhinoscopy was not helpful, rigid or flexible nasal endoscopic examination was also performed. Different instruments like Jobson Horne probe, Quire foreign body lever, Hartmann forceps, FB hook, Tilley forceps and crocodile forceps were used in FB removal from the nose and ear. For removal of foreign bodies in the ear, additional methods like syringing and suctioning were also frequently used. Plain X-ray of the neck and chest was done in patients with a history of FB ingestion to rule out the presence of foreign body in the oesophagus and airway. Rigid nasal endoscopy, flexible nasopharyngolaryngoscopy, flexible bronchoscopy and flexible upper gastrointestinal endoscopy were performed in cases of high suspicion when the patient was symptomatic and the FB was not visible in X-ray, to rule out the presence of FB or to determine its site of impaction. Once the site of foreign body enlodgement was ascertained, it was removed with various surgical procedures like rigid nasal endoscopy, direct laryngoscopy, rigid oesophagoscopy and rigid bronchoscopy under general anaesthesia. Age and sex distribution, clinical presentation, type and location of FB, removal technique and complications encountered were analysed. The data generated were analysed using SPSS 16 software.

## RESULTS

During the study period of one year, a total of 315 patients visited the hospital with a foreign body in their ear, nose or throat. It comprised of around 12% of all the ENT emergencies in the hospital in the last two years. Among them, 201 were males and 114 were females. Among these 315 patients, 113 (35.87%) had foreign bodies in the

ear, 65 (20.63%) had foreign bodies in the nose, 63 (20%) had foreign bodies in the oesophagus, 41 (13.02%) had foreign bodies in the oral cavity and oropharynx, and 33 (10.48%) had foreign bodies in the airway.

**Foreign Bodies in the Ear**

A total of 113 patients were admitted to the hospital with a complaint of foreign body in the ear. Among these 113 patients, 30 (26.55%) had animate (living) foreign bodies such as ticks, maggots, cockroaches and flies, and 83 (73.45%) had inanimate (nonliving) foreign bodies in their ears. Among those 83 cases of nonliving foreign bodies, 37 (32.74%) were hygroscopic foreign bodies like grams, peanuts, bean seed and rice grain; the remaining 46 (40.71%) cases were of nonhygroscopic foreign bodies like cotton, paper, eraser, broken matchstick/cotton bud, foam and beads as illustrated in Fig. 1. Clinical findings at the time of admittance are listed in Table 1. 90 (79.65%) were children of 10 years or younger and 110 (97.35%) foreign bodies were removed in the outpatient department as shown in Fig. 2 and Fig. 3 respectively. Only one patient developed tympanic membrane perforation.

**Foreign Bodies in the Nose**

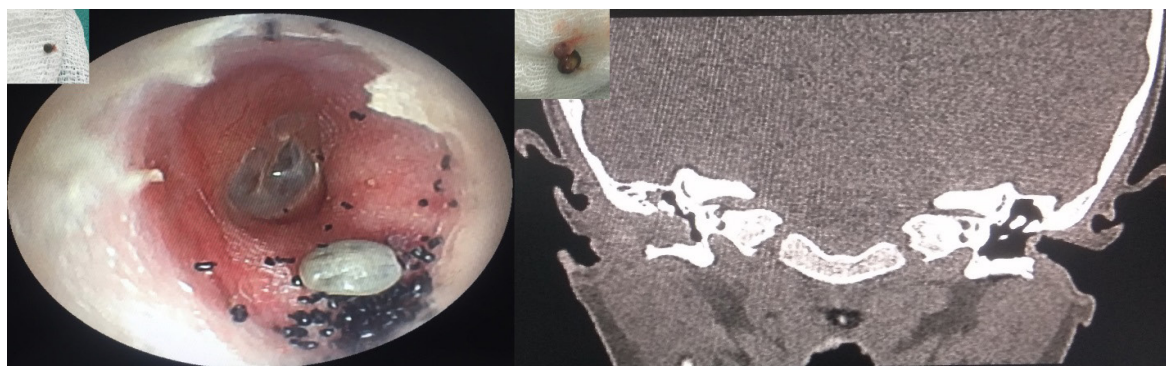
Sixty-five patients presented to the hospital with a complaint of foreign body in their nose. Among these 13(20%) had animate (living) foreign bodies like maggots, cockroaches and flies and 52 (80%) had inanimate (nonliving) foreign bodies in their nose. 28 (43.08%) out of 52 foreign bodies were hygroscopic like grams, peanuts, bean seed and rice grain; the remaining 37(56.92%) cases were of nonhygroscopic foreign bodies like cotton, paper, eraser and beads as in Fig. 4. Clinical findings at the time of presentation are listed in Table 1. 58 (89.23%) were children <10 years of age and 62 (95.38%) foreign bodies were removed in the outpatient department as in Fig. 2 and Fig. 3, respectively.

**Foreign Bodies in Oral cavity & Oropharynx**

Forty one patients presented to the hospital with complaints of foreign body stuck in the oral cavity and oropharynx. The most common foreign body was fish bone seen in 34 patients (82.92%), as in Fig. 5. The most common site of lodgement of foreign body was tonsillar fossa (51.21%), followed by base of tongue (29.27%),

**Table 1: Clinical features of nasal and aural foreign bodies**

Foreign Body in Ear		Foreign Body in Nose	
Clinical Features	Number (Percentage)	Clinical Features	Number (Percentage)
Asymptomatic	69 (61.06%)	Asymtomatic	37 (56.92%)
Ear pain	13 (11.50%)	Unilateral foul smelling nasal discharge	23 (35.38%)
Ear discharge	22 (19.46%)	Nasal irritation	5 (7.70%)
Ear bleeding	20 (17.70%)	Nose block	12 (18.46%)
Aural fullness	17 (15.04%)	Unilateral non-foul smelling nasal discharge	7 (6.15%)
Decreased Hearing	25 (22.12%)	Unilateral blood stained discharge	3 (4.61)
Tinnitus	5 (4.42%)	Pain	10 (15.38%)
Pruritic Ear	7 (6.19%)	Sneezing	2 (3.07%)



**Fig. 1:** Foreign body of ear (a) Endoscopy showing tick in external auditory canal. Tick in inset. (b) CT scan of temporal bone showing foreign body in external auditory canal. Peanut in inset.

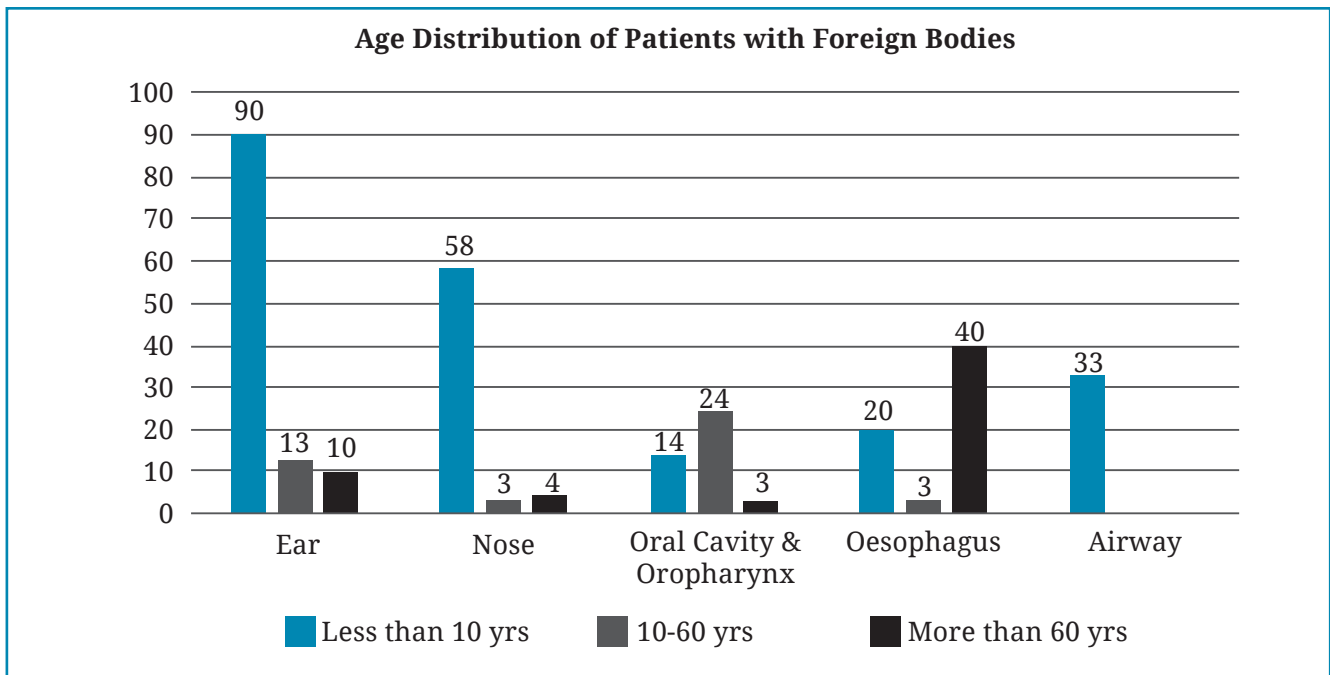


Fig. 2: Age distribution of patients with foreign bodies in upper aerodigestive tract

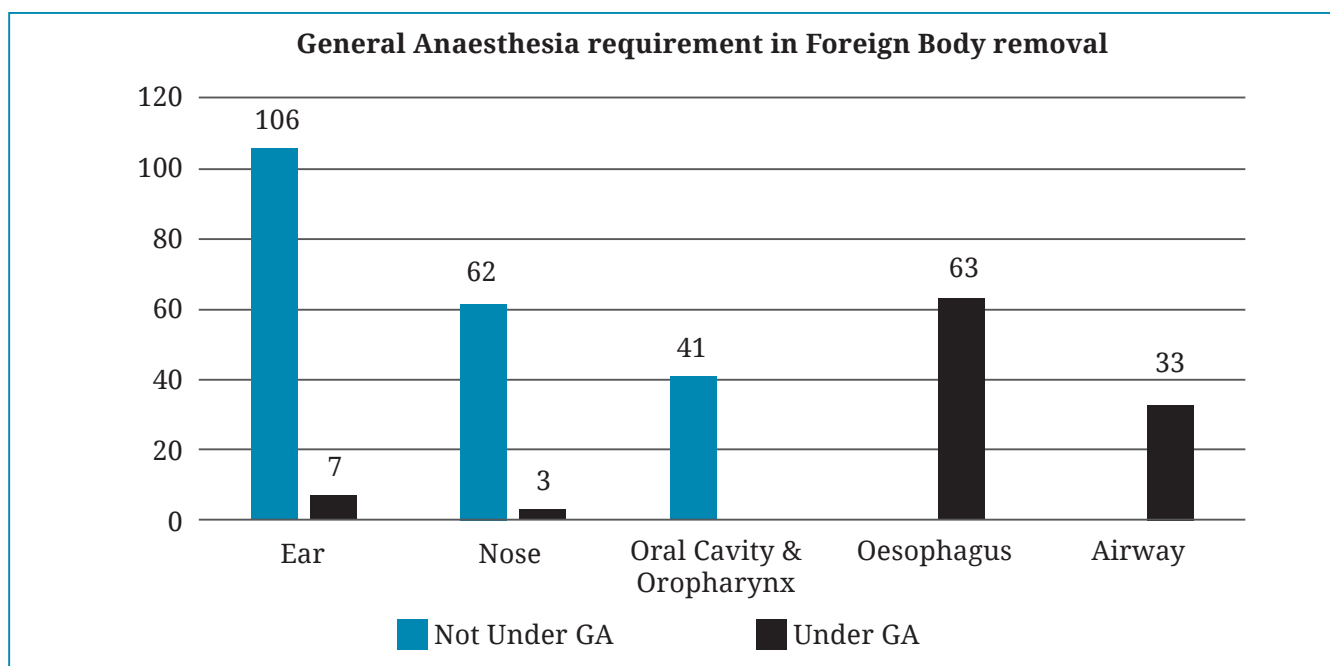


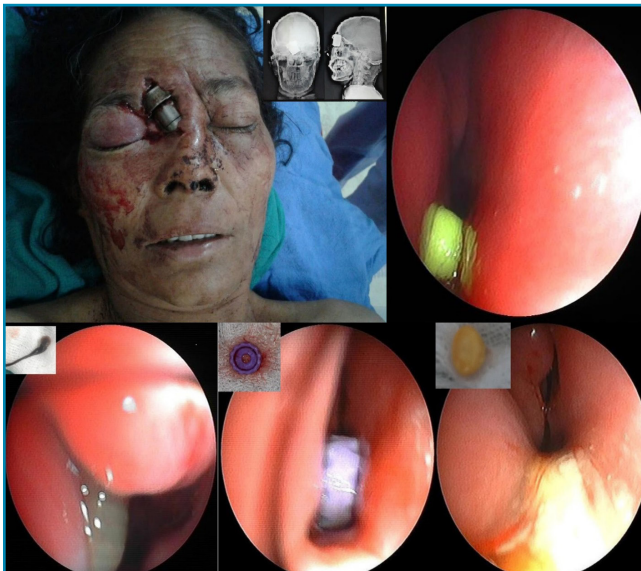Fig. 3: General anaesthesia requirement in foreign body removal in upper aerodigestive tract

vallecula (14.63%) and floor of mouth (4.88%). All foreign bodies were removed in the outpatient department, as seen in Figure 3.

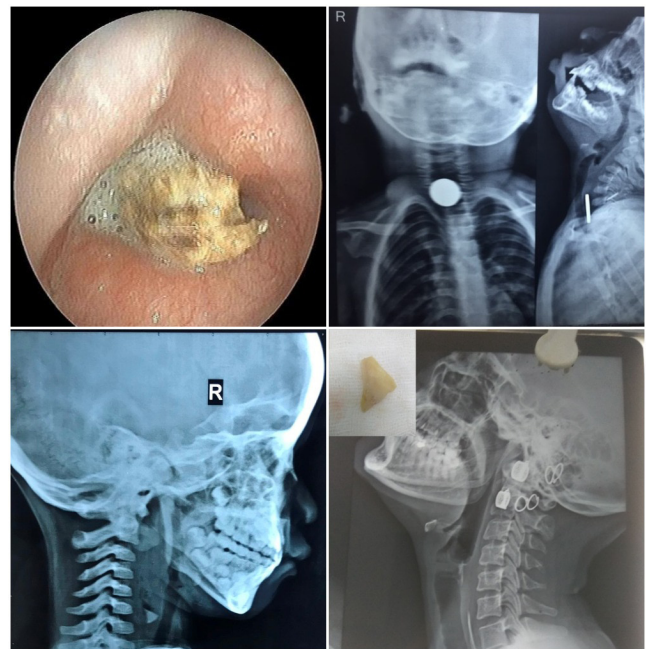
#### Foreign Bodies in the Oesophagus

63 patients presented to the hospital with a foreign body in the oesophagus. Their main complaint was dysphagia. In every case, x-ray of soft tissue of neck was done to confirm the diagnosis. The most common foreign body was bone, seen in 63.50% of the cases. This was followed by meat bolus, coin, dentures and metallic objects as shown in Figure

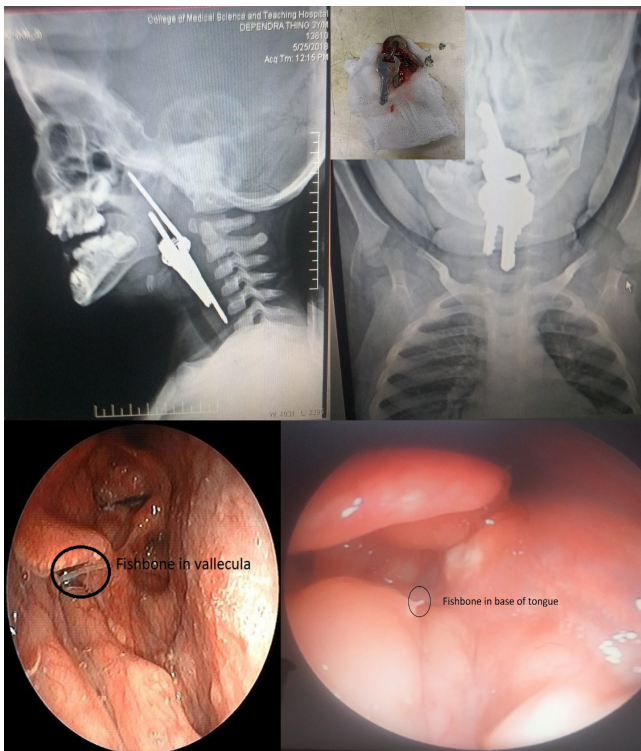
6. The most common site of enlodgement of the foreign body was just distal of cricopharyngeal sphincter seen in 45 (71.49%) cases, followed by midoesophagus and distal oesophagus. 8 (12.70%) cases presented with concomitant retropharyngeal abscess. The abscess was drained. In two cases of retropharyngeal abscess, patient developed mediastinitis. There was one mortality in mediastinitis. The most common age group was more than 60 years, as seen in Fig. 2. All foreign bodies were removed under general anaesthesia, as seen in Fig. 3.



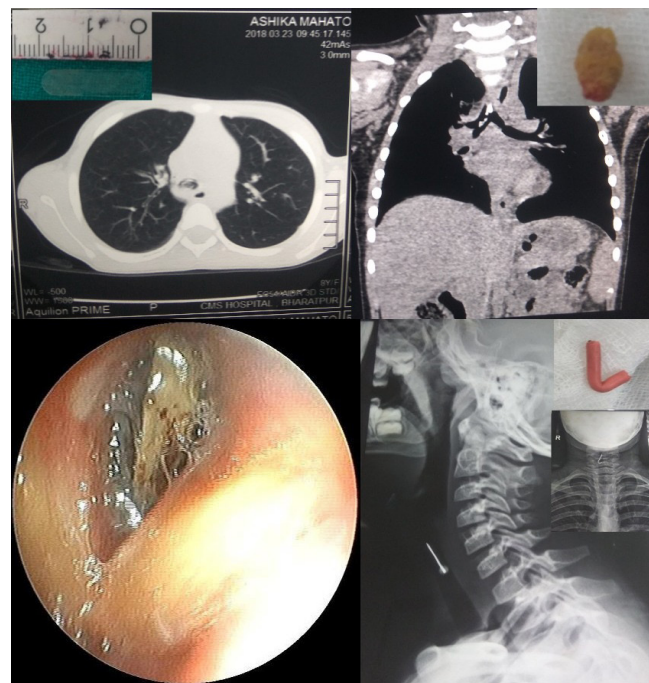
**Fig. 4:** Foreign bodies in nose (a)Vent weight pressure regulator breaking nose. Inset showing X ray in anteroposterior and lateral view. (b) Endoscopy of nose showing plastic ball. (c) Endoscopy of nose showing leech. Leech in inset. (d) Endoscopy of nose showing button. Button in inset. (e) Endoscopy of nose showing maize. Maize in inset.



**Fig. 6:** Foreign bodies in oesophagus (a) Endoscopy of oesophagus showing chicken. (b) X-ray of anteroposterior and lateral view of neck showing coin. (c) X-ray of lateral view of neck showing bone with retropharyngeal abscess. (d) X-ray of lateral view of neck showing bone. Chicken bone in inset.



**Fig. 5:** Foreign bodies in oropharynx (a) X-ray of lateral and anteroposterior view of neck showing keys in oropharynx. Keys in inset. (b) Flexible endoscopy picture of fishbone in vallecula. (c) Flexible endoscopy picture of fishbone in base of tongue.



**Fig. 7:** Foreign bodies in airway (a) CT scan chest with squeaker plastic in right bronchus. Squeaker plastic in inset. (b) CT scan chest with peach seed in right bronchus. Peach seed in inset. (c) Endoscopy showing betel nut in subglottis. (d) Lateral neck X-ray showing rubber pin. Inset showing anteroposterior view and rubber pin.

### Foreign Bodies in the Airway

33 patients presented with foreign in the airway. Their main complaints were episodes of choking, dyspnea, cough, cyanosis and fever. Chest X-ray showed foreign body in the airway in 16 cases. In cases of clinical suspicion, CT scan of the chest was done which showed foreign body in the next 14 cases. In the remaining 3 cases, diagnostic rigid bronchoscopy was done to make the diagnosis. The most common foreign body was plant-based seen in 20 patients (60.6%), followed by plastic/metal foreign body seen in remaining 13 patients (39.4%) as in Fig. 7. The foreign body was mostly encountered in the right bronchus (15 cases), followed by left bronchus (10 cases) and subglottic area (8 cases). All patients were children under 10 years of age. All patients underwent rigid bronchoscopy under general anaesthesia for removal of foreign body. No post-operative complications were reported.

## DISCUSSION

In this study, foreign bodies accounted for 12 percent of all otorhinolaryngology emergencies. This statistics is quite similar to the one reported by Mukherjee *et al*<sup>4</sup> in their study, where the incidence was about 11.0%. The male predominance and most common age group (less than 10 years) as shown by the present study is supported by other studies as well.<sup>4,6</sup> Children find pleasure in manipulating the various orifices of the body like ear, nose and oral cavity which might lead to enlodgement of foreign body in ear, nose and throat region and hence the dominance of this case in this age group.

This study also revealed that ear was the most common point of insertion of foreign bodies among young children. Children not only insert objects in their own ears but also into the ears of their siblings and friends. Commonly inserted foreign bodies include cotton bud, bean, bead, paper/plastic, eraser, insect, paddy seed and popcorn kernel. A high incidence of living FBs (ticks, etc.) in our study is explained by the fact that Chitwan district lies in the vicinity of the jungle and villagers of this district go to jungle to collect fodder and graze cattle and thus get in contact with these living organisms. This study showed that majority of the foreign bodies (97.35%) were removed in the outpatient department only. This is higher in comparison to other case series reporting as low as 70%.<sup>7-9</sup> Different instruments and techniques like Jabson Horne probe, crocodile forceps, cup forceps, syringing and suctioning were used depending on the nature of foreign bodies.

The case of foreign bodies in nose is also prevalent among children under 10 years of age.

Similar findings was observed in many other studies as well.<sup>1,10,11</sup> In our study, around 57.0% of the people were asymptomatic and showed signs of unilateral, foul-smelling, purulent nasal discharge. In adults, foreign bodies were seen in atrophic rhinitis with nasal myiasis and in psychiatric patients. Only three patients (5.0%) underwent general anaesthesia for the removal of foreign bodies. This is in contrast to study done by Prayaga *et al*,<sup>12</sup> where around 25.0% of patients underwent general anaesthesia for foreign body removal. General anaesthesia was required when the foreign body was posteriorly placed, if it was impacted or if the patient was uncooperative.<sup>13</sup> Some other techniques like usage of balloon catheter and nasal positive pressure were not utilized in our study, as were reported in other studies.<sup>14-16</sup>

The most common foreign body identified through this study was fish bone. Chitwan is located on the bank of Narayani River and fish forms the staple diet of many people residing here. The cause of foreign body impaction within the oral cavity may either be iatrogenic or traumatic. Iatrogenic causes include implantation of dental materials and instruments, excessive apical deposition of endodontic material and mucosal amalgam tattoos.<sup>17</sup> Road traffic accidents and bullet injuries are common traumatic causes. Glass pieces are commonly reported traumatic foreign bodies.<sup>18</sup>

Foreign body ingestion is a common problem. In our study, in adult and elderly age group, the most common foreign body was meat bones, whereas in children, the most common foreign body was coins and metallic foreign body (parts of playing objects), as also reported in other studies.<sup>19,20</sup> Heavy alcohol consumption and eating meat simultaneously, along with poor mastication, may be the cause for meat bone impaction in elderly people. In elderly people, loss of teeth, defective peristalsis due to age-related neuromuscular incoordination and poor masticating habits are the predisposing factors for the cause of impaction of meat bone/bolus in the oesophagus.<sup>19</sup> Foreign bodies in the oesophagus must be rapidly diagnosed and treated. This will decrease their morbidity and the length of hospital stay.<sup>21</sup> If the time of reporting such incidents to the hospital is delayed then there are chances of complications like oesophagitis, oesophageal perforation, etc., and longer hospital evaluation and treatment is needed.<sup>22</sup>

In our study, all tracheobronchial foreign bodies (TFB) were present in children under 10 years of age. Similar findings were seen in a study conducted by Rodriguez *et al*.<sup>23</sup> Lack of molar teeth, poor ability to chew, premature airway protection reflex and tendency to explore

environmental objects with mouth put children at high risk.<sup>24</sup> Among 33 children, only 20 had a clear history of foreign body aspiration. Chest X-ray tests helped to diagnose further five more cases. However, a negative finding on chest X-rays cannot rule out TFB diagnosis.<sup>25</sup> CT scan of the chest diagnosed further seven cases. Chest CT scan shows a greater diagnostic sensitivity and specificity for tracheobronchial foreign bodies.<sup>26</sup> In one remaining case, CT scan of the chest was also unable to diagnose the case. As the patient was symptomatic, diagnostic rigid bronchoscopy was performed and foreign body was removed.

In conclusion, foreign bodies in ear, nose and throat regions are common causes of otorhinolaryngological emergencies. However the nature of foreign body and site of enlodgment may differ among different age groups and their place of origin. Most of the cases have history of attempted removal by local quacks before they land up in hospital. Foreign bodies in ear, nose and throat region can potentially be associated with significant complications if utmost care by a skillful person is not provided immediately.

## REFERENCES

- Sarkar S, Roychoudhury A, Roychaudhuri BK. Foreign bodies in ENT in a teaching hospital in Eastern India. *Indian J Otolaryngol Head Neck Surg* 2010; 62: 118–20.
- Schulze SL, Kerschner J, Beste D. Pediatric external auditory canal foreign bodies: a review of 698 cases. *Otolaryngol Neck Surg* 2002; 127: 73–8.
- Banerjee S. Concept of foreign body-its past and present. *Indian J Otolaryngol Head Neck Surg* 1999; 51: 23–30.
- Mukherjee A, Haldar D, Dutta S, Dutta M, Saha J, Sinha R. Ear, nose and throat foreign bodies in children: a search for socio-demographic correlates. *Int'l J Pediatr Otorhinolaryngol* 2011; 75: 510–2.
- Sahin A, Meteroglu F, Eren S, Celik Y. Inhalation of foreign bodies in children: experience of 22 years. *J Trauma Acute Care Surg* 2013; 74: 658–63.
- Afolabi AO. Factors influencing the pattern of self-medication in an adult Nigerian population. *Ann Afr Med* 2008; 7: 120–7.
- Balbani AP, Sanchez TG, Butugan O *et al.* Ear and nose foreign body removal in children. *Int'l J Pediatr Otorhinolaryngol* 1998; 46: 37–42.
- Bressler K, Shelton C. Ear foreign-body removal: a review of 98 consecutive cases. *The Laryngoscope* 1993; 103: 367–70.
- Thompson SK, Wein RO, Dutcher PO. External auditory canal foreign body removal: management practices and outcomes. *The Laryngoscope* 2003; 113: 1912–5.
- Shrestha I, Shrestha BL, Amatya RCM. Analysis of ear, nose and throat foreign bodies in dhulikhel hospital. *Kathmandu Univ Med J* 2012; 10: 4–8.
- Ray R, Dutta M, Mukherjee M, Gayen GC. Foreign body in ear, nose and throat: experience in a tertiary hospital. *Indian J Otolaryngol Head Neck Surg* 2014; 66: 13–6.
- Moorthy PNS, Srivalli M, Rau GV, Prasanth C. Study on clinical presentation of ear and nose foreign bodies. *Indian J Otolaryngol Head Neck Surg* 2012; 64: 31–5.
- Brown L, Denmark TK, Wittlake WA, Vargas EJ, Watson T, Crabb JW. Procedural sedation use in the ED: management of pediatric ear and nose foreign bodies. *Am J Emerg Med* 2004; 22: 310–4.
- Backlin SA. Positive-pressure technique for nasal foreign body removal in children. *Ann Emerg Med* 1995; 25: 554–5.
- Navitsky RC, Beamsley A, McLaughlin S. Nasal positive-pressure technique for nasal foreign body removal in children. *Am J Emerg Med* 2002; 20: 103–4.
- Kalan A, Tariq M. Foreign bodies in the nasal cavities: a comprehensive review of the aetiology, diagnostic pointers, and therapeutic measures. *Postgrad Med J* 2000; 76: 484–7.
- Sumanth KN, Boaz K, Shetty NY. Glass embedded in labial mucosa for 20 years. *Indian J Dent Res* 2008; 19: 160.
- Hunter TB, Taljanovic MS. Foreign bodies. *Radiogr Rev Publ Radiol Soc N Am Inc* 2003; 23: 731–57.
- Adhikari P, Shrestha BL, Baskota DK, Sinha BK. Accidental foreign body ingestion: analysis of 163 cases. *Int'l Arch Otorhinolaryngol* 2007; 11: 267–70.
- Pokharel R, Adhikari P, Bhusal CL, Guragain RPS. Oesophageal foreign bodies in children. *J Nepal Med Assoc* 2008; 47: 186–8.
- Messner AH. Pitfalls in the diagnosis of aerodigestive tract foreign bodies. *Clin Pediatr (Phila)* 1998; 37: 359–65.
- Reilly JS, Cook SP, Stool D, Rider G. Prevention and management of aerodigestive foreign body injuries in childhood. *Pediatr Clin North Am* 1996; 43: 1403–11.
- Rodríguez H, Passali GC, Gregori D *et al.* Management of foreign bodies in the airway and oesophagus. *Int'l J Pediatr Otorhinolaryngol* 2012; 76 Suppl 1: S84–91.
- Higo R, Matsumoto Y, Ichimura K, Kaga K. Foreign bodies in the aerodigestive tract in pediatric patients. *Auris Nasus Larynx* 2003; 30: 397–401.
- Baharloo F, Veyckemans F, Francis C, Biettlot M-P, Rodenstein DO. Tracheobronchial foreign bodies: presentation and management in children and adults. *Chest* 1999; 115: 1357–62.
- Sattar A, Ahmad I, Javed AM, Anjum S. Diagnostic accuracy of chest x-ray in tracheobronchial foreign body aspiration in paediatric patients. *J Ayub Med Coll Abbottabad* 2011; 23: 103–5.