

DIMENSIONS OF FORAMEN MAGNUM FOR ESTIMATION OF SEX IN NEPALESE POPULATION

Maharjan MR,¹ Walung ED,¹ Shrestha R,¹ Acharya J²

¹Department of Forensic Medicine, Maharajgunj Medical Campus, Institute of Medicine, Nepal,

²Department of Forensic Medicine, Kathmandu Medical College, Kathmandu, Nepal

ABSTRACT

Human skull is considered as one of the most reliable bones for sex differentiation. This study is an attempt to estimate sex, using variations in dimensions of Foramen Magnum among the Nepalese population. Most studies on the skull have been carried out in dry skull, using ectocranial measurements. This study on sexual dimorphism in Foramen Magnum of Nepalese population was carried out in wet skull and measurements are taken intracranially by using sliding Vernier's caliper. A cross-sectional study of 96 medico-legal autopsies (53 males and 43 females) was conducted at Department of Forensic Medicine, Institute of Medicine, Kathmandu, to establish reference standards for sexual dimorphism of dimensions of Foramen Magnum. The mean antero-posterior diameter (APD) was found to be 33.45 mm in males and 30.70 mm in females. The mean transverse diameter (TD) was found to be 27.64 mm in males and 25.19 mm in females. Both APD and TD were found to have statistically significant dimorphism between the sexes. Discriminant function analysis showed that the accuracy ranged between 55.8% and 81.4 % with use of both APD and TD showing the most accurate classification. Binary logistic regression showed that 69.8% were correctly classified as female and 79.2 % were correctly classified as male and 75% on overall population.

KEYWORDS

Antero-posterior, Foramen Magnum, sexual dimorphism, transverse

CORRESPONDING AUTHOR

Dr. Eugen Dolma Walung,
Department of Forensic Medicine,
Maharajgunj Medical Campus,
Institute of Medicine, Kathmandu, Nepal
Email: dr.eugendolma@iom.edu.np

INTRODUCTION

Identification is the act of establishing the individuality of a person. The determination of age and sex could facilitate the search for identity of the individual.

Identification of the deceased is vital to the process of forensic investigation.¹ Sex is a principal trait that can be used to establish the identity of the individual. Estimation of sex plays a crucial role, as it narrows the possibility for identification by 50%.² Identification is important for legal, medical, administrative as well as humanitarian purposes.³

The subjectivity of morphological methods of sex estimation can lead to erroneous results, if conducted by a general medical examiner with no formal training in forensic anthropology.^{4,5} The presence of all skeletal elements can result in 98% accuracy, with pelvis alone accounting for 95% and skull 90%. Therefore, individually, skull is considered as one of the most reliable bones for sex differentiation.⁶

Foramen Magnum (FM) is an important landmark of the base of the skull⁷ due to protection afforded by its location.¹ Sexual dimorphism of Foramen Magnum has been studied by both direct metric measurements as well as using computed tomographic images.⁸ The present study has been carried out in wet skull of all medico-legal autopsies and measurements have been collected by directly observing the land marks of the foramen magnum.

MATERIALS AND METHODS

A cross-sectional study of 96 medico-legal autopsies (53 males and 43 females) was conducted to determine sexual dimorphism in the morphometric measurement of Foramen Magnum. The study was conducted at Department of Forensic Medicine, Institute of Medicine, Kathmandu. The selection criteria included, medico-legal autopsies cases of Nepalese individual between the age group of 20 to 65 years with no cranio-facial injuries. During routine autopsy, the scalp was reflected with a coronal incision extending from one mastoid to the other, temporalis muscles scrapped off, and the cranial cavity exposed following circular sawing, at level of Glabella anteriorly, Pterion laterally and just below the external occipital protuberance posteriorly. The dura was incised and brain removed as far from spinal cord as possible. Dura over base of skull was manually removed, and soft tissue attached to the Foramen Magnum, like Tectorial ligament, superior longitudinal band of cruciate ligament of atlas and apical ligament of dens and posterior atlanto-occipital membrane, was incised. With the help of sliding Vernier's caliper, Antero-Posterior Diameter and Transverse Diameter of foramen magnum were directly visualized and the measurements were then recorded.

The points/ landmarks at which the measurements were taken are as follows:

Antero-Posterior Diameter – Maximum Antero-Posterior Diameter between basion (anterior midpoint of basi-occiput) and opisthion (posterior midpoint of Foramen Magnum)

Transverse Diameter – Maximum transverse diameter from the lateral margin of Foramen Magnum perpendicular to the Antero-posterior diameter.

The data analysis was performed using SPSS-17.0. The descriptive statistic and Pearson correlation coefficient were used for analysis of the data. The recorded data was also analyzed using Discriminant function analysis and binary logistic regression equation to determine sexual dimorphism.

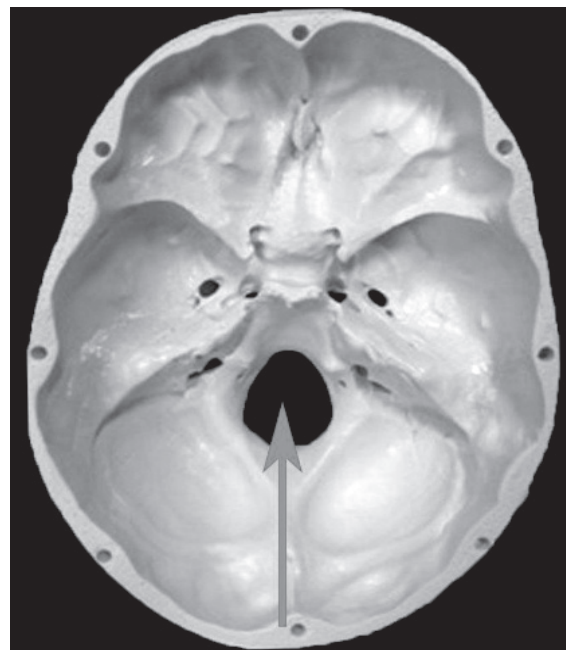


Fig. 1: Intracranial view of Foramen Magnum

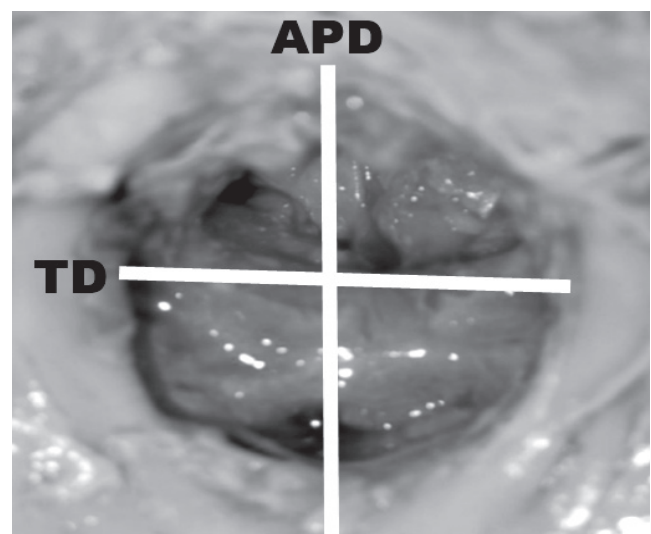


Fig. 2: Foramen Magnum showing the measurement of Antero-posterior diameter (APD) and Transverse diameter (TD) in wet skull.

RESULTS

The study examined 96 medico-legal autopsies performed at Department of Forensic Medicine, consisting of 53 males and 43 females. The mean antero-posterior diameter (APD) was found to be 33.45 mm with standard deviation of ± 2.25mm in males and 30.70 mm with standard deviation of ± 2.28 mm in females.

Similarly, the mean transverse diameter (TD) was found to be 27.64mm with standard deviation of ± 2.02 mm in males and 25.19 mm with standard deviation of ± 2.03 mm in female population.

Correlations between antero-posterior diameter and transverse diameter with both sexes were found to be statistically highly significant with p value of less than 0.001.

APD, Antero-posterior diameter; TD, Transverse diameter

By using the equation, $Sex = APD * 2.518 + TD * 3.402 - 17.102$, if the value were found to be less than 1, then it classifies as female population and if the value were found to be more than 1, it classifies as male population. 81.4 % were correctly classified as female population and 71.7% were correctly classified as male population and 76.0% were correctly classified as original group by conical discriminant function coefficients when antero-posterior diameter and transverse diameter were used in combined.

In classification by discriminant function analysis using APD, 55.8 % female, 75.5 % male and 66.7% of original grouped cases were correctly classified. Similarly, 79.1% female, 64.2 % male and 70.8 % of

Table 1: Classification of samples based on discriminant function analysis of APD, TD and both APD and TD combined

APD	Sex	Predicted Group Membership		Total
		Female	Male	
	Female	55.8	44.2	100
	Male	24.5	75.5	100
66.7% of original grouped cases correctly classified.				
TD	Sex	Predicted Group Membership		Total
		Female	Male	
	Female	79.1	20.9	100
	Male	35.8	64.2	100
*70.8% of original grouped cases correctly classified.				
APD and TD combined	Sex	Predicted Group Membership		Total
		Female	Male	
	Female	81.4	18.6	100
	Male	28.3	71.7	100
*76.0% of original grouped cases correctly classified.				

Table 2: Binary Logistic Classification for APD and TD

		B	S.E.	df	Sig.	Exp (B)
Step 1 ^a	Anteroposterior Diameter	4.129	1.332	1	.002	62.144
	Transverse Diameter	5.420	1.515	1	.000	225.954
	Constant	-27.283	5.759	1	.000	.000

Table 3: Comparison with other previous studies

Variables	Rontal <i>et al</i> (1984) India	Murshed <i>et al</i> (2003) Turkey	Deshmukh <i>et al</i> (2006) India	Gapert <i>et al</i> (2008) Britain	Suazo <i>et al</i> (2009) Brazil	Ukoha U <i>et al</i> (2011) Nigeria	Tanuj <i>et al</i> (2013) India	Present study
FM-APD Males	35.5±2.8	37.2±3.2	34.0±3.03	35.91±2.41	36.5±2.6	36.26±2.3	34.51±2.77	33.25±2.25
FM-APD Females	32.0±2.8	34.6±2.6	34±2.05	34.71±1.91	35.6±2.50	34.39±3.88	33.60±2.63	30.70±2.28
FM-TD Males	29.6±1.9	31.6±2.99	29.0±1.97	30.51±2.60	30.6±2.5	30.09±2.5	27.36±2.09	27.64±2.02
FM-TD Females	27.1±1.6	29.3±2.99	28.9±2.09	29.6±1.53	29.5±1.9	28.16±1.9	26.74±2.36	25.19±2.03

original grouped cases were correctly classified by using TD.

The binary logistic regression equation derived as:
B, coefficient for constant; S.E, Standard Error; df, degree of freedom; Sig, Significance; Exp (B), Exponentiation of the B coefficient

Sex = APD*4.129 + TD * 5.420 – 27.283, here the cut of value is .50. It classified the sex as male, if the value is more than .50 and female if the value is less than .50. The predictability for sexing from foramen magnum was 69.8% female and 79.2 % male and 75% on overall population.

DISCUSSION

Sex determination of the human cranium using more traditional subjective analysis is generally based on size differences, robusticity and alterations on the morphology attributable to muscular attachments.⁹ These differences are unique to each population and are influenced by genetic, environments and socio-economic factors.¹⁰ Sexual dimorphism is population specific and discriminate functions applied to cases belonging to populations other than the source populations used to develop these functions have been known to result in incorrect classification ranging between 32% and 48%.¹¹ It is therefore necessary to study its expression in as many geographically and temporally diverse populations as possible utilizing measurements for sex estimation, rather than subjective observing of morphometric traits that permit the representation of results in an objective manner.

Various studies have been conducted using measurements of the whole cranium,^{12,13} the mandible,¹² as well as dentition,⁹ to determine sex by discriminate function analysis and regression equations. These studies demonstrated that statistically significant differences exist between male and female skulls. These differences can be used to predict sex in an unidentified skull. However, the need for methods to identify sex from cranial fragments becomes apparent when considering the fragile nature of the splanchno-cranium (viscero-cranium). The cranial base has had a remarkable ability to remain intact in cases where the rest of the cranium has been destroyed and researchers have made use of this fact by analyzing statistically

significant sexually dimorphic traits for this region.^{14, 15}

There have been various studies on estimation of sex from measurements of the Foramen Magnum that have been conducted on British,¹ Central European,⁷ Turkish,^{5,16} and Indian,^{17, 18-20} populations.

The present study found mean Antero-Posterior Diameter (APD) and Transverse Diameter to be less than those found in earlier studies.^{1,18,20-23} The present study was conducted in wet skull of all medico-legal autopsies, while most of the previous studies were conducted on dry skull,^{1, 5, 7, 17-20} or using imaging tools like CT-scan or MRI.⁸ Presence of soft tissue in wet skull and shrinkage of dry skull and use of imaging tools might have contributed to these differences in mean value of different diameters. On the other hand, the study conducted in Western countries,^{1, 4,5,7,16, 22} the mean values were found to be much higher than the present study. Increased size of Foramen Magnum in these populations might be due to their large physical development, which are directly influenced by genetic, environmental and socio-economic factors. Hence, this study justifies the need to have our own reference ranges used in other studies may not be suitable in our context.

In conclusion the descriptive statistics in this study show that the mean values of all variables of foramen magnum of the entire sample population are greater in males than in females. Anterior posterior diameter of foramen magnum is greater than transverse diameter in the entire sample population and also greater in male than in female. Statistical analysis shows a highly significant ($p < 0.001$) positive correlation between antero-posterior diameter and transverse diameter of foramen magnum. By using discriminant function analysis, APD were found to be more reliable while sexing male population and TD were found to be more reliable while sexing female population. When both variables were used in combined, female populations were more correctly classified by using discriminant function analysis. By using binary logistic regression equation, the predictability for sexing from foramen magnum was higher in male than female population. The present study can be utilized to analyze and determine sex of individual, in case of mass disaster such as earthquake and air crash and as well as in mutilated bodies. Similar study is suggested to be carried out incorporating larger sample size to check the accuracy of the derived regression.

REFERENCES

1. Gapert R, Black S, Last J. Sex determination from the foramen magnum discriminant function analysis in an eighteenth and nineteenth century British sample. *Int'l J Legal Med* 2009; 123: 25-33.
2. Robinson MS, Bidmos MA. The skull and humerus in the determination of sex: reliability of discriminant function equations. *Forensic Sci Int'l* 2009; 186: 86.
3. Chapman AJ. Death and Deduction – A reasoned approach to Forensic Pathology, *Privately Published*, 2001.
4. Teixeira WR. Sex identification utilizing the size of the foramen magnum. *Am Forensic Med Pathol* 1982; 3: 203-6.

5. Günay Y, Altinkök M. The value of the size of foramen magnum in sex determination. *J Clin Forensic Med* 2000; 7: 147-9.
6. Krogman WM, Iscan MY. The human skeleton in forensic medicine, 2nd ed. Springfield Illinois: Charles Thomas Publisher 1986; 189-243
7. Gruber P, Henneberg M, Böni T, Rühli FJ. Variability of human foramen magnum size. *Anat Rec (Hoboken)* 2009; 292: 1713-9.
8. Sendemir E, Savci G, Cimen A. Evaluation of the foramen magnum dimensions. *Kaibogaku Zasshi* 1994; 69: 50-2.
9. Rosing FW, Graw M, Marre B, Ritz-Timme S, Rothschild MA, Rotzcscher K, Schmeling A, Schroder I, Geserick G. Recommendations for forensic diagnosis of sex and age from skeletons. *Homo* 2007; 58: 75-89.
10. Hamilton ME. Sexual dimorphism in skeletal samples. In: Hall RL (ed) Sexual dimorphism in homo sapiens- a question of size. Praeger Publishers, New York. 1982; Pp 107-163.
11. Kajanoja P. Sex determination of Finnish Crania by discriminant function analysis. *Am J Phys Anthropol* 1989; 24: 29-30.
12. Giles E, Elliot O. Sex Determination by discriminant functional analysis of crania. *Am J Phys Anthropol* 1963; 21: 53-68.
13. Franklin D, Freedman L, Milne N. Sexual dimorphism and discriminant function sexing in indigenous south African Crania. *Homo* 2005; 55: 213-28.
14. Graw M. Morphometrische and orphognostische. Geschlechtsdiagnostik an der menschlichen Schadelbasis. In: Oehmicen M, Geserick G (eds) *Osteologische Identifikation and Altersschätzung Schmidt-Romhild, Lubeck*, 2001 Pp. 103-121.
15. Holland TD. Sex determination of fragmentary crania by analysis of crania base. *Am J Phys. Anthropol* 1986; 70: 203-8.
16. Selma URM, Gokharman D, Kacar M, Tuncbielek I, Kosar U. Estimation of Sex by 3D CT Measurements of the Foramen magnum. *J Forensic Sci* 2005; 50: 1310-1314
17. Raghavendra Babu YP, Kanchan T, Attiku Y, Dixit PN, Kotian MS. Sex estimation from foramen magnum dimensions in an Indian population. *J Forensic Leg Med* 2012; 19: 162-7.
18. Routal RR, Pal GP, Bhagawat SS, Tamankar BP. Metrical studies with sexual dimorphism in foramen magnum of human crania. *J Anat Soc India* 1984; 33: 85-89.
19. Sayee R, Janakiram S, Thomas IM. Foramen magnum measurements of Crania from Karnataka. *J Anat Soc India* 1987; 36: 87-89.
20. Deshmukh AG, Devershi DB. Comparison of Cranial Sex Determination by Univariate and Multivariate Analysis. *J Anat Soc India* 2006; 55: 48-51.
21. Ukoha U, Egwu OA, Okafor IJ, Anyabolu AE, Ndukwe GU, Okpala I. Sexual Dimorphism in the Foramen Magnum of Nigerian Adult. *Int'l J Biol Med Res* 2011; 2: 878-81.
22. Suazo GIC, Russo PP, Zavando MDA, Smith RL. Sexual dimorphism in the foramen magnum dimensions. *Int'l J Morphol* 2009; 27: 21-23.
23. Kanchan T, Gupta A, Krishan K. Craniometric Analysis of Foramen Magnum for Estimation of Sex. *World Acad Sci Engineering Technol* 2013; 7: 500-3.