

Available online at www.nepjol.org.np

Nepal Journal of Health Sciences



Histopathological Examination of Gallbladder in Cholecystectomy Specimens in Lumbini Medical College and Teaching Hospital

Laxmi Lama¹, Manisha Bajracharya Gubhaju¹, Dipesh Shrestha¹, Prasamsha Bajracharya Gubhaju²

¹ Department of Pathology, Lumbini Medical College and Teaching Hospital, Nepal;

² Nepal Manipal Teaching Hospital.

Artical Info

Article History:

Received date: Feb 2, 2026

Revised date: Mar 5, 2026

Accepted date: Apr 5, 2026

Published date: May 15, 2026

Corresponding Author:

Dr. Laxmi Lama

Department of Pathology, Lumbini Medical College and Teaching Hospital, Nepal

Email: lamalax2018@gmail.com

Online Access:



DOI: [10.3126/njhs.v5i2.90679](https://doi.org/10.3126/njhs.v5i2.90679)

Abstract

Introduction: More than 95% of biliary tract infection is caused by Gallstone. Cholecystectomy, the utmost major abdominal operation across the globe. Cholelithiasis establish a numerous histopathological variation in gallbladder mucosa, which is acute and chronic inflammation, cholesterolosis, hyperplasia, granulomatous inflammation, dysplasia, carcinoma in situ and carcinoma.

Objective: To assess the histopathological examination of gallbladder in cholecystectomy specimen in Lumbini Medical College and Teaching Hospital.

Methods: This was retrospective descriptive study of 200 cholecystectomy specimens received in the Department of Pathology, Lumbini Medical College and Teaching Hospital (LMC-TH) Nepal over a period of 2.5 years from November 2022 to May 2025. Clinical details and histopathological data were retrieved from the record file. A wide variety of histomorphological changes in the resected gall bladder were studied.

Results: Out of 200 cases, 134 (67%) were female and 66 (33%) male, with male to female ratio was 1:2. The age of the patients ranged from 8 years to 85 years, with a mean age of 46.75 ± 14.202 years. Histopathological examination showed that chronic cholecystitis was the most usual findings (50%) with a female predominance. The least common variant was adenocarcinoma not otherwise specified, low grade dysplasia and empyema of the gallbladder each in 1% of cases. Analysis of the relationship between serosal and sex of the respondents using the chi-square test yielded P-value of 0.024, indicating significant association. The significant association was also observed between age of the respondents with serosal surface, whereas age of respondents was not found to be significantly associated with serosal surface..

Conclusion: Routine histopathological examination of cholecystectomy specimens is crucial in identifying the non-neoplastic lesion, their complication and incidental gallbladder carcinoma.

Keywords: Cholecystectomy; cholelithiasis; chronic cholecystitis; histopathological; metaplasia.

How to cite (Vancouver Style)

Lama L, Bajracharya Gubhaju M, Shrestha D, Bajracharya Gubhaju P. Histopathological Examination of Gallbladder in Cholecystectomy Specimens in Lumbini Medical College and Teaching Hospital. Nepal J Health Sci. 2025;5(2):36-41.

© The Author(s) 2026 This work is licensed under a Creative Commons Attribution 4.0 International License. (CC BY-NC)



Introduction

More than 95% of biliary tract infection is caused by Gallstone. The stones in gallbladder give rise to morphological alteration.¹ Cholecystectomy, the utmost major abdominal operation across the globe.² Cholelithiasis is associated with a numerous histopathological variation in gallbladder mucosa, which includes acute inflammation, chronic inflammation, cholesterolosis, hyperplasia, granulomatous inflammation, dysplasia, carcinoma in situ and carcinoma.³ Cholelithiasis has strong correlation for the progression of gallbladder carcinoma in up to 40-100% as well as significantly correlated factor independent of age or sex.⁴

Following cholecystectomy, gallbladder carcinoma is often diagnosed as an incidental histological findings.⁵ Majority of gallstones are asymptomatic in more than 80%, however gallstones can also give rise to numerous complications associated with cholecystitis and can result in serious morbidity and mortality.⁶ Cholecystectomy operated for the benign diseases established on clinical, ultrasonological and computerized tomographic scanning skips a remarkable number of early malignant lesions of gallbladder. To prevent such errors with adverse consequences, all cholecystectomy specimens should be routinely examined histologically.⁷ This study aims to evaluate the histopathological lesion in gallbladder specimens encounter cholecystectomy due to cholelithiasis.

Methods

A retrospective descriptive study was conducted on 200 specimen cases from November 2022 to May 2025 in the Department of Pathology, Lumbini Medical College and Teaching Hospital (LMC-TH) Nepal following ethical approval from the Institutional Review Committee (Reference number: IRC- 09/2025).

This study included gallbladder specimens resected via open or laparoscopic cholecystectomy for cholelithiasis. All resected specimens were submitted to the Department of Pathology for detailed histopathological analysis. The sample size was calculated using the formula $n = Z^2 \times p \times q / d^2$, taking $p = 0.75$ [Reference: Sharma S et al.⁸, $Z = 1.96$ at 95% confidence interval, and $q = 0.25$]. Assuming a margin of error of 6% ($d = 0.06$), the calculated sample size was obtained as: $Z^2 = 3.8416$, $p \times q = 0.1875$, and $d^2 = 0.0036$. Substituting these values, $n = (3.8416 \times 0.1875) / 0.0036 = 200.0$ Patients of all age group and both gender were included. Specimens that were autolyzed or absence of gallstones, acalculous cholecystitis were excluded to ensure the reliability of the histopathological findings. Cases with incomplete, inadequate, or missing medical records were excluded from the study. The patient's clinical history was retrieved from histopathology requisition forms and the hospital medical records and histopathological findings were obtained from the Pathology Department. All cholecystectomy specimens were received in 10% formalin, subjected to detailed gross examination, processed, paraffin-embedded, and stained with Hematoxylin and Eosin staining. Sections were obtained from the fundus, body, and neck of the gallbladder. All slides were examined under a light microscope by the consultant pathologist.

Data were analyzed during SPSS version 25. Descriptive data were used to summarize the data. The Chi-square test was applied to assess associations between categorical variables with a P-value of <0.05 considered statistically significant.

Results

The study included 200 cholecystectomy specimens received in the Department of Pathology at Lumbini Medical college. Of these, 134 (67%) were female and male 66 (33%), with male to female ratio was 1:2. Also the patient's age ranged from 8 years to 85 years with mean age of 46.75 ± 14.202 years and the preponderance of gall bladder lesions were notice in the age group 31 to 55 years. (Table 1)

Table 1: Distribution of demographic characteristics of study population.

General Characteristics	Frequency (n)	Percentage (%)
Age of Respondents		
5-30 Years	31	15.5
31-55 years	107	53.5
56-70 years	53	26.5
> 70 years	9	4.5
Mean age of respondents in years \pm SD; 46.75 ± 14.20		
Sex of Respondents		
Female	134	67.0
Male	66	33.0

Among 200 cases, 93.50% of cases had normal serosal surface whereas 6.5% of cases were found to have congestion of serosal surface. (Figure 1)

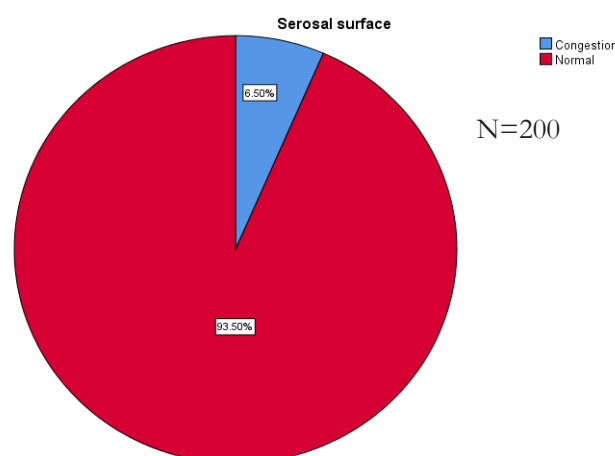


Figure 1: Serosal surface of the study population.

Regarding the wall thickness, 54.0% had thickened wall thickness were as remaining 46.0% of cases were found to have normal wall thickness. (Figure 2)

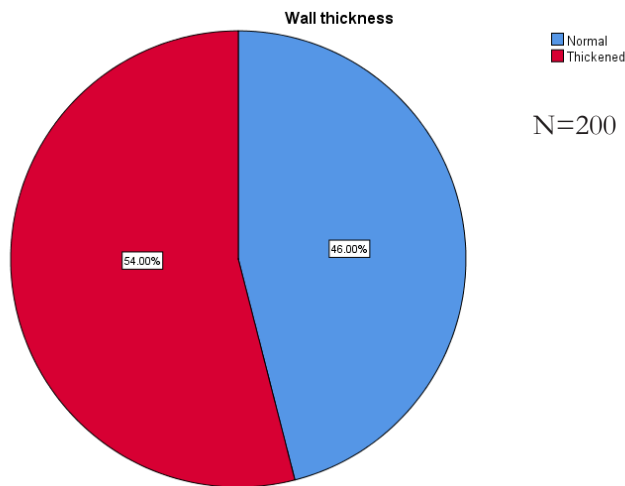


Figure 2: Wall thickness of the study population.

Regarding mucosal patterns more than two third (68.50%) of cases had normal mucosa, followed by strawberry (18.0%), atrophied (8.5%) and least nodular and Polyp (1%). (Figure 3)

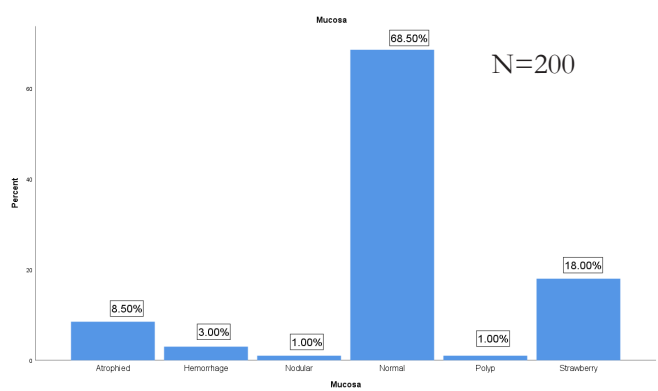


Figure 3: Mucosal pattern of the study population.

Histopathological examination showed chronic cholecystitis was the most usual histological findings (50%) with a female predominance. The second most common findings were chronic cholecystitis with cholesterolosis (18%) followed by chronic cholecystitis with pyloric metaplasia (13%). Other least histological variant findings were acute on chronic cholecystitis in 5%, Adenomatous hyperplasia and spongoid hyperplasia both found in 3%, chronic cholecystitis with intestinal metaplasia in 2.5%, follicular cholecystitis in 2%, Xanthogranulomatous cholecystitis were found in 1.5%. Very least variant was Adenocarcinoma NOS, low grade dysplasia and empyema of gallbladder in 1%. (Table 2)

Table 2: Distribution of Histopathological diagnosis in the study population.

Histopathological Diagnosis	Frequency (n=200)	Percentage (%)
Chronic cholecystitis	100	50.0
Chronic cholecystitis with cholesterolosis	36	18
Chronic cholecystitis with pyloric metaplasia	26	13
Acute on chronic cholecystitis	10	5
Adenomatous hyperplasia	6	3.0
Chronic cholecystitis with spongoid hyperplasia	6	3.0
Chronic cholecystitis with intestinal metaplasia	5	2.5
Follicular cholecystitis	4	2.0
Xanthogranulomatous cholecystitis	3	1.5
Acute cholecystitis	1	0.5
Adenocarcinoma NOS	1	0.5
Low-grade dysplasia	1	0.5
Empyema of gallbladder	1	0.5

The association between serosal surface and demographic characteristics (sex and age of the respondents) were analysed using chi-square test. A statistically significant association was observed between sex of the respondents and serosal surface, whereas age of respondents was not found to be significantly associated with serosal surface. (Table 3)

Table 3: Association of serosal surface with demographic characteristics

Characteristics	Serosal Surface (%)		p-value
	Congestion (n=13)	Normal (n=187)	
Sex of Respondents			
Female	5 (3.7)	129(96.3)	0.024*
Male	8 (12.1)	58(87.9)	
Age of Respondents			
5-30 Years	1 (3.2)	30(96.8)	<0.588
31-55 years	7 (6.5)	100 (93.5)	
56-70 years	5 (9.4)	48 (90.6)	
Greater than 70 years	0 (0)	9 (100.0)	

The association between mucosa with demographic variables. Both the variables were not found to be significantly associated with mucosa (Table 4)

Table 4: Association of Mucosa with demographic variables

Characteristics	Mucosa (%)						p value
	Atrophied (n=17)	Hemorrhage (n=6)	Nodular (n=2)	Normal (n=137)	Polyp (n=2)	Strawberry (n=36)	
Sex of Respondents							
Female	11 (8.2)	3 (2.2)	0(0)	94 (70.1)	2 (1.5)	24 (17.9)	0.303
Male	6 (9.1)	3 (4.5)	2 (3.0)	43 (65.2)	0 (0)	12 (18.2)	
Age of Respondents							
5-30 Years	1 (3.2)	0 (0)	1 (3.2)	26 (83.9)	0 (0)	3 (9.7)	0.178
31-55 years	11 (10.3)	4 (3.7)	0 (0)	63 (58.9)	2 (1.9)	27 (25.2)	
56-70 years	5 (9.4)	2 (3.8)	1 (1.9)	39 (73.6)	0 (0)	6 (11.3)	
> 70 years	0 (0)	0 (0)	0 (0)	9 (100)	0 (0)	4 (44.4)	

The association between wall thickness with demographic variables. Both the variables that is Sex of respondents and age of respondents were not found to be significantly associated with wall thickness. (Table 5)

Table 5: Association of wall thickness with demographic variables

Characteristics	Wall thickness (%)		p value
	Normal (n=92)	Thickened (n=108)	
Sex of Respondents			
Female	66 (49.3)	68(50.7)	0.188
Male	26 (39.4)	40 (60.6)	
Age of Respondents			
5-30 Years	15 (48.4)	16(51.6)	0.926
31-55 years	48 (44.9)	59 (55.1)	
56-70 years	24 (45.3)	29 (54.7)	
Greater than 70 years	5 (55.6)	4 (44.4)	

Discussion

Cholecystectomy is the most frequently performed surgical procedure and is indicated in the management for the majority of gallbladder pathologies, including cholelithiasis, cholecystitis, gallbladder polyps, and carcinoma. Among the aforementioned pathologies, cholelithiasis accounts the utmost common biliary tract pathology worldwide with a prevalence rate at 10%-15%.⁹ In the present study of 200 cholecystectomy specimens received, gallbladder lesions were predominantly observed in females as compared to males accounting 134 (67%) female cases and 66 (33%) male cases with male to female ratio (M: F) ratio of 1:2. which is similar to the study conducted by Bhatta et.al.¹⁰ Stinton LM et.al.¹¹ The gall stone disease is more frequent in female gender particularly over the fertile period. Women are at high risk nearly twice as men to develop stones. Subsequent menopause, the accelerating rate will be in men. The female sex hormones, parity, estrogen replacement therapy, and oral contraceptive use might be the underlying mechanism for the established risk factors for cholesterol gallstone formation.¹²

In this study the patients age ranged from 8 years to 85 years with mean age of 46.75±14.202 years and the preponderance of

gall bladder lesions were notice in the age group 31 to 55 years. This result was similar to the study done by Joshi HN et al.¹³ who described that most of the gall bladder lesions were seen in 3rd to 4th decade of life. However many other studies found that 40 to 50 years was the crucial age group for cholecystectomy.^{14,15} Dissimilarly Veerabhadrapa PS and Uysal et al.^{12,16} reported maximum cholecystectomy cases in the age group more than 50 years. In the current study, entire cholecystectomy specimens encounter chronic inflammation, with chronic cholecystitis being the most common, concerning 100 (50%) patients. Various further studies also revealed chronic cholecystitis as the most common lesion in gall bladder specimens.^{17,18}

The present study found chronic cholecystitis with cholesterolosis in 36(18%) cases. Similarly, Mondal B et al.¹⁹, Kafle et al.⁴ and Bhatt et al.¹⁰ also observed cholesterolosis in 2.9%, 22% and 9.75% of cholecystectomy specimens, respectively. In our study, chronic cholecystitis with pyloric gland metaplasia was the third common finding accounting for 27 (13.5%) cases. of total cholecystectomy cases. The prevalence of pyloric gland metaplasia varied considerably across studies. Mondal B et al.¹⁹ observed pyloric gland metaplasia in 73.7% of cases, indicating a markedly higher prevalence while Thakar BD et al.²⁰ reported 64 cases (8%), a proportion that aligns closely with the results of our study. Also it was assumed that persistent irritation by gallstones and chronic inflammation followed to metaplastic changes of gallbladder mucosa which may sometimes and ultimately lead to the development of carcinoma.²¹

Acute on chronic cholecystitis was found in 10 (5%) cases, histologically characterized by congestion, edema, hemorrhage, acute inflammatory infiltrate and fibroblastic proliferation. Raza et al.²² reported 26.25% cases in their study, Kumbhakar D.¹⁸ and Pathak et al.²³ had also observed in 1.25% and 3% respectively, whereas Acute cholecystitis was found in least number 1 (0.5%) in our study. In this present study out of 200 cases, we found equal number and percentage of chronic cholecystitis with spongoid hyperplasia and adenomatous hyperplasia. Cholelithiasis can induce the epithelium to undergo hyperplastic changes. These are in primary papillary, spongoid or adenomyomatous hyperplasia are the precursor lesions of carcinoma of the gallbladder.²⁴ The follicular cholecystitis in the present study was observed in 4 (2%) cases which was similar to the observation made by Dattal et al.²⁵ (0.6%). We found three cases (1.5%) of Xanthogranulomatous cholecystitis, which reveals marked wall thickening and simulate

with carcinoma macroscopically. There microscopic diagnosis is hence necessary. Similar study was observed in Uysal et al. 16 Bhatta et al.¹⁰ in 0.1% and 1.39% respectively. We also found 0.5% case of Empyema and chronic cholecystitis with low grade dysplasia. Empyema of gallbladder is an rare condition designate by purulent infection of the gallbladder developed on blockage of the cystic duct. The lumen is commonly distended with pus.²⁵ In our study among the non-neoplastic specimens, low grade dysplasia which can be considered as pre-malignant lesions but not true neoplastic lesions. These cases were included in the non-neoplastic group rather than neoplastic group in our study. This gives a variety of inflammatory and pre-malignant histopathological changes of the study cases.

Out of 200 cases in our study, Adenocarcinoma of gallbladder was found in 1 (0.5%). Similar finding were observed by Bharti et al.²⁰ and Mohamed et al.²⁶ in 0.25% and, 0.1% respectively. The signs and symptoms of carcinoma are non-specific, simulating chronic cholecystitis and reveal only after the tumor has invoke significant harm.²⁷ Gallbladder carcinoma is a rare but fatal disease represented by poor prognosis carcinoma constitutes 2- 4 % of all malignant lesions and is the commonest malignancy of the biliary tract.²³ The study's limitations include relatively small sample size and retrospective design and patient population from a single region at Lumbini Medical College and Teaching Hospital, (LMC-TH) which may affect the relevance of the findings to other populations. And also results may vary in regions with a higher prevalence of gallbladder carcinoma emphasizing the need for broader, multicenter research across diverse populations.

Conclusion

Routine histopathological examination of cholecystectomy specimen is crucial in identifying the non-neoplastic lesion, their complication and incidental gallbladder carcinoma. Although the most common histopathological finding is chronic cholecystitis, however histopathological findings of gallbladder following cholecystectomy is immensely variable. Also they state indicating that the metaplasia-dysplasia-carcinoma sequence, a well-established progression in carcinoma. The results strongly recommended that all specimens should undergo routine histopathological assessment to promptly identify any associated pathological abnormalities.

Conflict of Interest: None

AUTHOR'S CONTRIBUTION AND ORCID IDS

Laxmi Lama: Conceptualization, Literature review, writing original draft, review and editing.

Orchid: 0009-0002-6483-0874

Manisha Bajracharya Gubhaju: Literature review and data curation.

Orchid: 0009-0008-0968-7757

Dipesh Shrestha: Methodology, review and editing.

Orchid: 0009-0005-5108-7729

Prasamsha Bajracharya Gubhaju: Data curation and review and editing.

Orchid: 0009-0004-9008-9308

References

- Zhu L, Aili A, Zhang C, Saiping A, Abudureyimu K. Prevalence of and risk factors for gallstones in Uighur and Han Chinese. *World Journal of Gastroenterology: WJG*. 2014 Oct 28;20(40):14942. [\[Full Text\]](#)
- Bhatta S, Singh S. Study of gallbladder lesions and its relationship with serum lipid profile. *Int J Adv Med*. 2018 Sep;5:1245-9. [\[Full Text\]](#)
- Stinton LM, Shaffer EA. Epidemiology of gallbladder disease: cholelithiasis and cancer. *Gut and liver*. 2012 Apr 17;6(2):172. [\[Full Text\]](#)
- Veerabhadrapa PS, Tank P, Singh A, Goel S, Nathwani P. A study of gall stone disease from a tertiary care center of Madhya Pradesh, India. *Int Surg J*. 2017 Jan 25;4:728-31. [\[Full Text\]](#)
- Joshi HN, Singh AK, Shrestha D, Shrestha I, Karmacharya RM. Clinical profile of patients presenting with gallstone disease in University Hospital of Nepal. *Kathmandu University Medical Journal*. 2020 Sep 30;18(3):256-9. [\[Full Text\]](#) [\[DOI\]](#)
- Babu H. A prospective study on emergency laparoscopic or open cholecystectomy in acute cholecystitis in a tertiary care hospital. *International Surgery Journal*. 2019;6(7):2525-32. [\[Full Text\]](#) [\[DOI\]](#)
- Singh P, Gupta SK, Kumar M. A comparative study of open cholecystectomy and laparoscopic cholecystectomy in patients with cholelithiasis. *Int Surg J*. 2018;5(1):253-56. [\[DOI\]](#)
- Sharma S, Walia BS, Randhawa M, Sharma A, Dugg P, Pannu JS. Histopathological changes in gall bladder mucosa in relation to the number, and size of gallstones, and analysis of the findings in the context of age distribution of the patients: A perspective. *Annals of hepato-biliary-pancreatic surgery*. 2023 Aug 31;27(3):277-86. [\[Pubmed\]](#)
- Zhu L, Aili A, Zhang C, Saiping A, Abudureyimu K. Prevalence of and risk factors for gallstones in Uighur and Han Chinese. *World Journal of Gastroenterology: WJG*. 2014 Oct 28;20(40):14942. [\[Full Text\]](#)
- Bhatta S, Singh S. Study of gallbladder lesions and its relationship with serum lipid profile. *Int J Adv Med*. 2018 Sep;5:1245-9. [\[Full Text\]](#)
- Stinton LM, Shaffer EA. Epidemiology of gallbladder disease: cholelithiasis and cancer. *Gut and liver*. 2012 Apr 17;6(2):172. [\[Full Text\]](#)
- Joshi HN, Singh AK, Shrestha D, Shrestha I, Karmacharya RM. Clinical profile of patients presenting with gallstone disease in University Hospital of Nepal. *Kathmandu University Medical Journal*. 2020 Sep 30;18(3):256-9. [\[Full Text\]](#) [\[DOI\]](#)
- Babu H. A prospective study on emergency laparoscopic or open cholecystectomy in acute cholecystitis in a tertiary care hospital. *International Surgery Journal*. 2019;6(7):2525-32. [\[Full Text\]](#) [\[DOI\]](#)
- Singh P, Gupta SK, Kumar M. A comparative study of open cholecystectomy and laparoscopic cholecystectomy in patients with cholelithiasis. *Int Surg J*. 2018;5(1):253-56. [\[DOI\]](#)

15. Uysal E, Sezgin E, Bakir H, Gurer A, Sokucu M. Is routine histopathological gallbladder examination necessary after cholecystectomy? Evaluation of the results of 1,366 cholecystectomy specimens in single center. *Konuralp Medical Journal*. 2017 Jan 1;9(3):243-9. [[Full Text](#)] [[DOI](#)].
16. Anushree CN, Patil SB, Kumar SC, Pallavi S, Jayaprakash HT. Histopathological spectrum of cholecystectomy specimens in a tertiary care hospital in Bangalore. *Indian Journal of Pathology and Oncology*. 2018 Jan;5(1):145-9. [[Full Text](#)] [[DOI](#)]
17. Kumbhakar D. A histopathological study of cholecystectomy specimens. *Journal of Medical Science And clinical Research*. 2016 Jul;7(01). [[Full Text](#)] [[DOI](#)]
18. Mondal B, Maulik D, Biswas BK, Sarkar GN, Ghosh D. Histopathological spectrum of gallstone disease from cholecystectomy specimen in rural areas of West Bengal, India-an approach of association between gallstone disease and gallbladder carcinoma. *Int J Community Med Public Health*. 2016 Dec 22;3(11):3229-5. [[Full Text](#)] [[DOI](#)]
19. Thaker BD, Singh K. Histopathological spectrum of cholecystectomy specimen in Government Medical College Jammu—A hospital-based study. *Int J Sci Res*. 2017;6(6):59-60. [[Full Text](#)] [[DOI](#)]
20. Espinoza JA, Bizama C, García P, Ferreccio C, Javle M, Miquel JF, Koshiol J, Roa JC. The inflammatory inception of gallbladder cancer. *Biochimica et Biophysica Acta (BBA)-Reviews on Cancer*. 2016 Apr 1;1865(2):245-54. [[DOI](#)]
21. Raza AM, Islam SM, Ishrat T, Hossain N, Sarkar SA, Islam SS. Histopathological Disease Spectrum of Cholecystectomy Specimen: A Retrospective Observational Study. *The Journal of Ad-din Women's Medical College*. 2023 Jan 8;11(1):22-5. [[Full Text](#)] [[DOI](#)]
22. Pathak R, Gupta M, Poudel P, Khadka K. Histopathological evaluation of gall bladder in cholecystectomy specimens in a tertiary health care centre of Nepal. *Nepal Medical College Journal*. 2020 Dec 31;22(4):233-7. [[Full Text](#)] [[DOI](#)]
23. Choudhary U, Saroj SK, Shekhawat DS, Akhtar MJ, Bhartiya SK, Mishra A, Saroj SK, Shekhawat DS, Bhartiya SK. Precancerous Gallbladder Lesions in Cholelithiasis: A Histopathological Study. *Cureus*. 2025 Dec 13;17(12). [[Full Text](#)] [[DOI](#)]
24. Dattal DS, Kaushik R, Gulati A, Sharma V. Morphological spectrum of gall bladder lesions and their correlation with cholelithiasis. *Int J Res Med Sci*. 2017 Mar;5(3):840-6. [[Full Text](#)] [[DOI](#)]
25. Benkhadoura M, Elshaikhy A, Eldruki S, Elfaedy O. Routine histopathological examination of gallbladder specimens after cholecystectomy: is it time to change the current practice?. *Turkish journal of surgery*. 2018 Sep 11;35(2):86. [[Full Text](#)] [[DOI](#)]
26. Kumar H, Kini H, Tiwari A. Histological evaluation of 400 cholecystectomy specimens. *Journal of pathology of Nepal*. 2015 Sep 14;5(10):834-40. [[Full Text](#)] [[DOI](#)]

BIOS

Laxmi Lama is a consultant pathologist and working as a lecturer at Lumbini Medical college and Teaching Hospital, Nepal. Her research area of interest include Clinical pathology and hematology.

Email: lamalax2018@gmail.com

Manisha Bajracharya Gubhaju is a consultant pathologist and working as a lecturer at Lumbini Medical college and Teaching Hospital, Nepal. Her research area of interest on Clinical pathology and anatomical pathology.

Email: easymanisha5@gmail.com

Dipesh Shrestha is a third year resident presently pursuing his MD in pathology at Lumbini Medical College and Teaching Hospital. His research area of interest includes Clinical pathology and cytopathology.

Email: stha.dipesh04@gmail.com

Prasamsa Bajracharya Gubhaju is currently working as a medical officer in Manipal Teaching Hospital, Pokhara Nepal. Her research area of interest includes medicine and clinical pathology.

Email: prasamshabajracharya@gmail.com