

Prevalence of Dental Anomalies in Pediatric Patients visiting Tertiary Care Hospital: A Panoramic Radiograph based study

Sagar Adhikari¹, Harleen Bali¹, Ganga Kuikel¹, Reena Lakhemaru¹, Prakriti Maharjan¹, Richa Thapa¹,
Bina Bhattarai²

¹Department of Oral Medicine and Radiology, Kathmandu University School of Medical Sciences, Dhulikhel, Nepal;

²Research and Development Division, Dhulikhel Hospital, Dhulikhel, Nepal

ABSTRACT

Introduction: Dental anomalies are deviations from the normal development, structure, or appearance of teeth. These anomalies can affect the number, size, shape, position, and structure of teeth.

Objective: This study aimed to assess the prevalence of dental anomalies in the pediatric patients visiting Kathmandu University School of Medical Sciences (KUSMS), Dhulikhel Hospital, Nepal.

Methods: A descriptive cross-sectional study was conducted at KUSMS, Dhulikhel Hospital. The panoramic radiographs of the pediatric patients between 6 and 14 years of age in the archive of the hospital were assessed for the presence of dental anomalies.

Results: Of the total 451 panoramic radiographs meeting the inclusion criteria, 55.9% were male and 44.1% were female. The overall prevalence of dental anomaly was 26.8 % with rotation as the most common anomaly (19.3%) followed by missing (6.7%), supernumerary teeth (4.4%), dilaceration 2.4 %, gemination (1.8%), dens-in-dente (1.1%) and peg shaped (0.9%).

Conclusions: The most common dental anomaly among the pediatric patients was rotation followed by missing and supernumerary tooth.

Keywords: Dental anomalies; pediatric; prevalence; panoramic radiograph; Nepal.

INTRODUCTION

Dental anomalies refer to deviations from the typical morphology of teeth. These changes may be either congenital or acquired.

They can have a genetic origin, linked to recessive or multifactorial inheritance, new mutations, or stochastic effect.¹ Additionally, factors like trauma to the primary teeth or alveolar bone, as well as nutritional influences, can impact tooth development.² Anomalies in tooth size, shape, position, number, and structure can lead to problems with arch length and occlusion.³ These dental irregularities can result in dysfunction, reduced activity, defective phonetics, impaired


Correspondence

Sagar Adhikari

Email: sagaradh@gmail.com

Citation

Adhikari S, Bali H, Kuikel G, Lakhemaru R, Maharjan P, Thapa R, Bhattarai B. Prevalence of Dental Anomalies in Pediatric Patients visiting Tertiary Care Hospital: A Panoramic Radiograph based study. *Nepal J Health Sci.* 2024;Jan-Jun;4(1): 57-64.



They can affect a single tooth or be generalized, involving multiple teeth. These anomalies may

esthetics and decreased work productivity, ultimately impacting the quality of life.^{2,4}

Although some research has been conducted on the prevalence of dental anomalies in orthodontic patients in Nepal, there is a noticeable gap in the literature regarding these anomalies in the pediatric population.¹ Incorporating dental anomaly screening in pediatric patients can significantly reduce the burden of future dental treatments by enabling early detection and intervention reducing the need for extensive corrective procedures later in life, ultimately leading to better oral health outcomes and lower healthcare costs.⁵ Moreover, understanding the prevalence of dental anomalies is crucial not only from a clinical perspective, aiding in treatment planning and anticipating potential complications, but also for exploring variations within and between populations.⁶ Thus, the aim of this study was to assess the prevalence of dental anomalies in pediatric patients visiting Kathmandu University School of Medical Sciences (KUSMS), Dhulikhel Hospital, a tertiary center in Nepal.

METHODS

A descriptive cross-section study was conducted at KUSMS, Dhulikhel Hospital from January, 2024 to March, 2024. Ethical clearance was obtained from the Institutional Review Committee of KUSMS (IRC KUSMS Approval No. 03/24). The convenience sampling technique was implied. All the radiographs in

the archive taken in the last two years past the research date were evaluated to avoid selection bias. In reference to the previous study conducted by Sakulratchata et al.⁷, the sample size was calculated as: $N = Z^2p(1-p)/d^2$ where, $Z=1.96$ at 95% confidence interval, $p=13.25\%$ and $d=5\%$. Thus, the final sample size was 177.

Panoramic radiographs of the patients aged between 6 and 14 years were retrieved from the radiographic archives maintained in Department of Oral Medicine and Radiology, KUSMS, Dhulikhel Hospital. The past dental records of the patients maintained in the hospital were reviewed. Radiographs with projection/image acquisition errors/artifacts resulting in non-interpretable panoramic images, patient with history of trauma or missing teeth due to extraction were excluded from the study. A total of 451 radiographs meeting the inclusion and exclusion criteria were included in the study. The radiographs were analyzed in Rainbow TM Image Viewer (Dentium, Korea) software. The radiographs were assessed for presence of anomalies including missing tooth (Figure 1), supernumerary (Figure 2), rotation (Figure 3), peg shaped (Figure 4), microdontia, macrodontia, gemination, fusion, dilacerations, rotation, dens invaginatus (Figure 1) and dens evaginatus based on diagnostic criteria given by Alanzi et al.⁸ All the radiographs were observed independently by two experts of oral and maxillofacial radiology (author 1 and 2) and presence of dental anomaly was confirmed

based on mutual consensus. The data was entered in Microsoft Excel 2019 and analyzed in Statistical Analysis for Social Science (SPSS) version 25 (IBM, Chicago, US). Cross-tabulation were done using descriptive statistics. Chi-square test was used to compare the prevalence of dental anomalies based on gender.

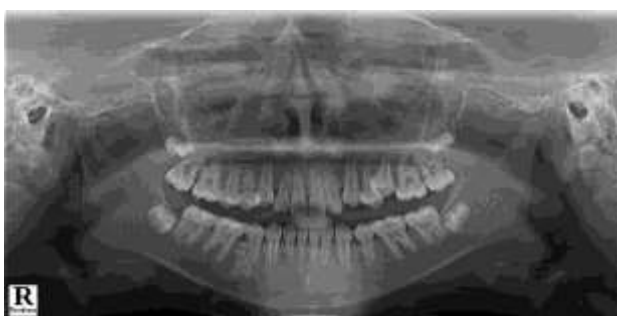

Figure 1: Panoramic radiograph of a patient with dens-in-dente with respect to 12 and missing 22

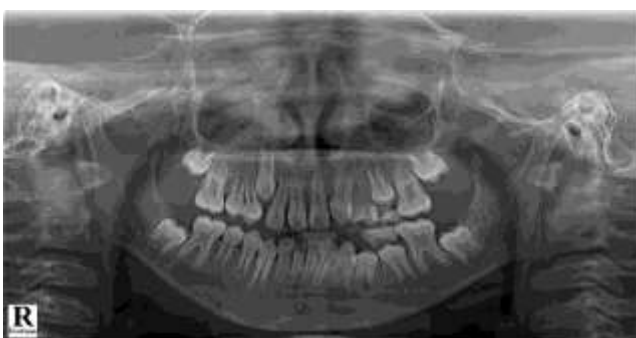

Figure 2: Panoramic radiograph of a patient with supernumerary tooth in maxillary anterior region

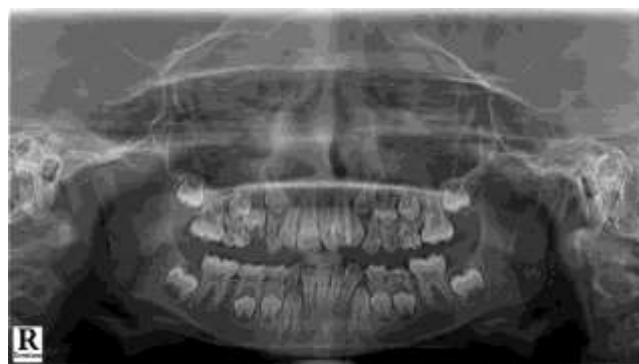

Figure 3: Panoramic radiograph of a patient with rotation wrt 22

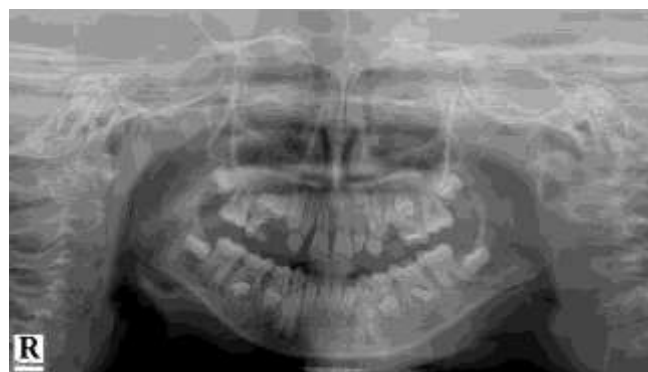

Figure 4: Panoramic radiograph with peg shaped 12 and 22

RESULTS

Of the total 451 panoramic radiographs meeting the inclusion criteria, 252 (55.9%) were male and 199 (44.1%) were female. The mean age of the patients was 10.94 ± 2.53 years. The total prevalence of the dental anomaly was 26.8 % with 60 cases in male and 61 in female. There was no statistically significant difference in the prevalence of dental anomaly among male and female patients ($p=0.10$, Chi-square test). The frequency of distribution of different types of dental anomalies is provided in the Figure 5.

Of all form of anomalies present, the most common was rotation followed by missing teeth. Rotation was more common in maxillary anterior region (47.12%). Single tooth was missing in 18 cases and more than one tooth were missing in 12 cases. Most commonly, teeth were missing in maxilla (77.27%). The most commonly encountered missing teeth was maxillary lateral incisors (40.90 %) followed by

mandibular premolars (11.36%). Of the total 20 cases with supernumerary teeth 14 were mesiodens followed by three cases with supernumerary teeth in premolar region and five in molar region. Gemination was seen in permanent maxillary anterior teeth. All the cases

of dens-in-dente and peg shaped tooth involved permanent maxillary lateral incisors.

The distribution of different types of dental anomaly based on gender are provided in Table 1. There was no statistically significant difference in distribution of types of anomalies based on gender.

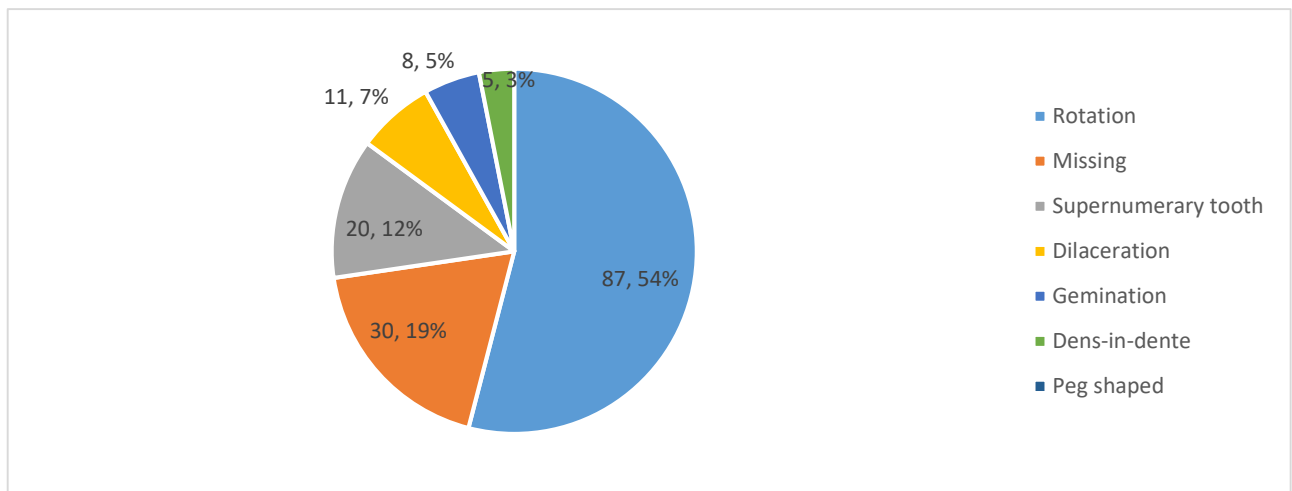


Figure 5: Distribution of different types of dental anomaly

Table 1: Distribution of dental anomalies based on gender

Dental anomaly	Frequency	Prevalence (%)	Male	Female	p value
Rotation	87	19.3	44	43	0.27*
Missing	30	6.7	12	18	0.07*
Supernumerary teeth	20	4.4	14	6	0.19*
Dilaceration	11	2.4	7	4	0.76#
Gemination	8	1.8	2	6	0.15#
Dens-in-dente	5	1.1	2	3	0.66#
Peg shaped	4	0.9	3	1	0.63#

*Chi-square test, $p < 0.05$: statistically significant; #Fischer’s exact test, $p < 0.05$: statistically significant

DISCUSSION

This study provides epidemiology of dental anomalies in pediatric patients visiting KUSMS, Dhulikhel Hospital. In our study, the most common dental anomaly in the pediatric patients was rotation (19.3%) followed by missing (6.7%), supernumerary teeth (4.4%), dilaceration (2.4%), gemination (1.8%), dens-in-dente (1.1%) and microdontia (0.9%).

The rotation refers to the mesiolingual or distolingual displacement of a tooth along its long axis, which can lead to arch length discrepancies and subsequent malocclusion.⁹ In our study, we observed a notably high prevalence of tooth rotation, surpassing the 3.25% reported by Narayanan et al. and aligning closely with the 24.5% prevalence found by Bakhurji et al.^{10,11} Hypodontia or agenesis refers to the failure of formation of tooth. The prevalence of hypodontia in our study population was 6.7% which is consistent with the findings reported by Gokkaya et al. (6.2%).¹² However, remarkably low

prevalence of missing teeth has been reported in Indonesian pediatric population (0.06%).

Supernumerary tooth is the presence of an extra tooth in addition to the normal series of dentition.¹³ In our study, the prevalence of supernumerary teeth was 4.4 % which is more compared to the prevalence reported by Singh et al. (1.87%) and Alberti et al. (0.38%).^{14,15} The most common supernumerary tooth was

mesiodens and it was more common in male compared to female. Similar is the finding reported by Mukhopadhyay and Chen et al.^{16,17} Dilaceration is “an abnormal angulation or bend in the root”.¹⁸ The prevalence of dilaceration in our study was 2.4% which is significantly high compared to the one reported by Alanzi et al. (0.01%) and similar to the finding reported by Sakulratchata et al. (1.5%).^{7,8}

Gemination is an incomplete division of tooth with incompletely or completely separated crown and single root. In our study, gemination was seen in 1.8% of cases which is high compared to the one reported by Bakhurji et al. (0.3%) and Anggraini et al. (0.009%).^{6,10} Dens invaginatus is an invagination of the enamel layer into the dentin and pulp of a tooth.¹⁹ The prevalence of dens invaginatus in our study was 1.1 % which is high compared to 0.17% in Turkish population reported by Colak et al.²⁰ Peg shape is an alteration in the morphology of the tooth resulting in pointed shape of the tooth. In our study all the cases of peg shaped tooth involved maxillary lateral incisor with a prevalence of 0.9% which is less compared to the meta-analysis of prevalence of peg laterals by Hua et al. (1.8%).²¹

The pattern of prevalence reflected in our study differs from the one reported by other authors. This difference may be attributed to the heterogeneity in the study population. Dental anomalies can be influenced by a combination

of genetic and environmental factors. Genetically, mutations or variations in specific genes responsible for tooth development or maturation can lead anomaly of tooth size, structure or number.²² Furthermore, environmental factors, including prenatal and postnatal exposure to drugs, infections, malnutrition, or toxins can disrupt normal tooth development.²³ As dental anomalies have multifactorial risk factors and causes, there might be difference in presentation of these anomalies in different study sites and populations. On the other hand, the retrospective design and reliance on panoramic radiographs in this study may introduce limitations in detecting certain anomalies, further differentiating the results from other studies.

The high prevalence of dental anomalies in pediatric patients highlights a significant public health concern. These anomalies can lead to long-term oral health issues, including malocclusion, esthetics, and compromised function.⁸ The findings underscore the need for enhanced preventive care strategies, such as early dental screenings. Early detection and

treatment of the dental anomalies can prevent complications, reduce the burden on healthcare systems, and improve overall quality of life for children.^{24,25}

CONCLUSION

Thus, the prevalence of dental anomalies in pediatric patients visiting KUSMS, Dhulikhel Hospital was 26.8 %. The most common anomaly was rotation (19.3%) followed by missing (6.7%) followed by supernumerary teeth (4.4%). There was no statistically significant difference in prevalence of dental anomalies based on gender. However, these values represent a small population of a tertiary health center of Nepal. Moreover, the retrospective study design and reliability on panoramic radiographs alone for detection of dental anomalies may pose further limitations. Thus, multi-centric prospective studies incorporating both the clinical and radiographic examination with larger sample size may be required for a generalizable result representative of Nepalese population.

Conflict Of Interest: None.



REFERENCES

1. Gupta SP, Rauniyar S. Prevalence and Distribution of Dental Anomalies among Orthodontic Patients of Kathmandu, Nepal. *Orthodontic Journal of Nepal*. 2019; 9(2): 23-8. [[Full Text](#) | [DOI](#)]
2. Amuasi AA, Sabbah DK, Oti-Achempong A, Mamah RN. Prevalence of Dental Anomalies among Patients Who Report to the Komfo Anokye Teaching Hospital's Orthodontic Clinic. *Open Journal of Stomatology*. 2024; 14(2): 102-17. [[Full Text](#) | [DOI](#)]

3. Aljuaid TSS, Manjunatha BS, Amith HV, Alshehri RA, Alharthi FB, Kariri AM. Prevalence and distribution of selected developmental dental anomalies in Taif, Saudi population. *J Public Health Res.* 2021; 11(1):2132. [[PubMed](#) | [Full Text](#) | [DOI](#)]
4. Matambu EG, Nakagoshi MA, Cepeda RH, González GI, Yamada JR, Quevedo TD, et al. Dental developmental anomalies: An updated review. *International Journal of Applied Dental Sciences.* 2024; 10(2):319-23. [[Full Text](#) | [DOI](#)]
5. Mallineni SK, Alassaf A, Almulhim B, Alghamdi S. Dental Anomalies in Primary Dentition among Arabian Children: A Hospital-Based Study. *Children.* 2024; 11(3):366-79. [[PubMed](#) | [Full Text](#) | [DOI](#)]
6. Aggraini LD, Sekarjati, Augustyana DI. Prevalence of dental anomalies in pediatric patients at Dental and Oral Hospital of Universitas Muhammadiyah Yogyakarta. *Dental Journal.* 2023; 56(1):63-7. [[Full Text](#) | [DOI](#)]
7. Sakulratchata R, Wongma S, Saenmood S, Rianpingwang T, Chiohanangkun S. Prevalence and characteristics of dental anomalies in pediatric patients at a dental hospital in Thailand. *Naresuan University Journal: Science and Technology (NUJST).* 2020; 29(2):73-83. [[Full Text](#) | [DOI](#)]
8. Alanzi A, Bufersen N, Haider S, Abdulrahim M. Prevalence and Distribution of Dental Anomalies in Schoolchildren in Kuwait. *Int Dent J.* 2024; 74(3):566-72. [[PubMed](#) | [Full Text](#) | [DOI](#)]
9. Jahanimoghadam F, Momenidanayee S, Karimifshar M. Correction of severe tooth rotation by using two different orthodontic appliances: Report of two cases. *Journal of Oral Health and Oral Epidemiology.* 2016; 5(1):46-51. [[Full Text](#) | [DOI](#)]
10. Bakhurji EA, Aldossary F, Aljarbo J, AlMuhammadi F, Alghamdi M, Nazir MA. Prevalence and distribution of nonsyndromic dental anomalies in children in eastern Saudi Arabia: A radiographic study. *The Scientific World Journal.* 2021; 2021(1):9914670. [[PubMed](#) | [Full Text](#) | [DOI](#)]
11. Narayanan RK, Jeseem M, Kumar TA. Prevalence of Malocclusion among 10-12-year-old Schoolchildren in Kozhikode District, Kerala: An Epidemiological Study. *Int J Clin Pediatr Dent.* 2016; 9(1):50-5. [[PubMed](#) | [Full Text](#) | [DOI](#)]
12. Gokkaya B, Kargul B. Prevalence and pattern of non-syndromic hypodontia in a group of Turkish children. *Acta Stomatologica Croatica.* 2016; 50(1):58-64. [[PubMed](#) | [Full Text](#) | [DOI](#)]
13. Singhal R, Bhagol A, Singhal P, Namdev R, Rani R, Sikka N. Prevalence and Characteristics of Mesiodens among 4-12-year-old Children of North Indian Subpopulation. *Journal of South Asian Association of Pediatric Dentistry.* 2020; 3(2):71-4. [[Full Text](#) | [DOI](#)]
14. Alberti G, Mondani PM, Parodi V. Eruption of supernumerary permanent teeth in a sample of urban primary school population in Genoa, Italy. *Eur J Paediatr Dent.* 2006; 7(2):89-92. [[PubMed](#) | [Full Text](#)]
15. Singh AK, Soni S, Jaiswal D, Pani P, Sidhartha R. Prevalence of Supernumerary Teeth and Its Associated Complications among School-going Children between the Ages of 6 and 15 Years of Jamshedpur, Jharkhand, India. *International Journal of Clinical Pediatric Dentistry.* 2022; 15(5):504-8. [[PubMed](#) | [Full Text](#) | [DOI](#)]
16. Mukhopadhyay S. Mesiodens: a clinical and radiographic study in children. *J Indian Soc Pedod Prev Dent.* 2011; 29(1):34-8. [[Full Text](#) | [DOI](#)]
17. Cheng FC, Chen MH, Liu BL, Liu SY, Hu YT, Chang JYF, et al. Nonsyndromic supernumerary teeth in patients in National Taiwan University Children's hospital. *J Dent Sci.* 2022; 17(4):1612-8. [[PubMed](#) | [Full Text](#) | [DOI](#)]
18. Nabavizadeh MR, Shamsi MS, Moazami F, Abbaszadegan A. Prevalence of root dilaceration in adult patients referred to Shiraz dental school (2005-2010). *Journal of Dentistry.* 2013; 14(4):160-4. [[PubMed](#) | [Full Text](#)]
19. Dixit PB. Dens Invaginatus: Diagnosis and its treatment options. *Journal of Nepal Dental Association.* 2010; 11(1):82-4. [[Full Text](#)]
20. Çolak H, Tan E, Ayhıkçı BU, Uzgur R, Turkal M, Hamidi MM. Radiographic study of the prevalence of dens invaginatus in a sample set of Turkish dental patients. *Journal of clinical imaging science.* 2012; 2:24-8. [[PubMed](#) | [Full Text](#) | [DOI](#)]
21. Hua F, He H, Ngan P, Bouzid W. Prevalence of peg-shaped maxillary permanent lateral incisors: A meta-analysis. *Am J Orthod Dentofacial Orthop.* 2013; 144(1):97-109. [[PubMed](#) | [DOI](#)]
22. Klein OD, Oberoi S, Huysseune A, Hovorakova M, Peterka M, Peterkova R. Developmental disorders of the dentition: an update. *Am J Med Genet C Semin Med Genet.* 2013; 163(4):318-32 [[PubMed](#) | [Full Text](#) | [DOI](#)]

-
23. Brook AH. Multilevel complex interactions between genetic, epigenetic and environmental factors in the aetiology of anomalies of dental development. *Arc Oral Biol.* 2009; 54(Suppl 1):S3-17. [[PubMed](#) | [Full Text](#) | [DOI](#)]
 24. Silva BS, Paranhos LR, Rode SM. The early diagnosis of dental anomaly and its importance to the dentist. *Journal of Oral Research.* 2017; 6(3):55-6. [[Full Text](#) | [DOI](#)]
 25. Rodd HD, Marshman Z, Porritt J, Bradbury J, Baker SR. Oral health-related quality of life of children in relation to dental appearance and educational transition. *Br Dent J.* 2011; 211(2):E4-10. [[PubMed](#) | [Full Text](#) | [DOI](#)]
-