

## Schwannoma of False Vocal Cord - A Rare Entity

Arju Deo,<sup>1</sup> Daisy Maharjan,<sup>2</sup> Alina Karna<sup>3</sup>

<sup>1</sup>Gajendra Narayan Singh Sagarmatha Zonal Hospital, Rajbiraj;

<sup>2</sup>Pokhara Academy of Health Sciences, Pokhara;

<sup>3</sup>Madan Bhandari Academy of Health Sciences, Hetauda.

Correspondence:

Dr. Arju Deo. Email: deo\_arju@yahoo.com

### ABSTRACT

Laryngeal Schwannoma is rare comprising 0.1 – 1.5% of all benign laryngeal tumors. The most common site in larynx is aryepiglottic fold followed by arytenoids, ventricular folds, and vocal cord. Patients present with the symptoms of hoarseness, dysphagia or globus sensation. We present a 33-year-old male with supraglottic schwannoma who experienced hoarseness of voice for three months. The patient underwent micro laryngeal surgery and submucosal solid tumor of false vocal cord was removed. Postoperative recovery was uneventful and after one month of follow up the patient was improving with no hoarseness of voice.

**Keywords:** Larynx; schwannoma; vocal cord.

*Submitted: May 27, 2021*

*Accepted: June 20, 2021*

*Published: June 28, 2021*

## INTRODUCTION

Nerve sheath tumors within the larynx are extremely uncommon, with an incidence of 0.5-1.5% of all benign laryngeal tumors.<sup>1</sup> In larynx these tumors arise in false vocal cord or the aryepiglottic fold. It is a slow growing encapsulated tumor commonly presenting in the fourth and fifth decade of life, especially women.<sup>2</sup> The main symptoms are usually secondary to the mass effect like dysphagia, dysphonia, pharyngeal globus sensation and respiratory distress with inspiratory stridor. Here we report a supraglottic schwannoma with initial presentation of hoarseness of voice with no significant medical history except for personal habits of smoking and drinking.

## CASE REPORT

A 33-year-old male came to ENT OPD in Institute of Medicine, with history of change in voice for three months. Onset of hoarseness of voice was sudden without any precipitating factors like upper respiratory tract infection, trauma, surgical procedure.

Symptom was refractory to the medications that he took from general practitioners. There was no fever, dysphagia, odynophagia, neck swelling or stridor. Patient had no known systemic illness. Oral cavity inspection showed aphthous ulcer, congestion and grade II trismus.

On indirect laryngoscopy, there was submucosal swelling involving left false vocal cord.

Clinical features: It was a case of 33-year-old male who presented with hoarseness of voice. On direct laryngoscopy there was 2x2 cm firm globular mass arising from left false vocal cord overlying the glottic chink. Bilateral true vocal cords were mobile.

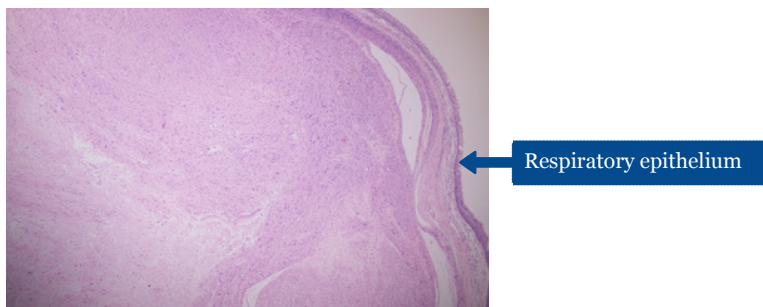
Laboratory findings: Complete Blood Count (CBC) was within normal limit.

Operative procedure: He underwent microlaryngeal surgery under general anesthesia and the biopsy was sent for histopathological examination. Post-operative

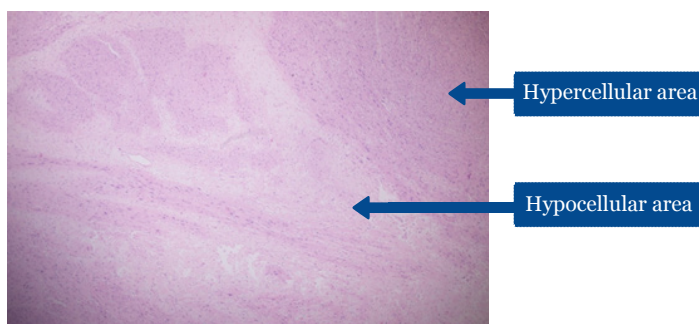
**Citation:** Deo A, Maharjan D, Karna A. Schwannoma of false vocal cord- a rare entity. Nepal J Health Sci. 2021 Jan-Jun;1(1): 60-63

period was uneventful. Gross findings: We received multiple pieces of grey white tissue altogether measuring 2.0x1.5x1.0cm and entire specimen was processed. Microscopic findings: On microscopic examination, tumor was well circumscribed with the tumor cells arranged in fascicles with hypocellular and hypercellular areas as shown in figure 1 and 2. Those tumor cells were spindle in shape with wavy nuclei and some were ovoid to round in shape. Mitosis and necrosis were not

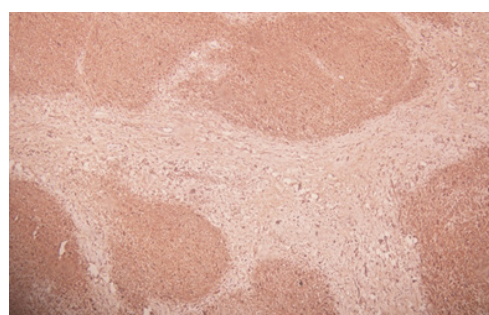
seen. The tumor cells showed mild to moderate degenerative atypia. Mast cells were also noted. Overlying mucosa showed respiratory lining with focal metaplastic stratified squamous lining. Immuno-histochemical staining S-100 was done which showed diffuse cytoplasmic and nuclear staining of the tumor cells as shown in figure 3. These findings were in consistent with the diagnosis of ancient laryngeal schwannoma.



**Figure 1: Haematoxylin and eosin section showing circumscribed mass with overlying respiratory epithelium at 40x.**



**Figure 2: Haematoxylin and eosin section showing hypocellular and hypercellular areas at 40x.**



**Figure3: Immunohistochemistry showing diffuse nuclear and cytoplasmic S100staining at 100x**

## DISCUSSION

Verocay was the first to describe the tumors deriving from Schwann cells in 1908.<sup>3</sup> Schwannoma is a benign peripheral nerve sheath tumor. Schwannomas and neurofibromas are two different types of neurogenic tumors of larynx comprising 0.1% to 1.5% of all benign laryngeal tumors.<sup>4</sup> Malignant transformation is reported in 10% of neurofibromas while in schwannoma it is very uncommon.<sup>5</sup> Schwannomas arise from schwann cells of nerve root, most frequently in the eighth cranial nerve (vestibular Schwannoma/ acoustic Schwannoma/ acoustic neuroma). The fifth cranial nerve is the second most common site. The schwannomas of head and neck grow slowly along peripheral,

cranial or autonomic nerves. A schwannoma is a solitary, encapsulated, slow-growing benign tumor, which is more common in women with increased incidence in the fourth and fifth decades of life. Laryngeal schwannomas are most commonly located in the aryepiglottic folds in the supraglottis (80%) and 20% of them arise from false or true vocal cords.<sup>6</sup> The internal branch of superior laryngeal nerve is presumed to be the most likely origin of laryngeal schwannomas. Symptoms are related to the mass effect of a slow-growing tumor in the larynx, and include sore throat, odynophagia, dysphagia, stridor, dyspnea, dysphonia, hoarseness, and a foreign body sensation in the throat. The clinical

manifestations depend upon site with early presentation being hoarseness of voice and foreign body sensation followed by dysphagia, dyspnea and stridor with increase in size. Schwannomas are diagnosed histologically by immune-histochemical study for S100 protein reaction and by electron microscopic Antoni A and B patterns.<sup>7</sup> The Antoni A growth pattern is characterized by the classically described Verocay bodies, which are an arrangement of spindle cells in compact clusters with palisading nuclei and pooled cytoplasm. The Antoni B growth pattern is characterized by edema and a loose arrangement of spindle cells in a myxoid matrix. The tumor shows variable proportions of these two components. Histopathological examination is the gold standard. Enzinger and Weiss suggest that the diagnosis of schwannoma can be made in the presence of three features: (1) encapsulation; (2) Antoni A and B areas; and (3) a positive S100 reaction.<sup>8</sup>

In contrast, neurofibromas are unencapsulated and comprise a variety of cell types: elongated spindle Schwann cells interwoven with axons and collagen fibers. An important feature is that schwannoma grows extrinsic to the nerve fiber while in neurofibroma, the tumor is entwined with the parental nerve fascicles which makes surgical removal difficult.

Schwannomas must be distinguished from neurofibromas because the latter are more likely to recur and more likely to undergo malignant transformation (10% of cases).<sup>9</sup> Neurofibromas can develop singly or multiply; multiple lesions characterize neurofibromatosis type 1.

Schwannomas arising from perineural Schwann cells grow extrinsically to their parent nerve fascicles and may develop along any somatic or sympathetic

nerve in the body. Whereas neurofibromas originate from perineural fibrocytes, involving nerve fibers and sheath cells. These tumors exhibit diffuse proliferation and are usually intertwined with the nerve trunk.

Direct laryngoscopy and biopsy are required for diagnosis. Immuno-histochemical staining helps to identify the cellular origin. In our case, we used antibodies against protein S- 100 which is characteristic of benign nerve sheath tumor.

Laryngoscopic evaluation reveals a round submucosal mass originating from the aryepiglottic fold and/or vocal cords. With CT scans, a small schwannoma is regarded as a homogenous, enhanced mass. When the size is large (>3 cm), tumors are often heterogeneous, with randomly distributed areas of low attenuation, surrounded by a peripheral ring of enhancement.<sup>10</sup>

Endoscopic excision is recommended for small lesions. Surgery is the treatment of choice for laryngeal schwannomas and there is usually no recurrence on long term follow up after complete surgical excision. However, surgical approach depends on the site and size of tumor.

## SUMMARY

Laryngeal schwannomas are rare benign neurogenic tumors usually located in supraglottic larynx. Vocal cord schwannoma is a very rare benign laryngeal tumor. Confirmatory diagnosis can be made by histopathology. Clinicians should be aware of patient with voice change which may also be due to a neurogenic tumor in larynx.

**Conflict of interest:** None

## REFERENCE

1. Jones SR, Myers EN, Barnes L. Benign neoplasms of the larynx. *Otolaryngol Clin North Am.* 1984; 17(1):151-78. PMID: 6326016.
2. Ramakrishnan Y, Issing WJ. Laryngeal schwannoma: case report and literature review. *ISRN otolaryngol.* 2011 May 31; 2011. doi: 10.5402/2011/540643. PMID: 23724254.
3. Cumming CW, Montgomery WW, Balogh K Jr. Neurogenic tumors of the larynx. *Ann OtolRhinolLaryngol.* 1969; 78(1):76-95. doi: 10.1177/000348946907800107. PMID: 5763193.
4. Chiu CC, Chou SH, Wu CC, Liang PI, Lee KW. Obstructive laryngeal schwannoma in a young female. *World J Surg Oncol.* 2015;13:24. doi: 10.1186/s12957-014-0433-1. PMID: 25889574.

1. Zbauren P, Markwalder R. Schwannoma of the true vocal cord. *Otolaryngol Head Neck Surg* 1999; 121(6):837-9. doi: 10.1053/hn.1999.v121.a99282. PMID: 10580252.
2. Markou K, Dova S, Poulios C, Karkos P. Laryngeal schwannoma as an acute airway presentation. *BMJ Case Rep*. 2016 Mar 11;2016:bcr2016214682. doi: 10.1136/bcr-2016-214682. PMID: 26969364; PMCID: PMC4800277.
3. Chandrashekhara SH, Bhalla AS, Kartikeyan KV, Shukla B, Safaya R. Vocal cord schwannoma: a rare case report. *J Cancer Res Ther*. 2010 Oct; 6(4):543-5. doi: 10.4103/0973-1482.77063. PMID: 21358097.
4. Lo S and Ho WK. Schwannoma of the larynx—an uncommon cause of vocal cord immobility. *Hong Kong Med J*, 2004 Apr;10(2):131-3. PMID: 15075434.
5. Taylor J, Stiefel M, Park SY. Schwannoma of the true vocal fold: a rare diagnosis. *Ear Nose Throat J*. 2006 Jan;85(1):52-9. PMID: 16509246.
6. Plantet MM, Hagay C, De Maulmont C, Mahe E, et al. Laryngeal schwannomas. *Eur J Radiol* 1995;21(1):61-6. doi: 10.1016/0720-048x(95)00655-a. PMID: 8654462.



Rara in Tri-color

*-Namra Kumar Mahato, MPH*