

Pediatric urological malignancies operated at a tertiary cancer center in Nepal: a 5 year experience.

Sulav Pradhan, Umesh Nepal, Bharat Mani Pokharel, Binod Babu Gharti, Gyan Prasad Pokharel, Nirmal Lamichhane

Urology Unit, Dept of Surgical Oncology. B P Koirala Memorial Cancer Hospital, Bharatpur Chitwan, Nepal.

Abstract

Introduction: Pediatric tumor is often an incidental discovery. Improvements in diagnosis modality and treatment have decreased the mortality rates. **Materials and Method:** We performed a retrospective review of pediatric patients operated in the Department of Urology at B.P. Koirala Memorial Cancer Hospital from January 2018 to December 2022. **Results:** A total of 28 pediatric patients were operated for cancers in that time duration. Among them there were 6 cases of Neuroblastoma, 19 cases of Nephroblastoma and 3 cases of Testicular germ cell tumors. **Conclusion:** Despite limited resources, a fair number of pediatric tumors are being managed in BPKMCH with good results.

Key words: Pediatric Tumors, Wilms tumor, Neuroblastoma, testicular tumor

Introduction:

Diagnosis of any pathology in a child is difficult. Pediatric tumor is often an incidental finding.¹ At presentation, patients may be asymptomatic or report a wide range of associated symptoms, including fever, hematuria, and abdominal pain or distension.¹ Abdominal Pediatric tumors commonly constitute Neuroblastoma (30%), Nephroblastoma (25%), Lymphoma (15%), Germ cell tumor (9%), Hepatoblastoma (9%), Rhabdomyosarcoma (4%) and Hepatocellular carcinoma (1.5%).²

Neuroblastoma represents 8% of all pediatric tumors. It is the most common extra cranial tumor arising from the neural crest that forms the adrenal medulla and sympathetic ganglia.^{3,4} Among these tumours, 89% are diagnosed below the age of 5 and 98% below the age of 10 years.⁴ The location is situated at 75% intraperitoneal, 50% in the adrenal gland and 25% paravertebral. Male gender is affected more than female and at the time of diagnosis, 50 -60% of patients already have metastasis.^{4,5} Nephroblastoma or Wilms' tumor represents 90% of solid renal tumors. It is the most common malignant renal neoplasm.³ It arises from the remnants of the

Correspondence

Dr Umesh Nepal, Consultant Surgeon, Urology Unit, Dept of Surgical Oncology, B.P Koirala Memorial Cancer Hospital. Email: uroumesh@gmail.com

metanephric tissue or nephrogenic crests. Male and female genders are equally affected.

Pediatric germ cell tumors represent about 9% of all pediatric tumors. They comprise a diverse group of neoplasms significantly variable in characteristics.^{6,7} Although they do share a common origin from the progenitor germ cells, they may develop due to variations from normal differentiation or aberrant migration.^{6,8} Twenty percent of all GCTs are malignant and represent approximately 3% of all pediatric cancers.⁶

The diagnosis may be established with the help of radiological, biochemical and pathological investigations. The treatment is multidisciplinary. Surgery, chemotherapy and radiotherapy may be opted for depending on the stage, the histological type, staging, associated comorbidities and the child's tolerance to therapy.

In the past 3-4 decades, there has been a significant development in management of cancer disease as a whole. Similarly substantial progress has been made in the management of pediatric solid tumors as well. Better survival and prognosis is the result of understanding of the natural history of the disease, proper histologic characterization, better means to accurately determine the stage and better treatment modality in terms of surgery, chemotherapy and radiation therapy.⁹

Materials and Methods:

We performed a retrospective review of pediatric patients treated in the Department of Urology in B.P. Koirala Memorial Cancer Hospital from January 2018 to December 2022.

Ethical clearance was taken from institutional review committee of B P Koirala Memorial Cancer Hospital and being a retrospective study, the informed consent was waived off. A retrospective review of the procedure was done and expressed as frequency and percentage.

The histopathological and demographic data of 28 intra-abdominal tumors of both sexes under 16 years of age was collected and analyzed to determine the various morphological types of intra-abdominal tumors in relation to age and sex.

Results:

A total of 28 pediatric patients were operated on for various Urological cancers in that time period. Among them there were 6 cases of Neuroblastoma, 19 cases of Nephroblastoma and 3 cases of Germ cell tumor.

Table 1 : PATIENT PRESENTATION AND FREQUENCY

Characteristic	Frequency
Age	4.4 (3months to 11yrs)
Gender	
Male	18
Female	10
Presenting symptom	
Abdominal mass	22
Fever	10
Pain	2
Testicular mass	3

There was a total of 18 male and 10 female patients (M/F:1.8:1). The most common presenting symptom was abdominal mass in 22 patients (78.57%) followed by fever in 10 patients (35.71%). Among 6 cases of Neuroblastoma, 3 were male and 3 were

female M/F: 1:1. Among 19 patients with Nephroblastoma, 12 were male and 7 were female (M/F: 1.7:1). With regards to the management of Nephroblastoma, 13 were treated with chemotherapy first approach as per SIOP protocol while 6 were treated with upfront surgery approach as per NWTSG protocol. Favorable histology was diagnosed in 76.9% and unfavorable histology in 23.1% of the patients. Four patients (66.67%) showed intermediate risk and 2 (33.3%) showed high risk histology. Three patients presented with testicular swelling/mass and all 3 were diagnosed as yolk sac tumor on pathological analysis.

Table 2 RESULTS, FREQUENCY AND PERCENTAGE

DIAGNOSIS	n	%
NEUROBLASTOMA	6	21.42
NEPHROBLASTOMA	19	67.86
SIOP	13	68.4
NWTSG	6	31.6
GERM CELL TUMOR	3	10.7

As per follow up data, 68% of the patients treated for Neuroblastoma, 79% of Nephroblastoma and 100% of Germ cell tumors are still under regular follow up during this period of 5 years.

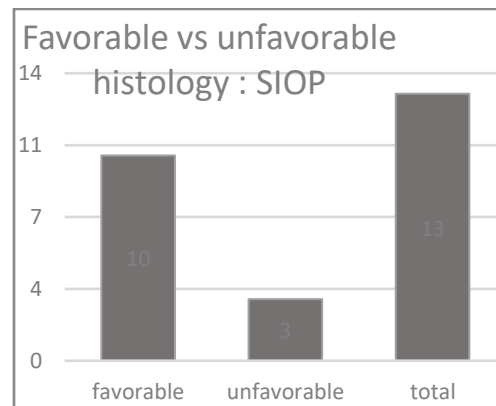
Discussion:

Pediatric tumors are mostly incidentally diagnosed. The development in the medical field has led to early diagnosis and early treatment and better survival for these conditions. The treatment is a multimodal approach including surgery, chemotherapy and radiotherapy and other treatments. The treatment options depend on the stage, histology and ECOG status of the patient at

presentation. Among the common pediatric tumors, we only encountered the mentioned three types of tumors.

The incidence of Neuroblastoma in this series is 28.57%. Although a male predominance has been described in other studies, both genders were equally affected in our study. Similarly, the incidence of Nephroblastoma is around 67.85%. We noted a male predominance in the incidence of Nephroblastoma. Studies from India and Europe have shown equal male/ female incidence and studies from America reports a female predominance.^{10,11,12} Abdominal mass was the most common presenting symptoms in our study (78.57%). Similar studies from UK and India reports about 75% of the patients presented with abdominal mass.^{10,13}

Figure 1: Histology: Favorable vs unfavorable



The findings are comparable to other studies done.^{16,17} The NWTSG reports an 88.8% of favorable histology.¹⁸ Similarly when NWTSG approach, 4 patients (66.67%) showed intermediate risk and 2 (33.3%) showed high risk histology. Similar study shows a lower percentage of patients with intermediate risk and high percentage of high-risk histology.¹⁶

The findings are comparable to other studies done. The NWTSG reports an 88.8% of favorable histology.¹⁸ Similarly when NWTSG approach, 4 patients (66.67%) showed intermediate risk and 2 (33.3%) showed high risk histology. Similar study shows a lower percentage of patients with intermediate risk and high percentage of high-risk histology.¹⁶

Figure 2: Histology of the tumors

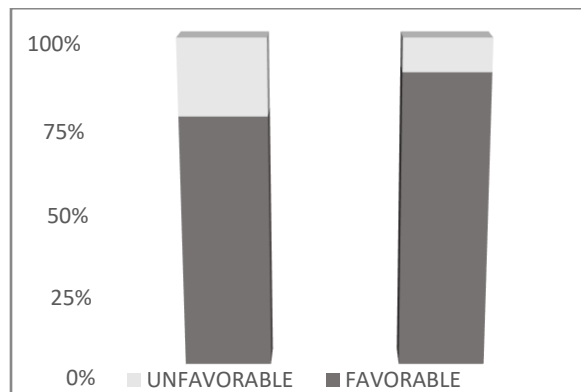
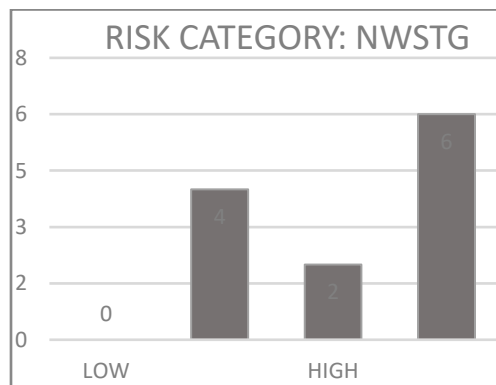


Figure 3: Risk Category



Improvements in diagnosis modality and treatment have decreased the mortality rates of many diseases. The similar is the case with Nephroblastoma. The overall survival rate was 79% in the study. NWTSG reports an 89% overall survival rate.¹⁸ Similar studies done in a similar geographic region shows survival rates around 80-87.5.^{10,16} The patients who lost follow up also were included in this category. Lower socioeconomic status,

awareness about disease and lack of facilities may have contributed to lost follow up. Better counseling programs and follow up incentives may decrease the number of defaulters.

The incidence of pediatric germ cell tumors is rather low. In the study also we encountered only 3 cases of testicular tumors. All of the histology came out to be yolk sac tumors. Yolk sac tumors are the most common germ cell neoplasm among prepubertal patients.¹⁹ With very low number of germ cell neoplasm encountered in the time duration, further analysis seemed unreasonable.

Conclusion:

A fair number of pediatric tumor cases have been managed with good results in BPKMCH despite limited resources available. The survival rates are similar to international standards. A larger sample size is needed to provide better insights.

References:

1. Potisek NM, Antoon JW. Abdominal masses. *Pediatr Rev.* 2017;38(2):101-3.
2. Hanif G. Intra-abdominal tumors in children. *Journal of the College of Physicians and Surgeons--pakistan: JCPSP.* 2004;14(8):478-80.
3. Dumba M, Jawad N, McHugh K. Neuroblastoma and nephroblastoma: an overview and comparison. *Cancer Imaging.* 2014;14(Suppl 1):O15.
4. Park JR, Eggert A, Caron H. Neuroblastoma: Biology, Prognosis, and Treatment. *Pediatric Clinics of North America.* 2008;55(1):97-120.
5. Whittle SB, Smith V, Doherty E, Zhao S, McCarty S, Zage PE. Overview and recent advances in the treatment of neuroblastoma. *Expert Review of Anticancer Therapy.* 2017;17(4):369-86.
6. Horton Z, Schlatter M, Schultz S. Pediatric germ cell tumors. *Surgical Oncology.* 2007;16(3):205-13.
7. Billmire DF. Malignant germ cell tumors in childhood. *Seminars in Pediatric Surgery.* 2006;15(1):30-6.

8. Dehner LP. Gonadal and extragonadal germ cell neoplasia of childhood. *Human Pathology*. 1983;14(6):493-511.
9. Maurer HM. Solid tumors in children. *New England Journal of Medicine*. 1978;299(24):1345-8.
10. Kumar NA, Bezawada S, Chaitanya SV, Gouri SS, Pulla P. A retrospective study of Wilms tumour in our institute. *Int J Contemp Med Res*. 2016;3(8):2015-7.
11. Green DM, D'Angio GJ, Beckwith JB, Breslow NE, Grundy PE, Ritchey ML, et al. Wilms tumor. CA: a cancer journal for clinicians. 1996;46(1):46-63.
12. Shamberger RC, Macklis RM, Sallan SE. Recent experience with Wilms' tumor: 1978-1991. *Annals of Surgical Oncology*. 1994;1:59-65.
13. Pritchard J, Imeson J, Barnes J, Cotterill S, Gough D, Marsden H, et al. Results of the United Kingdom Children's Cancer Study Group first Wilms' Tumor Study. *Journal of clinical oncology*. 1995;13(1):124-33.
14. Sarin YK, Bhatnagar SN. Wilms 'tumor- roadmaps of management. *The Indian Journal of Pediatrics*. 2012;79:776-86.
15. Vujanić GM, Gessler M, Ooms AH, Collini P, Coulomb-l'Hermine A, D'Hooghe E, et al. The UMBRELLA SIOP-RTSG 2016 Wilms tumour pathology and molecular biology protocol. *Nature Reviews Urology*. 2018;15(11):693-701.
16. Sah KP, Rai GK, Shrestha PN, Shrestha A. Wilms' tumor: ten year experience at Kanti Children's Hospital. *Journal of Nepal Paediatric Society*. 2010;30(2):85-9.
17. Pečiulytė V, Ragelienė L, Gričius K. Clinical Features and Survival of Children with Wilms Tumor in Lithuania. *Hypertension*. 2002;2:4.
18. D'Angio GJ, Evans AE, Breslow N, Beckwith B, Bishop H, Feigl P, et al. The treatment of Wilms' tumor. Results of the national Wilms' tumor study. *Cancer*. 1976;38(2):633-46.
19. Brosman SA. Testicular tumors in prepubertal children. *Urology*. 1979;13(6):581-8.