

## Aberrent hepatic arteries, a rare anatomic variant: case report

Rajendra Dhakal<sup>1</sup>, Binay Thakur<sup>1</sup>, Shashank Shrestha<sup>1</sup>, Ashish Kharel<sup>1</sup>, Pankaj Shah<sup>1</sup>, Bibhav Hari Koirala<sup>1</sup>, Shiva Kandel<sup>1</sup>, Deewash Neupane<sup>1</sup>

<sup>1</sup>Department of Surgical Oncology. BP Koirala Memorial Cancer Hospital, Bharatpur, Nepal

### Abstract

Anatomic variations of hepatic arteries are observed in 12-49% cases. But replaced right and left hepatic arteries are extremely rare (0.8%). We report a 61 years old male patient with the diagnosis of gastric cancer. He underwent distal subtotal gastrectomy with D2 lymphadenectomy. Intraoperatively, both right and left hepatic arteries were replaced and were arising from superior mesenteric artery and aorta, respectively.

**Keywords:** *hepatic artery anomaly, gastric cancer, gastrectomy.*

### Introduction

Gastric carcinoma is the third leading cause of cancer related death worldwide.<sup>1</sup> Standard gastrectomy is the principal surgical procedure performed with curative intent.<sup>2</sup> One of the important principles of resection is greater extent of lymph node dissection which directly improves patients survival.<sup>3</sup> Extended lymphadenectomy (D2 resection) involves removal of perigastric lymph nodes, nodes of celiac axis, hepatoduodenal ligament, celiac artery and its branches.<sup>4</sup> The hepatic arterial system arises from celiac trunk which originates directly off the aorta and has three branches-splenic, common hepatic and left gastric artery.<sup>5</sup> The common hepatic artery after giving off gastroduodenal artery(GDA), supra-duodenal and right gastric artery becomes hepatic artery proper which is then divided into two main branches: left hepatic artery (LHA) and right hepatic artery (RHA).<sup>6,7</sup> 'Aberrant' defined

as an anatomical anomaly that redraws the anatomy of a patient who differs from the anatomy of the majority of the population.<sup>8</sup> Anatomic variations of hepatic arteries are frequently observed and have a reported prevalence of 12%–49%.<sup>9</sup>

The most frequently employed classifications for describing hepatic arterial variations in the previous literature are the Michels classification and its modification by Hiatt.<sup>10</sup> Common variations of RHAs are originating from the proximal to middle CHA, GDA, superior mesenteric artery(SMA), celiac axis, aorta, splenic artery and left gastric artery (LGA). Similarly variations of LHAs are arising from the LGA, celiac axis, aorta, and SMA.<sup>11</sup>

### Case

We report a case of 61 years old male patient with complains of vomiting and abdominal fullness for 4 months with anorexia and significant weight loss. Preoperative contrast enhanced computed tomography (CECT)

#### Correspondence

Dr. Rajendra Dhakal, Dept. of Surgical Oncology (Thoracic Unit), BP Koirala Memorial Cancer Hospital Bharatpur, Nepal.  
Email: [rajendradhakal@gmail.com](mailto:rajendradhakal@gmail.com), Phone: +977-9855083425

revealed enhancing circumferential thickening in antral region of stomach with thickness 12 millimeters. Endoscopy and biopsy showed gastric adenocarcinoma. The case was proceeded to radical subtotal distal gastrectomy. Per-operative finding showed ulceroproliferative growth at antropyloric region and multiple enlarged lymph nodes. During meticulous dissection common hepatic artery was not identified so right and left hepatic arteries were traced. The right hepatic artery was identified to arise from the superior mesenteric artery (SMA), and the left hepatic artery originated directly from the anterior aspect of the abdominal aorta and passing behind portal vein (Fig. 1). After proper delineation of vaessels, a complete D2 dissection was performed. Post operative period was uneventful and patient was discharged on 10<sup>th</sup> postoperative day.

### Discussion

There are various classification about variations in the vascular anatomy of the liver as proposed by several authors, including Adachi in 1928, Michels in 1966, Hiatt in 1994 and Abdullah in 2006. There are still some rare vascular variations not described in these classifications.<sup>12</sup>

The classification of Michels modified by Hiatt describes six categories: Hiatt type I -the normal anatomy, Hiatt type II -the LHA arising from the left gastric artery, Hiatt type III -the RHA arising from the SMA , Hiatt type IV -every combination of a double replaced pattern, Hiatt type V -the CHA originating as a branch of the SMA and type VI - the abnormality consisting of an isolated aortic origin of the CHA.<sup>10, 13</sup> Different studies shows Hiatt type III (Fig.2) as most common variant followed by type II.<sup>12</sup>

The hepatic arterial variation observed in this case, where the right hepatic artery arises from the SMA and the left hepatic artery arises from the aorta, is extremely rare. Such anomalies can significantly impact surgical interventions, particularly in patients requiring gastric lymph node dissection, hepatic resections or liver transplantation. The absence of the common hepatic artery in its normal location makes the dissection complicated and may compromise the arterial supply to the liver. It emphasizes the importance of recognizing and characterizing such variations before surgical procedures to minimize potential complications and improve patient outcomes.

In our case, a rare hepatic arterial variant, where the right hepatic artery arises from the superior mesenteric artery, and the left hepatic artery originated from the abdominal aorta was found. In a systematic review of 19013 cases, such anomaly was found in 0.8%.<sup>12</sup>

For surgeons dealing with gastric malignancies and hepatobiliary surgeries it is vital to be aware of such unique anatomical variations to ensure safe and effective surgical procedures. Preoperative imaging plays an important role in identifying these rare hepatic arterial configurations and aids in optimizing surgical planning and decision-making. In our patient, CT images did not show such abnormality, which was possibly due to inappropriate slice thickness and inappropriate timing of contrast. Therefore, surgeon should properly identify the vessels during D2 dissection in such accidentally detected vascular anomaly during surgery. Further studies and documentation of similar

cases are warranted to enhance our understanding of these anatomical variants and improve patient outcomes in complex surgical scenarios.

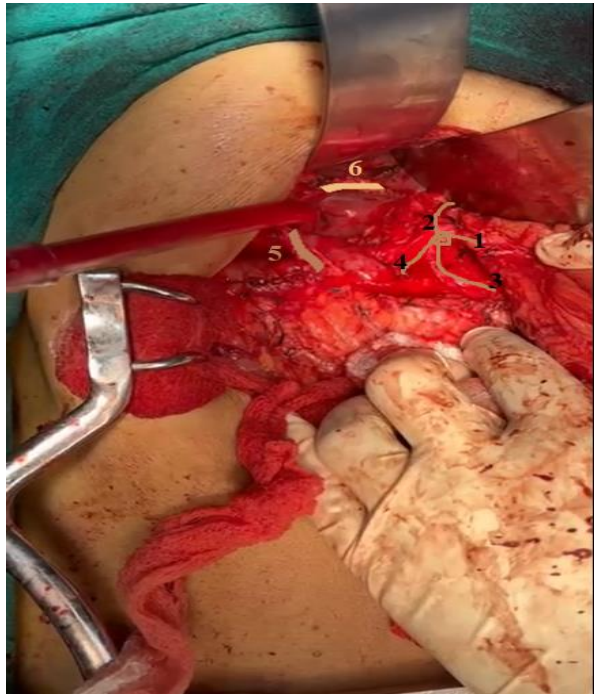


Figure 1. Celiac trunk(1) which gives left gastric artery (2), splenic(3) and one branch directing to duodenum, likely gastroduodenal artery (4). There is right hepatic artery (5) arising from SMA and left hepatic artery (6) arising directly from aorta.

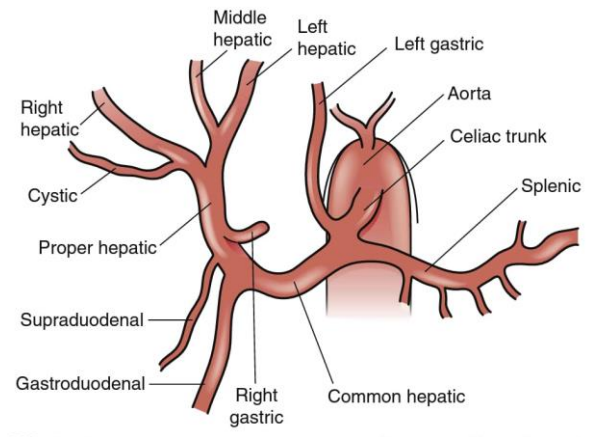


Figure 2. Most common anatomy of celiac axis and hepatic arterial system

#### References:

1. Thrift AP, El-Serag HB. Burden of Gastric Cancer. *Clin Gastroenterol Hepatol*. 2020 Mar;18(3):534-542.
2. Japanese Gastric Cancer Association. Japanese gastric cancer treatment guidelines 2018 (5th edition). *Gastric Cancer*. 2021 Jan;24(1):1-21.
3. Degiuli M, Sasako M, Ponti A; Italian Gastric Cancer Study Group. Morbidity and mortality in the Italian Gastric Cancer Study Group randomized clinical trial of D1 versus D2 resection for gastric cancer. *Br J Surg*. 2010 May;97(5):643-9.
4. Roukos DH, Lorenz M, Encke A. Evidence of survival benefit of extended (D2) lymphadenectomy in western patients with gastric cancer based on a new concept: a prospective long-term follow-up study. *Surgery*. 1998 May;123(5):573-8.
5. Lowe MC, D'Angelica MI. Anatomy of Hepatic Resectional Surgery. *Surg Clin North Am*. 2016 Apr;96(2):183-95. doi: 10.1016/j.suc.2015.11.003.
6. Dandekar U, Dandekar K, Chavan S. Right Hepatic Artery: A Cadaver Investigation and Its Clinical

- Significance. *Anat Res Int.* 2015;2015:412595.  
doi: 10.1155/2015/412595.
7. Skandalakis JE, Skandalakis LJ, Skandalakis PN, Mirilas P. Hepatic surgical anatomy. *Surg Clin North Am.* 2004 Apr;84(2):413-35.
  8. Carlo B, Rosanna PT, Domenico CS, Alfio MG, Roberto A, Biagio DS. Aberrant left hepatic artery from the gastroduodenal artery with no cystic branch: Case report and review of literature. *J Transl Science* 2020;7(3):1-5.
  9. Kooops A, Wojciechowski B, Broering DC, Adam G, Krupski-Berdien G. Anatomic variations of the hepatic arteries in 604 selective celiac and superior mesenteric angiographies. *Surg Radiol Anat.* 2004 Jun;26(3):239-44.
  10. Hiatt JR, Gabbay J, Busuttil RW. Surgical anatomy of the hepatic arteries in 1000 cases. *Ann Surg.* 1994 Jul;220(1):50-2.
  11. Choi TW, Chung JW, Kim HC, Lee M, Choi JW, Jae HJ, Hur S. Anatomic Variations of the Hepatic Artery in 5625 Patients. *Radiol Cardiothorac Imaging.* 2021 Aug 19;3(4):e210007.
  12. Noussios G, Dimitriou I, Chatzis I, Katsourakis A. The Main Anatomic Variations of the Hepatic Artery and Their Importance in Surgical Practice: Review of the Literature. *J Clin Med Res.* 2017 Apr;9(4):248-252.
  13. Paraskevas GK, Raikos A. Multiple aberrant coeliac trunk ramifications. *Singapore Med J.* 2011 Jul;52(7):e147-9.