

Primary Anorectal Amelanotic Melanoma: Case Report and Review of Literature

Sailuja Maharjan¹, Bandana Satyal², Reena Baidya³, Prakash Raj Neupane⁴

¹⁻³ Department of Pathology, B. & B. Hospital, Gwarko, Lalitpur, Nepal, ⁴ Department of Surgical Oncology, B. & B. Hospital, Gwarko, Lalitpur, Nepal

Abstract:

Primary amelanotic melanoma of rectum is a very rare tumor accounting for less than 2% of melanomas. It is a highly aggressive tumor that often tends to invade lymph nodes or metastasize in the early course of disease. The prognosis of this tumor is very bismal with five year survival of less than 20%. We report a case of primary amelanotic melanoma of anorectum in which preoperative biopsy was inconclusive, thus highlighting the role of immunohistochemical markers to reach to a correct diagnosis. This is the first case of amelanotic anorectal melanoma reported from Nepal.

Keywords: Amelanotic melanoma, anorectal melanoma, immunohistochemistry.

Introduction

Anorectal melanoma (ARM) is a very uncommon tumor accounting for less than 1% of all anorectal malignancies and less than 2% of all melanomas.¹ Anorectum is the third common site for melanoma after cutaneous and ocular areas.^{2,3,4} Approximately 30% of anorectal melanomas are amelanotic and hence simulates lymphoma, poorly differentiated carcinoma and GIST on histomorphology.^{5,6} Immunohistochemical analysis is often required for the diagnosis of these tumors.⁷ Due to rarity of this tumor and sparse data in literature, there is no standardized guidelines for staging and also lacks consensus regarding best therapeutic strategy.^{8,9} So, we

report a case of rare case of amelanotic melanoma arising from anorectum.

Case Report

A fifty two year old gentleman presented with complaints of per rectal bleeding for 4 months. There was no history of abdominal pain, change in bowel habits or significant weight loss. Colonoscopy revealed a growth in the lower rectum. CT scan showed a heterogeneous poorly enhancing mass in the left lateral wall of the distal rectum with multiple mesorectal lymph nodes. Biopsy evaluation showed sheets of tumor cells with high N:C ratio, coarse chromatin and high mitotic index. Based on these features, the differential diagnosis considered were

Correspondence: Dr. Sailuja Maharjan, B. & B. Hospital, Gwarko, Lalitpur, Nepal. Email: sailuzaa73@gmail.com, tel: +9779841209628

lymphoma, poorly differentiated carcinoma and melanoma.

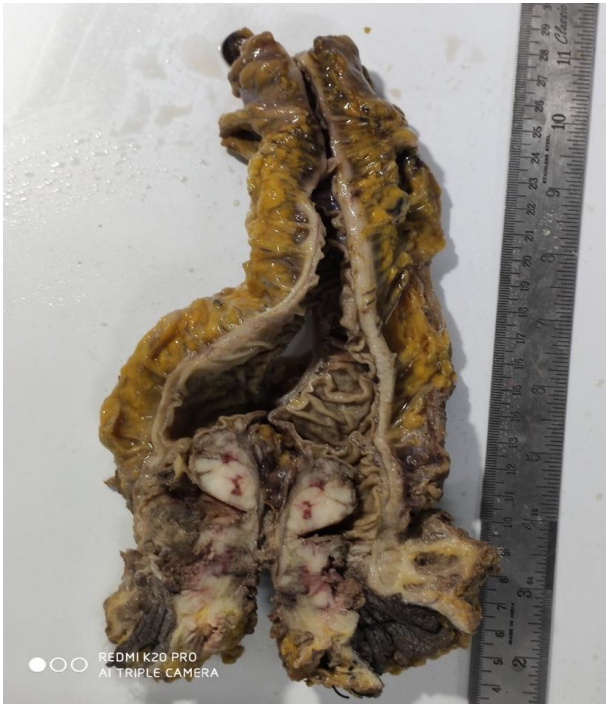

Figure.1 Gross image of rectal melanoma

Immunohistochemical analysis showed positive stains for HMB45 and S100 (Figure 3) and negative stains for CK, CD45, CD20, CD3. The proliferative index was 90%. Then the patient was planned for Abdominoperineal Resection. In surgical gross pathology, a polypoidal tumor measuring 6 x 4 x 2 cm was seen in the distal rectum (Figure1). The mass was grayish white, soft in consistency with surface ulceration. On microscopy, the tumor cells infiltrated up to the perirectal tissue and exhibited variable nuclear pleomorphism and prominent eosinophilic nucleoli in some area (Figure 2). However, no intracytoplasmic pigment was observed (Figure 2). The tumor was continuous with the adjacent dysplastic squamous epithelium with nesting and pagetoid growth pattern suggesting its origin

from anorectum. Lymphovascular invasion was identified and nine perirectal lymph nodes were involved by tumor. Hence, the tumor was diagnosed as primary amelanotic melanoma of anorectum.

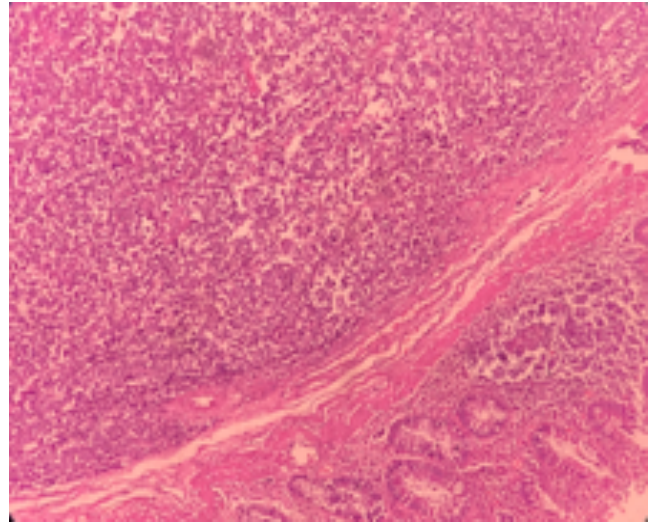


Figure.2 HE stain showing sheets of tumor cells in submucosa.(100X)

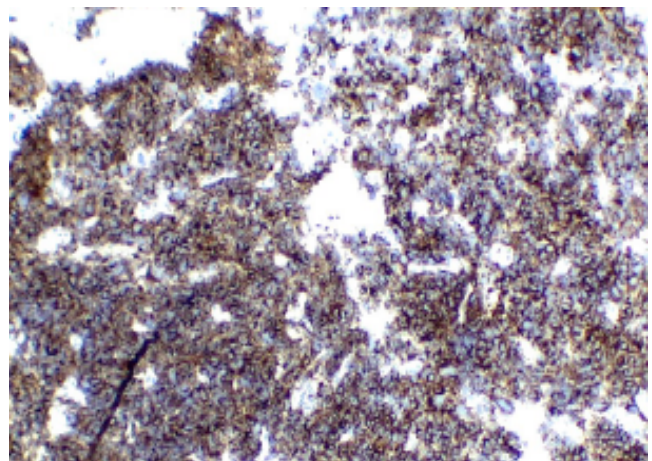


Figure.3 Immunohistochemical stain with diffuse positivity for HMB45

Discussion

ARM is a rare and highly aggressive tumor which was first reported by Moore in 1857.²

Primary ARM arises from the melanocytes located in mucosa below the dentate line which extends proximally in the rectum. Majority of cases occur in 5th to 6th decade and have female preponderance.¹ Unlike cutaneous melanomas, the risk factors for ARM have not been well documented. However, recent data support the association with HIV infection.¹⁰ As described in our case, rectal bleeding was the most common presenting symptom.⁹ Other complaints may be rectal pain, change in bowel habits, rectal prolapse, anal pruritus, sensation of rectal fullness or mass.⁸ These non-specific symptoms often lead to delayed diagnosis or misdiagnosis clinically in about 80% cases, the most common being hemorrhoids.¹⁰ Zhang et al mentioned that distant metastasis was more common in the patients with misdiagnosis or delayed diagnosis than those correctly diagnosed initially.¹ Rarity of these tumors as well as lack of pigmentation further adds to diagnostic confusion.

Chute et al analyzed 17 cases of ARM and reported histological variability as epithelioid, lymphoma like, spindle cell and pleomorphic which leads to wide spectrum of differential diagnosis like poorly differentiated carcinoma, neuroendocrine tumors, lymphoma, epithelioid GISTs, melanoma and sarcoma.⁷ Likewise, the diagnosis was not straight forward on histological evaluation in our case as no melanin pigment was present similar to a study by Tomoika et al. which was initially diagnosed as carcinoma on preoperative biopsy.⁶

Immunohistochemical stains are helpful in establishing correct diagnosis and in our case.

HMB45 and S100 were the diagnostic markers. Other markers expressed are Melan A, vimentin as well as CD 117 which is seen in around 75% of cases as studied by Chute et al.⁷ Expression of CD 117 can lead to diagnostic error in tumor with spindle cell morphology simulating GIST as both the tumors stain positively.³ Similarly, Seya et al reported a case misdiagnosed as neuroendocrine tumor as the tumor stained positive for CD 56, S100, CD 117 and negative for HMB 45. However, Melan A and HMB 45 were both positive on surgical specimen emphasizing the requirement of adequate immunohistochemical panel for correct diagnosis.⁴ Canales and Blesa mentioned that anorectal melanomas are positive for vimentin, CD117, S100 and Melan A with focal positivity for HMB45.⁷ Therefore, melanomas may not stain uniformly for HMB45 or may even stain negative and in such cases Melan A could be positive. Similarly, a study from Japan reported a case of anorectal tumor which stained positive for vimentin, CD 117 and negative for S100 but the excisional biopsy of lymph nodes showed positive stains for S100, Melan A, HMB 45 and tyrosinase. And upon repeating the immunohistochemistry of anorectal tumor they found positive stains for Melan A, HMB45 and tyrosinase and negative for S100.⁵ This highlights the importance of adequate immunohistochemical markers especially if considerable morphologic variability occurs. S100 has high sensitivity (97-100 %) but low specificity (75-85%) whereas HMB45 is highly specific but less sensitive for melanomas.³ Therefore, if malignant melanoma is suspected,

S100 and both melanoma specific markers HMB45 and Melan A should be done.⁵

After the diagnosis of malignant melanoma, it is essential to determine if it is primary or metastatic. The presence of junctional activity beneath squamous epithelium indicates its primary origin like in our case.⁷ If junctional activity is not seen, then detail skin evaluation is required to rule out metastatic lesion.¹

The prognosis of ARM is poor as more than half of the cases present with loco regional or distant metastasis at the time of diagnosis.^{2,3} The thickness of tumor appears to be the most important factor that correlates with the outcome.^{4,5} Even though the treatment option is still controversial, 5 year survival rate is less than 20% despite aggressive surgical and palliative treatment.⁸

Conclusion

Amelanotic melanoma of anorectum is a very rare and highly lethal tumor which is difficult to diagnose. Early detection with correct diagnosis may improve the survival of patients. Adequate immunohistochemical markers should be applied to establish a correct diagnosis in morphologic heterogeneity. Further studies and more clinical trials are required to establish the best therapeutic strategy.

References

1. Zhang J, Sochat M, Feller ER, Zhang J, Sochat M, Feller ER. Anorectal Melanomas : Case Series Let us know how access to this document benefits you Anorectal Melanomas : Case Series. 2016;17.

2. Maqbool A, Lintner R, Bokhari A, Habib T, Rahman I, Rao BK. Anorectal melanoma - 3 Case reports and a review of the literature. *Cutis*. 2004;73(6):409–13.
3. Núñez-Garbín A, Córdova-Pantoja C, Patiño-Ascona S, Santillana-Callirgos J. Anorectal amelanotic melanoma: A case report. *Rev Colomb Gastroenterol*. 2013;28(4): 359–62.
4. Khan M, Bucher N, Elhassan A, Barbaryan A, Ali AM, Hussain N, et al. Primary anorectal melanoma. *Case Rep Oncol*. 2014;7(1):164–70.
5. Baniyaseen KA, Saeed M, SaeedAlbonni AO, Abdulshakour BM, Dairi G, Al-Allaf FA, et al. Primary anorectal amelanotic melanoma:the first case report from Saudi Arabia. *Middle East J Dig Dis*. 2019;11(3): 1–8.
6. Tomioka K, Ojima H, Sohda M, Tanabe A, Fukai Y, Sano A, et al. Primary Malignant Melanoma of the Rectum: Report of Two Cases. *Case Rep Surg*. 2012;2012:1–4.
7. Laforga Canales JB, Gasent Blesa JM. Amelanotic Anorectal Malignant Melanoma: Case Report with Immunohistochemical Study and Literature Review. *Case Rep Oncol*. 2009;2(1):30–7.
8. Yeung H-M, Gupta B, Kamat B. A Rare Case of Primary Anorectal Melanoma and a Review of the Current Landscape of Therapy. *J Community Hosp Intern Med Perspect* [Internet]. 2020;10(4):371–6. Available from: <https://doi.org/10.1080/20009666.2020.1787809>
9. Kothonidis K, Maassarani F, Couvreur Y, Vanhoute B, De Keuleneer R. Primary anorectal melanoma—a rare entity: case report. *J Surg Case Reports*. 2017;2017(3): 1–3.
10. Negbenebor NA, Feller E. A rare case of amelanotic anorectal melanoma. *R I Med J* (2013). 2017;100(9):31–2.