

Original Article

Analysis of the curative effect of limb salvage therapy in patients with soft tissue sarcoma who underwent extensive resection combined with skin flap transplantation

Wei-na Wu¹, Hai-ying Cao², Zhen Feng²

¹ Department of radiology, Affiliated Hospital of Chengde Medical College, Chengde PR China

² Department of traumatology, Affiliated Hospital of Chengde Medical College, Chengde PR China

Abstract

Purpose: Patients who were diagnosed with soft tissue sarcoma (STS) of limbs and met the indications for amputation because of no effective soft tissue coverage after extensive tumor resection were treated with skin flap transplantation and therapeutic courses were observed.

Methods: A total of 23 patients, pathologically diagnosed as soft tissue sarcoma from January 2011 to June 2015 and whose effective soft tissue coverage was not guaranteed due to extensive tumor resections were included. They underwent extensive tumor excision and skin flap grafting. The postoperative follow-up, tumor control and functional recovery was evaluated as per the Musculoskeletal Tumor Society (MSTS) score.

Results: The follow-up time was from 8 to 60 months, with an average follow-up of 39.69 months. Of the 23 patients, 10(43.47%) died of tumor metastasis from 8th to 23rd months after surgery. In these 10 cases, 2 cases (8.70%) subsequently underwent amputation because of local tumor recurrence. The remaining 13 patients are recurrence free till date of follow up. The MSTS limb function score at 3 months after surgery of all patients were 7-28 points, with an average of 22.56 points, and the excellent and fair scores are observed in 91.30% of patients.

Conclusion: For patients who cannot achieve effective soft tissue coverage after extensive resection of soft tissue sarcoma and meet the indications of amputation can have limb preservation by extensive tumor resection combined with skin flap transplantation with a good functional results.

Keywords: Soft tissue sarcoma; Amputation; Skin flap; Limb salvage

Introduction

There is been extensive research on soft tissue sarcoma¹⁻², but it is still in the top of research because of its rise in incidence, death rate and its treatment related complexities. According to the study of Danish scholars, 5-year and 10-year mortality rate of soft tissue sarcoma are 32.8% and 36.0% respectively³. Soft tissue sarcoma is a malignant tumor derived from non-epithelial tissues. The sources include fat, fascia, muscle, fiber, lymph and blood vessels. About 60% of STS occurs in the limbs, 19% in the trunk, and other parts of the peritoneum, back and neck, etc. Even in recent years, the treatment of soft

tissue sarcoma is mostly by amputations rather than limb salvage⁴⁻⁵. Surgical treatment is the method for local control of soft tissue sarcoma, no matter what kind of neoadjuvant / adjuvant treatment is taken before or after surgery. However, if the limb salvage treatment cannot achieve an effective margin free resection of the tumor and effective soft tissue reconstruction, the only effective method is to do amputation⁶, with sacrifice of the limb of patient and deformed body image. In recent years, the development of flap transplantation technology has brought better options to patients with STS. This article

Address of Correspondence: Zhen Feng, department of traumatology, Affiliated Hospital of Chengde Medical College, Chengde PR China, email: fengzhen5057@aliyun.com

retrospectively analyzes the clinical data of 23 patients diagnosed as STS by pathological examination in our hospital, from January 2011 to June 2015. They underwent extensive tumor resection combined with skin flap transplantation for the purpose of limb preservation. They were followed up and evaluated according to Musculoskeletal Tumor Society(MSTS) functional score, and obtained good results⁷. The result proved that extensive tumor resection combined with skin flap transplantation is a feasible method of limb salvage treatment for soft tissue sarcoma.

Methods

Inclusion criteria: All the patients were confirmed by histopathology examination as STS. Clinical data about treatment courses, clinical staging and follow-up records were obtained via the case notes. The ethical clearance was obtained from institutional IRB.

Exclusion criteria: STS patients with dysfunction of liver, kidney or other organs, severe cardiovascular and cerebrovascular diseases with complex conditions difficult to make an effective evaluation were excluded.

General information

Altogether 23 patients were eligible for evaluation, among them 13 were males and 10 were females; they were ranging from 13 to 65 years of age, with an average age of 46.04 years. According to the pathological classification: 8 were undifferentiated pleomorphic sarcoma (UPS), 6 were liposarcoma, 3 were leiomyosarcoma, 2 were dermatofibrosarcoma protuberans (DFSP) and 4 were synovial sarcoma. Anatomical location wise: 3 were of shoulder and upper arm, 8 were around the thigh and hip joint, 7 were around the knee joint and 5 were around the calf. Surgical staging(Enniking stage): 8 in stage IB, 14 in stage IIB, and 1 in stage III. There were 19 cases of primary operation and 4 were re-operated. Before surgery, all the cases underwent biopsy or the original pathological results were confirmed to be soft tissue sarcoma. Metastatic work up was done with CT examination. MRI was performed to evaluate the primary tumor site and was used for preoperative plan of resection to determine the scope of surgical resection and to determine the

method of repair of soft tissue defect.

Surgical methods

Tumor resection:

Extensive tumor resection was performed in all cases, that is, the resection was carried out in the healthy soft tissue outside the tumor area, with near about 3 cm margin from the edge of the tumor, combined with the compartmental anatomical excision to ensure the adequate margin. Post-operative pathological examination confirmed that the margin was negative.

Repair and reconstruction of soft tissue defects.

In STS of the Shoulder and upper arm in 3 cases: the local skin flap was transferred to cover the exposed bone, and then free skin grafting was performed in the rotational defect. In 8 cases with tumor around the hip joint, 5 had local muscle flap transferred to cover the nerves, blood vessels or bone exposure, and then free skin graft; 3 cases had greater trochanter bone exposure and lateral thigh soft tissue defect, they were repaired using anterolateral thigh perforator skin flap plus split thickness skin grafting coverage. In 7 cases where tumors were around the knee joint: 3 cases were repaired with the medial head of gastrocnemius muscle combined with split thickness skin grafting; 4 cases were repaired with the posterior tibial artery perforator flap. In the 5 cases of calf STS, 3 cases were repaired with the posterior tibial artery perforator flap and 2 cases were repaired with sural nerve rotational flaps.

Evaluation of functional recovery

In the follow-up period from 8 to 60 months after surgery, the MSTS functional score was recorded at 3 months after surgery to evaluate the limb function. MSTS score > 20 was considered excellent, 10-20 was fair, and 0-9 was poor.

Results

After extensive resection of 23 cases of soft tissue sarcoma, various methods were used to repair soft tissue defects, and all skin grafts and flaps survived. After 8-60 months of follow-up and an average follow up of 39.69 months. 10(43.47%) cases died of tumor metastasis from 8 months to 23 months after surgery, among these 2 (8.70%)

cases underwent amputation because of tumor recurrence. Remaining 13 patients had no necrosis of the flap and limb function is good. The MSTS score recorded at 3 months after surgery of all patients were ranging from 7 to 28 points, with an average of 22.56 points; categorically speaking MSTS scores were poor in 2 cases, fair in 1 case and were excellent in 20 cases which confirms excellent and fair MSTS score of 91.30%. Four patients developed symptoms of neurological dysfunction after surgery, but all recovered within 3 months. Overall 5-year survival rate is 56.52%.

Example Cases

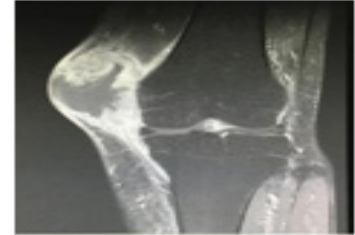
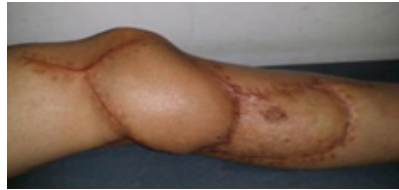
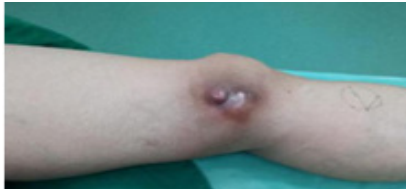
Figure 1: (1) 65 years old, female diagnosis: Undifferentiated Pleomorphic Sarcoma (UPS) of the left knee joint, underwent extensive tumor resection, and repair of soft tissue defect with posterior tibial artery perforator flap.

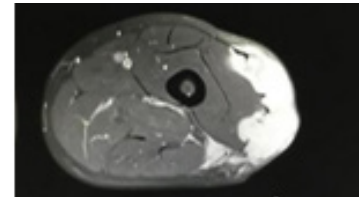
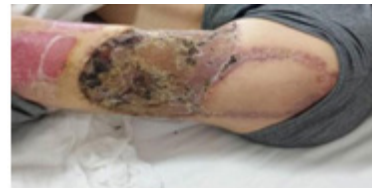
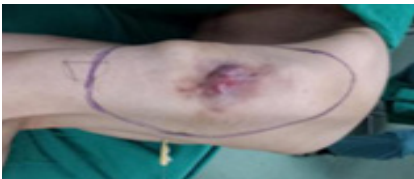
Figure 2: (2) 60 years old, male, diagnosis: Leiomyosarcoma of the left lateral thigh recurred after surgery, extensive tumor resection was performed, the anterolateral thigh perforator flap was used to repair the soft tissue defect at the greater tuberosity, and free thigh skin grafting.

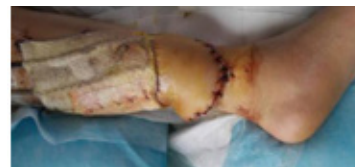
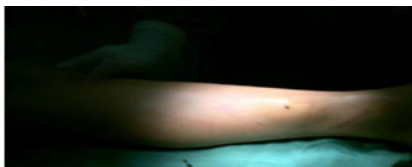
Figure 3: A 13-year-old male child, diagnosis: dermatofibrosarcoma protuberans (DFSP) of the distal right leg, underwent extensive tumor resection, and repair of soft tissue defects with sural nerve nutrition flap.

Discussion

The principle of surgical treatment of soft tissue sarcoma is the margin negative resection of tumor⁸. Therefore, the surgical treatment of soft tissue sarcoma requires complete removal of tumor along with adequate tissue margins, but the problem that follows is a large soft tissue defect and cavities resection site. Repair of the soft tissue defect and residual cavity are the prerequisite of the healing of the wound for soft tissue reconstruction⁹⁻¹⁰. However, sometimes it is difficult to repair soft tissue defects after tumor resection. Before the flap transplantation

is immature, patients with this type of soft tissue sarcoma can only choose to undergo amputation. For the repair of soft tissues, the goal should be to repair defects, rebuild function, and improve appearance¹¹. If these goals are not achieved, the harm of repairing the soft tissue to save limbs outweighs the advantages, and it is better to perform amputation. In recent years, with the improvement of surgical technique, the continuous research on the concept of sarcoma and anatomical barriers and the development of imaging technology, patients can be pre-

operatively staged, and meticulous surgical plans can be formulated. More and more patients with soft tissue sarcoma get the chance of safe limb salvage surgery. Distant metastasis is not a contraindication to limb salvage surgery. Plannings of repair of defect site and size of the tumor resection were done before surgery and the appropriate flap for reconstruction. At the same time, if the tumor is adequately resected, synchronous soft tissue reconstruction can be done; for those with insufficient tumor resection margins, delaying soft tissue reconstruction should be recommended¹². Due to the aggressive nature of soft tissue sarcoma, it often violates outside of the anatomical compartment. Even due to some inappropriate surgical treatments, extensive or radical resection of soft tissue sarcoma of the limbs will form soft tissue defects with exposed joints or bone tissue. Because there is no soft tissue bed covering, there isn't a simple method to repair the wound, then a flap transplantation is required to fill the large soft tissue defect caused by tumor resection.

This group of cases used different methods to repair soft tissue defects after resection of soft tissue sarcoma, and all achieved satisfactory clinical results. The 5-year survival rate(56.52%) did not drop significantly, compared with other studies¹³. Our experience is that where a simple and reliable method can be used to repair soft tissue defects, we should try to apply simple and reliable methods to repair soft tissue defects (such as vascularized muscle flaps or musculocutaneous flaps). Some patients with soft tissue sarcoma require radiotherapy and chemotherapy, and non-healing wounds will delay the treatment and even lead to failure of limb salvage treatment. In other areas that are difficult to cover with muscle flaps or musculocutaneous flaps, such as around the knee joint or distal calf, we choose to cover with vascular perforator flaps or sural nerve nutrition flaps. Vascular perforator flaps are skin flaps that only use skin perforating vessels to supply blood. Because muscles and well-known blood vessels are not cut, they have little impact on limb function, and have the advantages of excellent wound healing and rich blood supply. Currently widely used perforator flaps include anterolateral femoral flap, radial artery perforator

flap, ulnar artery perforator flap, peroneal artery perforator flap and posterior tibial artery perforator flap. Among them, the posterior tibial artery and peroneal artery perforator flaps are good choices for repairing soft tissue defects in the distal leg and ankle¹⁴⁻¹⁶.

Bias or shortcomings of this article: According to previous literature reports¹⁷⁻²⁰ and the author's experience, the treatment of soft tissue sarcoma did not effectively solve the problem of postoperative soft tissue defects in the early years, and amputation was the main method. In case of flap transplantation, due to the immature flap transplantation technology, most of the local flap necrosis occurred and eventually ended in salvage amputation. As a result, the previous data is missing, and this article lacks a convincing control group. At the same time, in this retrospective study, due to the limited number of disease sources in the region, the sample size is small and does not have authoritative representativeness. Extensive tumor resection combined with skin flap transplantation for limb salvage treatment of soft tissue sarcoma still needs further case collection and research.

Conclusion

In the treatment of soft tissue sarcoma of limbs, If tumor resection will lead to a large soft tissue defect, extensive tumor resection combined with skin flap transplantation can be considered for limb salvage in stead of amputation. The treatment results are good, and it is a feasible and reliable method for the treatment of soft tissue sarcoma.

References

1. Maretty-Nielsen K, Aggerholm-Pedersen N, Safwat A, et al. Prognostic factors for local recurrence and mortality in adult soft tissue sarcoma of the extremities and trunk wall: a cohort study of 922 consecutive patients. *Acta orthopaedica*.2014, 85(3): 323-332.
2. Ng VY, Scharschmidt T J, Mayerson J L, et al. Incidence and survival in sarcoma in the United States: a focus on musculoskeletal lesions. *Anticancer research*.2013, 33(6): 2597-2604.

3. Maretty-Nielsen K, Aggerholm-Pedersen N, Keller J, et al. Relative mortality in soft tissue sarcoma patients: a Danish population-based cohort study. *BMC cancer*.2014, 14: 682.
4. Sánchez Medina MT, Fernández-Palacios J, et al. Soft tissue sarcoma in the thigh and groin. Reconstruction using vertical rectus abdominis myocutaneous flap. *Ci Esp (English Edition)*.2014, 10(92): 693-694.
5. Misra A, Mistry N, Grimer R, et al. The management of soft tissue sarcoma. *Journal of Plastic, Reconstructive & Aesthetic Surgery*.2009, 62(2): 161-174.
6. Consenso del Grupo Espaol de Investigacion en sarcomas(GEIS). *Oncologia*.2006, 29: 238-244.
7. Enneking W F, Dunham W, Gebhardt M C, et al. A system for the functional evaluation of reconstructive procedures after surgical treatment of tumors of the musculoskeletal system. *Clinical orthopaedics and related research*.1993 (286): 241-246.
8. Xu Jian-qiang, Zhang Wei-bin, Wan Rong, et al. Gastrocnemius muscle transfer for soft-tissue coverage and extensor mechanism reconstruction for limb-sparing resection of the proximal tibia. *Journal of Clinical Rehabilitative Tissue Engineering Research*.2010, 14(17): 3050-3053.
9. Ji Tao, Wang Tian-bing, Guo Wei. SOFT TISSUE RECONSTRUCTION AFTER RESECTION OF MUSCULOSKELETAL TUMORS. *Chinese Journal of Reparative and Reconstructive Surgery*.2012, 26(8): 950.
10. López J F, Hietanen K E, Kaartinen I S, et al. Primary flap reconstruction of tissue defects after sarcoma surgery enables curative treatment with acceptable functional results: a 7-year review. *BMC surgery*.2015, 15(1): 1.
11. Davidge K M, Wunder J, Tomlinson G, et al. Function and health status outcomes following soft tissue reconstruction for limb preservation in extremity soft tissue sarcoma. *Annals of surgical oncology*.2010, 17(4): 1052-1062.
12. Morii T, Mochizuki K, Takushima A, et al. Soft tissue reconstruction using vascularized tissue transplantation following resection of musculoskeletal sarcoma: evaluation of oncologic and functional outcomes in 55 cases. *Annals of plastic surgery*.2009, 62(3): 252-257.
13. Pisters PW, Leung DH, Woodruff J, et al. Analysis of prognostic factors in 1,041 patients with localized soft tissue sarcomas of the extremities. *J Clin Oncol*.1996,14(5) 1679-1689.
14. Shantakumar S, Connelly-Frost A, Kobayashi M G, et al. Older soft tissue sarcoma patients experience increased rates of venous thromboembolic events: a retrospective cohort study of SEER-Medicare data. *Clinical sarcoma research*.2015, 5(1): 1.
15. Kang S, Kim H S, Kim W, et al. Comorbidity is Independently Associated with Poor Outcome in Extremity Soft Tissue Sarcoma. *Clinics in orthopedic surgery*.2015,7(1): 120-130.
16. Hanasilo C E H, Casadei M S, Auletta L, et al. Comparative study of planned and unplanned excisions for the treatment of soft tissue sarcoma of the extremities. *Clinics*.2014, 69(9): 579-584.
17. Doyle L A. Sarcoma classification: an update based on the 2013 World Health Organization Classification of Tumors of Soft Tissue and Bone. *Cancer*.2014, 120(12): 1763-1774.
18. Youn P, Milano M T, Constine L S, et al. Long-term cause-specific mortality in survivors of adolescent and young adult bone and soft tissue sarcoma: A population-based study of 28,844 patients. *Cancer*.2014, 120(15): 2334-2342.
19. O'Donnell P W, Griffin A M, Eward W C, et al. The effect of the setting of a positive surgical margin in soft tissue sarcoma. *Cancer*.2014, 120(18): 2866-2875.
20. Grimer R J. On the effect of setting of a positive surgical margin in soft tissue sarcoma. *Cancer*.2014, 120(18): 2803-2805.