

## Case Report

## Carcinosarcoma of the Uterus: An Elusive Diagnosis

Anupama Bhattarai<sup>1</sup>, Jitendra Pariyar<sup>2</sup>, Sameer Neupane<sup>3</sup>, Srijana Koirala<sup>3</sup>, Pratit Pokhrel<sup>4</sup>, Simit Sapkota<sup>5</sup>, Subhas Pandit<sup>5</sup>

<sup>1</sup>Paropakar Maternity and Women's Hospital, National Academy of Medical Sciences, Kathmandu, Nepal.

<sup>2</sup>Gynecologic Oncology Unit, Civil Service Hospital, Kathmandu, Nepal.

<sup>3</sup>Department of Pathology, Civil Service Hospital, Kathmandu, Nepal.

<sup>4</sup>Department of Radiology, Civil Service Hospital, Kathmandu, Nepal.

<sup>5</sup>Oncology Unit, Civil Service Hospital, Kathmandu, Nepal.

### ABSTRACT

**Introduction:** Carcinosarcoma or Malignant Mixed Mullerian Tumor (MMMT) of the uterus is a rare malignant tumor comprising both carcinomatous and sarcomatous components. Worldwide it accounts for two to five percentages of all uterine malignancies. However, there is a paucity of reports in Nepalese literature.

**Case report:** A 62 years postmenopausal woman with diabetes and hypertension presented with urinary symptoms for two months and passage of fleshy mass per vagina for two days. Ultrasound was inconclusive, whereas, Magnetic Resonance Imaging (MRI) showed an endo-cervical mass. Pre-operative biopsy of the mass suggested leiomyosarcoma. Abdominal hysterectomy with bilateral salpingo-oophorectomy and pelvic and para-aortic lymphadenectomy was performed. Per-operatively, an atrophic uterus, a dimple in the fundus, and ballooning of the lower uterine segment and vagina were noted. The cut section showed an exophytic polypoidal mass with base in the fundus. Histopathology revealed Stage IA carcinosarcoma with aggressive mitotic figures. Immunohistochemistry confirmed the diagnosis of carcinosarcoma with a heterologous rhabdomyosarcomatous component. Adjuvant chemotherapy and radiation therapy was advised.

**Conclusion:** The preoperative diagnosis of carcinosarcoma or MMMT was difficult and might be missed on biopsy as well. Owing to its aggressive nature and higher rates of post-surgical recurrence, carcinosarcoma accounts for around one-fifth of deaths due to uterine malignancies. Surgery is the primary treatment modality, yet much study is needed before evidence-based adjuvant management for improving its outcome is established.

**Keywords:** Biphasic Tumor, Carcinosarcoma of Uterus, Malignant Mixed Mullerian Tumor.

### Introduction

Uterine malignancies constitute 7% of all female malignancies. Carcinosarcoma, also known as the Malignant Mixed Mullerian Tumor (MMMT) accounts for 2-5% of all uterine malignancies.<sup>1,2</sup>

During the embryogenesis, mullerian duct is formed from the invagination of coelomic epithelium lateral to the

mesonephros. The mullerian duct is comprised of both epithelial and mesenchymal cell types.<sup>3</sup> In the female, the duct gives rise to the fallopian tubes, uterus, cervix, and upper part of the vagina. Carcinosarcomas are rare but, highly aggressive and biphasic tumors with mixed epithelial and mesenchymal components have also been reported to occur in the vagina, cervix, and ovary.<sup>4,5,6</sup> However, Nepalese literature is sparse in its reporting.

### Correspondence

**Dr. Jitendra Pariyar**, Gynecologic Oncology Unit, Civil Service Hospital, Kathmandu, Nepal,  
jipariyar@yahoo.com

The preoperative diagnosis of uterine carcinosarcoma is often difficult. Patient characteristics and physical examination may provide a differential diagnosis. Magnetic Resonance Imaging as an imaging tool for both diagnostic accuracy and assessment of disease extent has been studied with varying results.<sup>7</sup> Histologically, diagnosis of carcinosarcoma depends on the demonstration of high-grade malignant epithelial and mesenchymal components typically with a sharp demarcation,<sup>8</sup> for which sample may not always be adequate preoperatively.

We herein report a case of heterologous carcinosarcoma diagnosed postoperatively with preoperative biopsy suggestive of leiomyosarcoma.

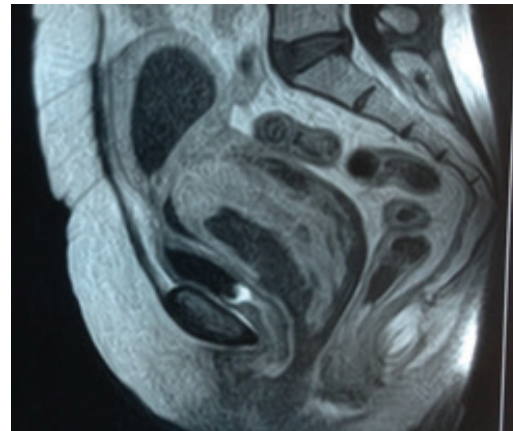
### Case Report

A 62-year-old para two woman, post-menopausal for fifteen years with type II diabetes mellitus under oral hypoglycemics, essential hypertension controlled on antihypertensive medication, and previous two caesarian sections, presented with complaint of urinary symptoms for four months and passage of painless fleshy mass per vagina for two days. She was a nonsmoker, non-alcoholic with no significant gynecological family history. She had no history of irradiation or hormonal drug therapy. Her vital signs were within normal limits. Pelvic examination revealed a fleshy exophytic mass protruding from the cervix and filling the vaginal canal. On blood investigations, her random blood glucose was 236 mg/dl, while the rest of the laboratory parameters were within the normal range.

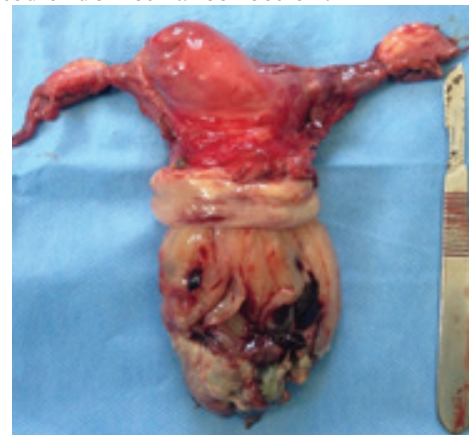Ultrasound showed a bulky uterus with the endometrial collection and enlarged cervix. MRI of the abdomen-pelvis reported a heterogeneously enhancing predominantly endocervical mass with involvement of the lower uterine cavity and upper half of the vagina with an associated endometrial collection. There was no gross involvement of bilateral parametria or significant pelvic lymph nodes. Differential diagnosis of cervical malignancy was reported (Figure 1). Examination under anesthesia was done for further assessment of the lesion, its relations with the vaginal wall, rectal mucosa, and parametria which were found to be free. Preoperative biopsy of the mass revealed mesenchymal neoplasm with morphology suggesting uterine leiomyosarcoma.

With primary curative intent, abdominal hysterectomy

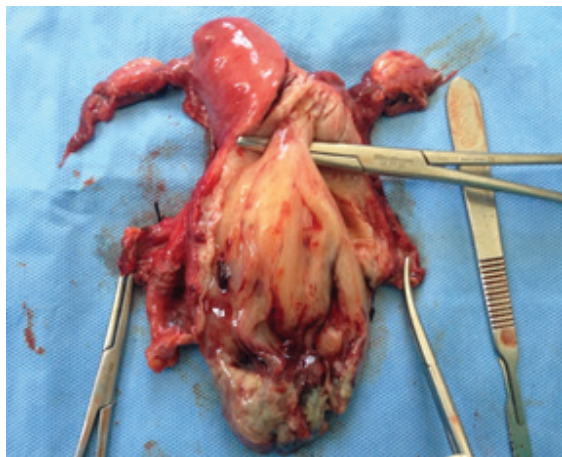
with bilateral pelvic lymph node and para-aortic lymph node dissection was performed. Intraoperatively, adhesion between the omentum and the anterior abdominal wall was noted. The urinary bladder was pulled up. The uterus was atrophic with dimpling at the fundus. The lower uterine segment and vagina were ballooned up. Bilateral ovaries and tubes were atrophic (Figure 2). All pelvic lymph nodes and para-aortic lymph nodes were < 1 cm. No gross evidence of tumor was seen in other abdominal and pelvic organs. The Cut Section of the uterus revealed a soft, fleshy, grayish-white to pale yellow tumor with hemorrhagic, cystic, and areas of necrosis occupying the lower uterine segment and upper vagina with a stalk of the tumor in the uterine fundus (Figure 3). The intraoperative period was uneventful with a blood loss of about 100 ml.



**Figure 1: MRI findings: Sagittal T1-weighted image heterogeneously enhancing predominantly endocervical mass with involvement of the lower uterine cavity and the upper half of the vagina with an associated endometrial collection.**



**Figure 2: Gross appearance: Polypoid fleshy tumor protruding from ballooned up cervix, with evident dimpling of the left portion of the uterine fundus.**



**Figure 3: Cut Section showing the fleshy tumor stalk arising from the uterine fundus.**

Postoperatively she was managed with glucose, potassium, and insulin infusion and switched to oral hypoglycemics from the second day with daily monitoring of blood glucose. Despite adequate glycemic control, there was primary surgical wound dehiscence, which was managed with intravenous antibiotics, daily dressing, and resuturing done on the 17<sup>th</sup> postoperative day. She was discharged on the 19<sup>th</sup> postoperative day with no further surgery-related complications.

The final histopathology reported a Carcinosarcoma with a differential diagnosis of Adenosarcoma. The tumor size was 9x5, 5x3cm. Section from the tumor showed proliferation of atypical cells in bundle, fascicles, and diffusely composed of epitheloid, elongated to bizarre cells with some dispersed glands that exhibited atypical epithelial lining. The tumor was limited to the uterus, with <50% myometrial invasion, 20 mitotic figures per 10 HPF, with no lymphovascular invasion. Lymph nodes were negative for metastasis. Bilateral ovaries and fallopian tubes along with the cervix, were free of disease. According to the 2009 International Federation of Gynecology and Obstetrics criteria of staging for endometrial carcinoma, she was designated to have a Stage IA disease. Further immunohistochemistry showed the tumor consisting of glands that stained positive for Cytokeratin and Epithelial Marker Antigen while the stroma stained positive for Vimentin, Desmin, Myogenin, and MyoD1. KI-67 was positive in 25% of tumor stroma and glands. A final diagnosis of carcinosarcoma with heterologous rhabdomyosarcomatous differentiation was made.

Post-operative adjuvant chemotherapy and radiation therapy was advised. She received two cycles of combined chemotherapy with carboplatin and paclitaxel and was switched to micronized paclitaxel (Nanoxel) with carboplatin to minimize the adverse effects. After six cycles of chemotherapy on a daycare basis, she underwent adjuvant radiation therapy both external beam radiation therapy and vaginal vault brachytherapy. She tolerated the treatment well with adverse effects of hair loss and occasional nausea.

### Discussion

Carcinosarcomas occur mainly in postmenopausal women with an average age of presentation at 62 years. These are often found in association with medical conditions such as diabetes, hypertension, and obesity. The other risk factors include nulliparity, exogenous estrogen exposure, and prolonged tamoxifen use. Seven to 37% of patients give a history of exposure to pelvic irradiation. The clinical presentation might be non-specific. A most frequent symptom is postmenopausal bleeding – seen in 80-90 % of cases. Uterine enlargement is present in 50-95% of cases. Fifty percent of cases show polypoid lesion protruding through the endocervical canal.<sup>9</sup> The symptom triad of pain, severe vaginal bleeding, the passage of necrotic tissue per vagina may be seen. Our case fit the clinical profile of 62 years para two, postmenopausal woman with diabetes and hypertension; had no history of irradiation or hormonal intake. She presented with a non-specific urinary symptom of on and off burning micturition and passage of fleshy mass per vagina. She also had growth protruding through the endocervical canal, distending the upper vagina and filling the cavity, though she did not have postmenopausal bleeding and the uterus was atrophic.

The preoperative diagnosis of Carcinosarcoma was very difficult. Owing to its biphasic histological characteristic, the preoperative biopsy is often elusive. As in our case, though the clinical picture arose a differential diagnosis of carcinosarcoma, the preoperative biopsy was suggestive of leiomyosarcoma. Pretreatment imaging, most commonly MRI is applicable for assessment of disease extent, while the definitive diagnosis is made postoperatively. Histologically, these biphasic tumors are composed of both carcinomatous and sarcomatous elements which may be native to the uterus (homologous) or non-native composed of tissue such as cartilage, bone



or striated muscle (heterologous).<sup>3</sup>

Immunohistochemistry contributes to the identification of the nature of the disease on a biochemical level and newer research on targeted therapies could be based upon the findings as that of hormonal receptors in the tumor. Immunohistochemistry in our case consisted of tumor glands that stained positive for Myogenin and MyoD1 confirming heterologous rhabdomyosarcomatous differentiation.<sup>10</sup>

These aggressive tumors have a high recurrence rate with recurrences in over half of the patients following primary treatment with surgery and adjuvant therapy, even in early-stage disease. Recurrence rate has been reported between 47-64% and most occur within a year of primary treatment.<sup>3</sup> The disease prognosis is poor with a survival rate at 5 years to be 35%. Heterologous sarcomatous components and high mitotic figures (20/10 HPF) might favor an adverse prognosis, however, the involvement of  $< \frac{1}{2}$  of the myometrium with an absence of lymphovascular invasion might confer a better prognosis in our case.

Carcinosarcomas have presented a much therapeutic challenge. While surgery is the primary treatment, adjuvant therapy in the form of chemotherapy and/or radiotherapy is advised. However, they have not shown to prolong survival. Recently, many targeted therapies at molecular levels are being studied.<sup>10</sup> Our case is disease free for 30 months now and will be under surveillance.

## Conclusion

Carcinosarcoma are rare and aggressive tumors that are difficult to diagnose preoperatively. Due to the rarity of the tumor, the sample size is restricted for case study purpose. More articles, case series, and reports should be published regarding the disease. Surgery is the primary treatment modality as offered in our case. Our case has benefitted from adjuvant chemotherapy and radiation therapy being disease-free to date. However, a larger-scale study is needed regarding adjuvant management to establish the improved treatment outcome.

## References

1. McConechy MK, Hoang LN, Chui MH, Senz J, Yang W, Rozenberg N, et al. In-depth molecular profiling of the biphasic components of uterine carcinosarcomas. *J Pathol: Clin Res.* 2015;1:173–85. DOI:10.1002/cjp2.18
2. Silverberg SG, Major FJ, Blessing JA, Fetter B, Askin FB, Liao SY, et al. Carcinosarcoma (malignant mixed mesodermal tumor) of the uterus. A Gynecologic Oncology Group pathologic study of 203 cases. *Int J Gynecol Pathol.* 1990;9:1-19. DOI:10.1097/00004347-199001000-00001
3. Kanthan R, Senger J-L. Uterine Carcinosarcomas (Malignant Mixed Mullerian Tumors): A Review with Special Emphasis on the Controversies in Management. *Obstetrics and gynecology International.* 2011;1-13. DOI:10.1155/2011/470795
4. Ahuja A, Safaya R, Prakash G, Kumar L, Shukla NK. Primary mixed mullerian tumor of the vagina—a case report with review of the literature. *Pathology Research and Practice.* 2011;207(4):253-5. DOI:10.1016/j.prp.2010.10.002
5. Sharma NK, Sorosky JI, Bender D, Fletcher MS, Sood AK. Malignant mixed mullerian tumor (MMMT) of the cervix. *Gynecologic Oncology.* 2005;97(2):442-5. DOI:10.1016/j.ygyno.2005.01.022
6. Duman BB, Kara IO, Gunaldi M, Ercolak V. Malignant mixed Mullerian tumor of the ovary with two cases and review of the literature. *Archives of Gynecology and Obstetrics.* 2011;283(6):1363-8. DOI:10.1007/s00404-011-1845-6
7. Huang Y-T, Chang C-B, Yeh C-J, Lin G, Huang H-J, Wang C-C, et al. Diagnostic accuracy of 3.0T diffusion-weighted MRI for patients with uterine carcinosarcoma: Assessment of tumor extent and lymphatic metastasis. *JMRI.* 2018. DOI:10.1002/jmri.25981
8. McCluggage, Glenn W. A practical approach to the diagnosis of mixed epithelial and mesenchymal tumours of the uterus. *Journal of Modern Pathology.* 2016;29:S78–91. <https://doi.org/10.1038/modpathol.2015.137>
9. Berek JS, editors. *Berek and Novak's Gynecology.* 15th ed. Philadelphia: Lippincott Williams and Wilkins, 2014. Chapter 35, Uterine Cancer; p.1291-93.
10. Vitale SG, Laganà AS, Capriglione S, Angioli R, La Rosa VL, Lopez S, et al. Target Therapies for Uterine Carcinosarcomas: Current Evidence and Future Perspectives. *Int J Mol Sci.* 2017;18(5):1100. DOI:10.3390/ijms18051100