

## Original Article

**<sup>18</sup>F-FDG-PET/CT for Evaluation of treatment response in high grade lymphoma**Yadav Ajay Kumar<sup>1</sup>, Kumar Rakesh<sup>2</sup>, Malhotra Arun<sup>2</sup>, Sharma Atul<sup>2</sup>

1. Dept. of Radiodiagnosis and nuclear medicine, BP Koirala Memorial Cancer Hospital.

2. Department of Nuclear Medicine, Department of Oncology, All India Institute of Medical Sciences, New Delhi, India

**ABSTRACT**

<sup>18</sup>F-FDG PET is highly sensitive and specific for evaluation of the treatment response of high-grade lymphomas. The molecular information provided by <sup>18</sup>F-FDG-PET identifies the functional content of anatomic finding and helps to categorize their nature as malignant or benign. On the other hand, the CT data obtained in the same setting provides anatomical localization of the <sup>18</sup>F-FDG-PET data while also improving the FDG-PET image quality as it is utilized for attenuation correction. Previously, most of the studies were done on this topic by using <sup>18</sup>F-FDG-PET alone. Present study was planning to assess the role of <sup>18</sup>F-FDG-PET/CT in evaluation of treatment response in patient of HD and NHL. Results showed that 43 patients out of 52 showed no pathologic FDG uptakes, whereas 9 showed persistent uptakes. Among the 43 patients who had negative PET scans, only three relapsed, whereas among the 9 patients who had persistent abnormal <sup>18</sup>F-FDG uptakes on post therapy PET/CT scans, two recovered. The sensitivity, specificity, positive and negative predictive values and accuracy of post therapy PET/CT scan was 70%, 95%, 78%, 93%, and 90% respectively.

**Keywords:** Positron Emission Tomography, Computed Tomography, NonHodgkin's Lymphoma, Hodgkin's Lymphoma, <sup>18</sup>F-Fluorodeoxyglucose

**INTRODUCTION**

The term lymphoma means variety of cancers that affect the lymphatic system. Lymphomas tend to form solid tumors in the body and are often felt as a lump that can occur almost anywhere in the body. There are two major types of lymphomas i.e. Hodgkin's disease and Non-Hodgkin's lymphoma.

NHL is a large group of cancers of the immune system. NHL can occur at any age and are often marked by enlarged lymph nodes, fever, and weight loss. There are many different types of NHL, which can be divided into aggressive (fast-growing) and indolent (slow-growing) types and can be classified as either B-cell or T-cell NHL. B-cell NHLs include Burkitt lymphoma, diffuse large B-cell lymphoma, follicular lymphoma, immunoblastic large cell lymphoma, precursor B-lymphoblastic lymphoma, and mantle cell lymphoma. T-cell NHLs include mycosis fungoides, anaplastic large cell lymphoma, and precursor T-lymphoblastic lymphoma. Lymphomas related to lymphoproliferative disorders following bone marrow or stem cell transplantation are usually B-cell NHLs. In general, the risk factors for

NHL include weak immune system, certain infections i.e. human immunodeficiency virus (HIV), Epstein-Barr virus (EBV), Helicobacter pylori: H. pylori (bacteria), Human T-cell leukemia/lymphoma virus (HTLV-1), and Hepatitis C virus, and age more than 60. Most often, these symptoms are not due to cancer. Infections or other health problems may also cause these symptoms. NHL can cause many symptoms i.e. swollen, painless lymph nodes in the neck, armpits, or groin, unexplained weight loss, fever, soaking night sweats, coughing, trouble breathing, weakness, pain, swelling, a feeling of fullness in the abdomen.<sup>1</sup>

The stage is based on where lymphoma cells are found (in the lymph nodes or in other organs or tissues). The stage also depends on how many areas of immune system are affected. (Fig 1)

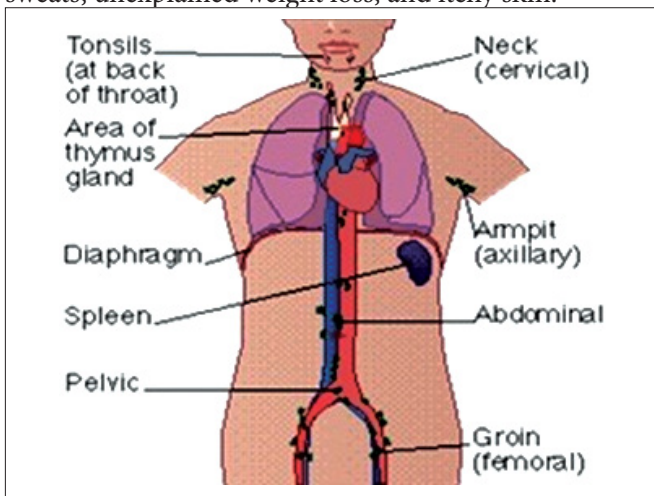
The treatment option for NHL patients, depend upon a variety of factors including the grade of the lymphoma (low, intermediate, or high); the stage or extent of spread of the disease, the areas of the body affected by the lymphoma, and the general health of the patient. In general, the treatment options range from "watchful

*Correspondence*

**A K Yadav**, Dept. of Radiodiagnosis and nuclear medicine, BP Koirala Memorial Cancer Hospital, [ajay\\_bpkmch@hotmail.com](mailto:ajay_bpkmch@hotmail.com)

waiting” in the earliest stage of the disease to high-dose chemotherapy with stem cell transplantation for patients with aggressive NHL, who fail to respond to standard treatment. A variety of new treatments are also currently being investigated.<sup>1</sup>

In HD, cells in the lymphatic system become abnormal. They divide too rapidly and grow without any order or control. Because lymphatic tissue is present in many parts of the body, HD can start almost anywhere. HD may occur in a single lymph node, a group of lymph nodes, or, sometimes, in other parts of the lymphatic system such as the bone marrow and spleen. HD is marked by the presence of a type of cell called the Reed-Sternberg cell. The two major types of Hodgkin's lymphoma are classical Hodgkin lymphoma and nodular lymphocyte-predominant Hodgkin lymphoma. Symptoms include the painless enlargement of lymph nodes, spleen, or other immune tissue. Other symptoms include fever, weight loss, fatigue, or night sweats. The risk factors associated with this disease are Age/Sex - Hodgkin's disease occurs most often in people between 15 and 34 and in people over the age of 55. It is more common in men than in women, Family History, and Viruses -- Epstein-Barr virus is an infectious agent that may be associated with an increased chance of getting Hodgkin's disease. Symptoms of Hodgkin's disease may include painless swelling in the lymph nodes in the neck, underarm, or groin, unexplained recurrent fever, night sweats, unexplained weight loss, and itchy skin.



*Figure 1. Staging of Lymphoma, (Cancer Research UK, What's New Clinical Trials Donate About Access Keys, NHS Information Partners, Last updated 06 September 2007)*

Treatment for HD depends on the stage of the disease, the size of the enlarged lymph nodes, which symptoms are present, the age and general health of the patient, and other factors. HD is usually treated with radiation therapy or chemotherapy. The doctors may decide to use one treatment method or a combination of methods. A variety of new treatments are also currently being investigated. Proper management of patients with NHL and HD depend upon correct staging and treatment. Correct staging is based on physical examination, complete blood counts, erythrocyte sedimentation rate (ESR) and biochemistry levels and FNAC, lymph node biopsy, bone marrow biopsy findings, and various diagnostic imaging modalities.<sup>2</sup>

Previously, Computed tomography (CT) was the principal staging tool for patients with lymphoma.<sup>3</sup> It is readily available, easy to perform, reliable and reproducible and there is evidence for its diagnostic and therapeutic impact in large series of patients. However, this imaging modality also has several limitations since interpretation of nodal involvement by CT is based on anatomic criteria of the size and shape. Early involvement of lymph nodes is not always associated with detectable anatomic changes and thus may be overlooked. On the other hand, benign lymph nodes enlargement as encounter in association with reactive changes may be a cause for false-positive interpretation. Furthermore, it is often impossible to reliably distinguish lymphoma lesions from benign CT abnormalities. Moreover, extra-nodal sites of lymphoma in the liver, skin and skeleton are often notoriously difficult to assess by CT alone. Therefore, we need a test, which not only provide structural detail of the disease process but also provide metabolic status of the disease. It has been suggested for some time now, that complementary functional and anatomical imaging allows for improved diagnostic and, subsequently, to better patient care in clinical oncology.

<sup>18</sup>F-fluorodeoxyglucose positron emission tomography (<sup>18</sup>F-FDG-PET), a functional imaging modality used for staging and monitoring response to treatment of a variety of cancer and has demonstrated a higher sensitivity and specificity than conventional anatomical imaging. <sup>18</sup>F-FDG-PET has had a major impact on the staging and management of lymphoma, resulting in alterations of the clinical stage and therapy in a substantial number of patients.<sup>4,5</sup> <sup>18</sup>F-FDG-PET is a functional modality often



requiring correction with anatomical imaging modalities so as to localize the detected lesion more accurately.

Zhao et al studied to assess the value of hybrid PET/CT with  $^{18}\text{F}$ -FDG after 3-4 cycles of chemotherapy for early evaluation of response to therapy and prediction of progression-free survival (PFS) in NHL. They concluded that early interim  $^{18}\text{F}$ -FDG imaging is an excellent and independent predictor of PFS in NHL. An early assessment of chemotherapy response with  $^{18}\text{F}$ -FDG scans may provide useful information for selection of patients for alternative therapeutic strategies.<sup>6</sup>

A literature review by Gustav *et al* demonstrated that PET/CT is a new diagnostic imaging modality, which proves that adding PET and CT is not merely additive, but highly synergistic. While PET provides high sensitivity for lesion detection, CT provides the anatomic backdrop, which frequently is important in order to make a specific diagnosis. CT can, however, also add sensitivity to PET, as certain lesions such as small clearly pathological lung nodules may not at all be visualized on PET alone; and PET clearly adds specificity to CT because, e.g., indeterminate lymph nodes seen on CT can often be diagnosed unequivocally as benign or malignant, using PET information. Furthermore, attenuation correction of PET data, which is needed for best PET image quality, can also be obtained using the same CT data. Hence, PET/CT also provides a very fast solution for obtaining attenuation images.<sup>7</sup>

So, PET/CT systems, which enable acquisition of PET and CT data at the same setting without changing the patients' positioning, have been introduced into clinical practice. The molecular information proved by  $^{18}\text{F}$ -FDG-PET identifies the functional content of anatomic finding and helps to categorize their nature as malignant or benign. On the other hand, the CT data obtained in the same setting provides anatomical localized of the  $^{18}\text{F}$ -FDG-PET data while also improving the  $^{18}\text{F}$ -FDG-PET image quality as it is utilized for attenuation correction. Thus, PET/CT offers several advantages including shorter image acquisition time, improved lesion localization and identification and more accurate tumor staging.

Nowadays, PET/MRI is a principle imaging tool on experiments for oncology. Heacock et al studied to assess patency of PET/MRI for the evaluation of patients with lymphoma. They found similar results of PET/MRI as

PET/CT (8). There were several studies done with PET/MRI on oncology including lymphoma and results were also acceptable (9-12). But we know that there are several limitations with MRI which still make PET/CT in choice (13).

Therefore, this study was planned to assess the role of fused  $^{18}\text{F}$ -FDG PET/CT in evaluation of treatment response in patients of HD and NHL.

## PATIENTS AND METHODS

### Place of study

These studies were conducted at Department of Nuclear Medicine, All India Institute of Medical Sciences, New Delhi, India in the collaboration with Department of Medical Oncology, All India Institute of Medical Sciences, and New Delhi, India.

### Study Population

A total 52 cases of lymphoma including both cases of Hodgkin's disease (HD) and Non-Hodgkin's lymphoma (NHL) were enrolled for study. In which total cases of Hodgkin's disease (HD) were 19 patients and Non-Hodgkin's lymphoma (NHL) were 33 patients. All patients were undergoing complete physical examination, comprising complete blood counts, biochemistry levels and FNAC/Biopsy before enrolling them in this study.

**Inclusion Criteria** - All patients who were known cases of Hodgkin's disease (HD) and Non-Hodgkin's lymphoma (NHL) and had not received any treatment in past

**Exclusion Criteria** - Patient refusing to give written informed consent, Pregnancy and lactation, uncontrolled diabetics

### PET/CT DATA ACQUISITION PROTOCOL

PET/CT scans were taken on the dedicated PET/CT scanner present in our Department of Nuclear Medicine, All India Institute of Medical Sciences i.e. SIEMENS, BIOGRAPH 64). It is made up of LSO (Lutetium oxyorthosilicate,  $\text{Lu}_2\text{SiO}_5:\text{Ce}$ ) detectors with attenuation coefficient  $0.89\text{ cm}^{-1}$ , photo fraction 30%, decay constant 40ns & energy resolution at 511 KeV (%FWHM) is 10 with spatial resolution of 6mm. After fasting for at least 4 hrs, verifying the serum glucose level (that should be below 140 mg/dl) and with patients in resting state, in quiet room, a dose of 10-15 mCi of  $^{18}\text{F}$ -FDG was injected intravenously depending on the age and weight of the

patient. After 45-60 minute uptake period, patients were placed into the scanner. In the PET/CT system, CT scan acquisition was performed on spiral dual slice CT with a slice thickness of 4mm and a pitch of 1. Images were acquired using a matrix of 512 x 512 pixels and pixel size of about 1mm. After transmission scan, 3 D PET acquisition was taken for 3-5 minutes per bed position for one-two bed position. PET data were acquired using matrix of 128 x 128 pixels with a slice thickness of 1.5mm. CT based attenuation correction of the emission images were employed. PET images were reconstructed by iterative method ordered subset expectation maximization (2 iterations and 8 subsets) with a filter of 5mm. Initial CT acquisition was done without oral or intravenous contrast injection; followed by PET scan. After completing the CT, the table is moved toward the field of view of the PET, and PET acquisition of the same axial range was started with the patient in the same position on the table.

## PROCESSING PROTOCOL

The CT images were acquired and reconstructed using optimized parameters for attenuation correction. Data obtained from the CT acquisition were used for low noise attenuation correction of PET emission data and for fusion of attenuation corrected PET images with the corresponding CT images. After Completion of PET acquisition, the reconstructed attenuation corrected PET images, CT images and fused PET/CT images of matching pairs of PET and CT images were available for review in axial, coronal, and sagittal plans and in maximum intensity projections, three dimensional cine mode.

After image reconstruction, a region of interest (ROI) will be carefully drawn around the site of the abdominal FDG uptake on lesions in the consequent 4-6 PET/CT scan slices. The slice with a maximal FDG uptake in the ROI will be chosen for quantitative measurement of metabolic activity of tracer (SUV).

## DATA INTERPRETATION

Two experienced Nuclear Medicine physicians were evaluate the scan findings independently and they were blinded to the structural imaging findings and clinical findings. PET images were looked for area of increased

radiotracer uptake. Corresponding area in the CT images and fused PET/CT images were corroborated.

Repeat PET/CT was done 4-6 weeks after completion of chemotherapy. Baseline FDG PET/CT study were compare (qualitatively and semi-quantitatively) with follow up PET/CT scans for evaluation of treatment response. Treatment response was determined by decrease in size, FDG uptake, and change in SUV. PET response was determined by decrease in size, FDG uptake, and change in SUV. PET/CT response was correlated with clinical improvement.

### PET/CT criteria for treatment response

*Complete Response (CR): Disappearance of all target lesions.*

*Partial Response (PR):- At least a 50% decrease in SUV.*

*Progressive Disease (PD):- At least a 20% increase in SUV*

*Stable Disease (SD):- No change in SUV and size of the lesion/s*

### Data Analysis

The quantitative values are expressed as mean $\pm$ SD. For quantitative data, frequency distributions have been reported. The various descriptive statistics such as mean, SD, range are used to summarize the baseline demographic and clinic profile of all patients. The results of <sup>18</sup>F-FDG-PET/CT were comparing with the result of CT and clinical outcome; the presence of relapse was determined on the basis of positive biopsy results or clinical follow up data. To see the association of various qualitative data with outcome chi-square test was used.

To evaluate the performance of one test over the other, various diagnostic tests, parameters like false negative rate, false positive rate, true negative rate, true positive rate, true negative rate, sensitivity, specificity, accuracy, positive predictive value, negative predictive value and prevalence had been calculated (Table-1). Significant level was considered as 5 %. Equations to calculate parameters are given below.

(Where, PPV-Positive Predictive Value, NPV-Positive Predictive Value, Sp.-Specificity, Ac-Accuracy, TSP – Total Study Population, Sn. – Sensitivity)

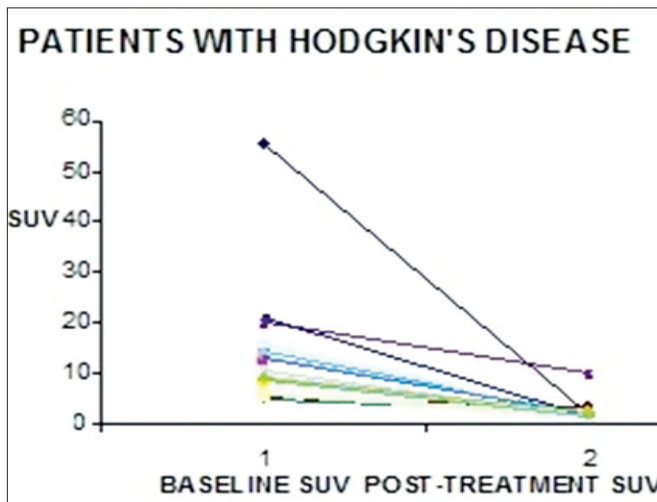


**Table-1 Showing how to categorize the PET/CT reports**

Total Study Population	Positive Biopsy / Follow up	Normal Biopsy /Follow up
Positive PET/CT Report	True Positive(TP)	False positive(FP)
Negative PET/CT Report	False Negative(FN)	True Negative(TN)

**RESULTS**

We included a total 52 patients (25male and 27female) in this study with FNAC/Biopsy proven high grade HD and NHL. Total number of patients of HD is 19 and NHL is 33. In this study, we analyzed all the 52 patients together in one group.



*Figure 2. Showing Baseline Vs Post-treatment SUV of HD Patients*

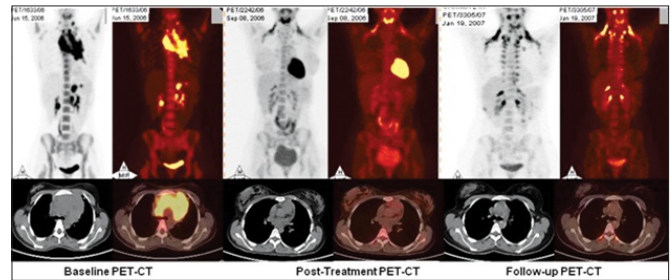
**Demographic Profile**

As a whole (n = 52) the mean age of the patients was 44.5 ± 31.5 yrs i.e. range 13-76 years. The mean age of the patients of Hodgkin’s disease (HD) was 36 ± 20 yrs i.e. range 16-56 years. The mean age of the patients of Non-Hodgkin’s lymphoma (NHL) was 44.9 ± 31.5 years i.e. 13-76 years. There was no significant difference mean age and age range in two groups. Characteristics of all patients are given in table 2.

**Baseline PET/CT results:**

In Hodgkin’s group, most of the patients were of classical HD and nodular lymphocyte-predominant HD was seen in lesser. Maximum SUV among HD patients was 55.5 with a range 55.5-4.7. Most of the patients of HD had

active disease in cervical, axillary and mediastinal L/Ns. In 10 patients of HD, active disease in L/Ns was noted above and below the diaphragm. In 9 patients there was organ involvement i.e. bone marrow, bone, spleen and liver. Detail findings are given in table 3.



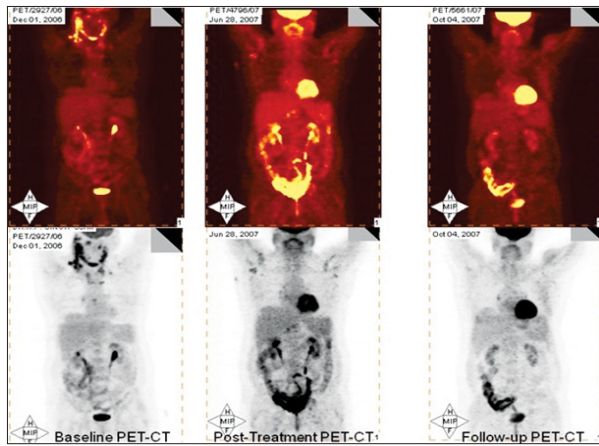
*Figure 2. FDG PET-CT of 21/F patient with HD showing residual normal in post-chemo PET-CT, which also normal in follow-up PET-CT (Responder)*

In NHL group, most of the patients were diffuse large B-Cell lymphoma and follicular NHL. Maximum SUV among NHL patients was 42.7 with the range 42.7-3.1. Approximately 75% of patients had active disease in L/ Ns of both above and below the diaphragm in cervical, axillary, mediastinal, retroperitoneal and pelvic L/Ns. Data showed that more than 50% patients had organs involvement i.e. bone, bone marrow, spleen and liver. Detail findings are given in table 4.

**Table-2 Characteristics of All Patients**

Characteristics	Values
Total Patients	52
Male	25(48.07%)
Female	27(51.92%)
HD	19(36.52%)
NHL	33(63.46%)
Age(Yrs)	
Range	13-76
Mean	44.84±0.31
Staging(NHL)	
Stage I	00
Stage II	10
Stage III	08
Stage IV	16

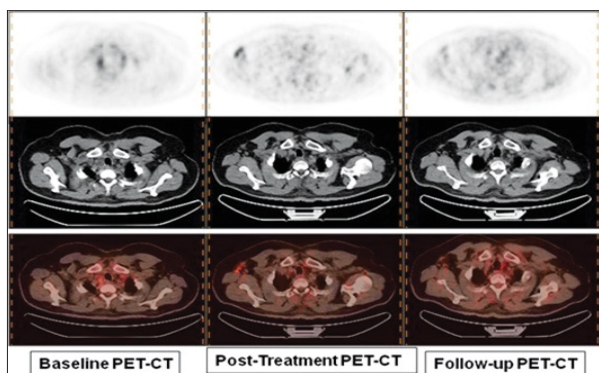
Staging(HD)	
Stage I	00
Stage II	09
Stage III	04
Stage IV	06



**Figure 4A:** FDG PET-CT of 58/M patient with HD showing residual active disease in axilla in post-chemo PET-CT, which was normal in follow-up PET-CT (False Positive)

**Post Chemotherapy PET/CT results**

Repeat <sup>18</sup>F-FDG PET/CT were done 4-6 weeks after completion of chemotherapy. Baseline FDG PET/CT study were compare (qualitatively and semi-quantitatively) with Post-treatment PET/CT scans for evaluation of treatment response. Treatment response was determined by decrease in size, FDG uptake, and change in SUV. PET response was determined by decrease in size, FDG uptake, and change in SUV. PET/CT response was correlated with clinical improvement.

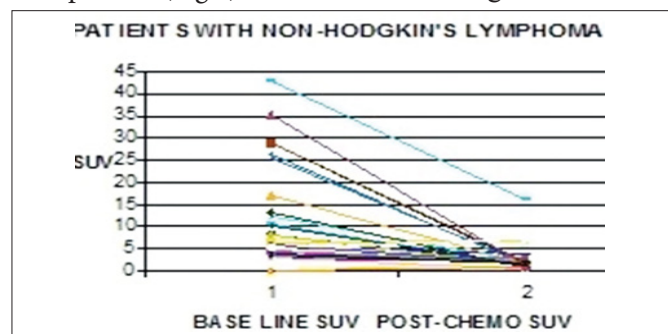


**Figure 4B:** Axial section of FDG PET-CT of 58/M patient with HD showing residual active disease inn axilla in post-chemo PET-CT, which was normal in follow-up PET-CT (False Positive)

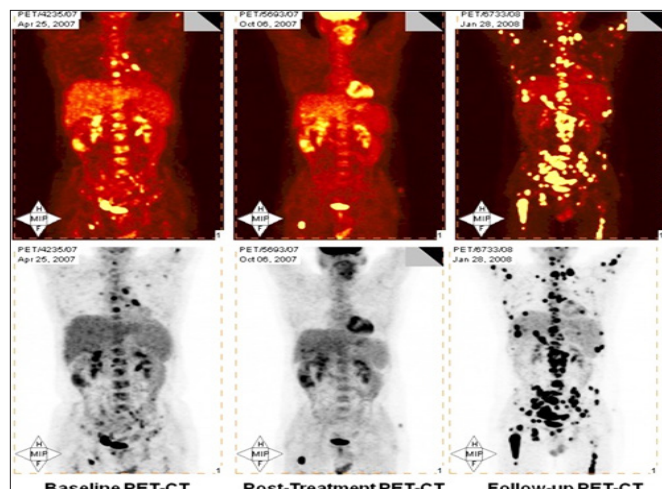
Ten out of 19 patients in HD group received 6 cycles of ABVD chemotherapy while 9 patients received CHOP and BEACOPP. Only 2 patients had received more than 6 cycles chemotherapy. 5 patients had received both chemotherapy and radiotherapy in combined. Post treatment PET/CT scans demonstrated complete resolution of baseline abnormal FDG uptake in 16 of 19 HD groups (fig. 2, 3). In remaining 3 PET/CT showed residual disease. Maximum SUV of was 9.8 with range 9.8-1.16 patients who had negative PET/CT scan after, 15 were true negative and 1 was false negative (Fig. 4). In 3 patients who had positive PET/CT, 2 were true positive and 1 was false positive. The final outcome of patients is given in table-5.

	HD	NHL	Total
Post-Chemo PET/CT			
Normal	16	27	43
Residual Disease	03	06	09
Follow-up			
True Negative(TN)	15	25	40
False Negative(FN)	01	02	03
True Positive(TP)	02	05	07
False Positive(FP)	01	01	02

All 33 patients of NHL group received 6 cycles of CHOP chemotherapy. 6 patients received more than 6 cycles of chemotherapy and they were treated by both CHOP and ABVD in combination. Only one patient had received radiotherapy as additional treatment with chemotherapy. Post treatment PET/CT scans demonstrated complete resolution of baseline abnormal FDG uptake in 27 in 33 NHL groups (fig. 5). In remaining 6 PET/CT showed residual disease (Fig. 6). Maximum SUV of NHL patients was 6.9 and average was 2.1 (range 6.9-.5) 27 patients who had negative PET/CT scan after chemotherapy, 25 were true negative and 2 were false negative. Six patients who had positive PET/CT, 5 were true positive and one was false positive (Fig.7). The final outcome is given in table 5.



**Figure 5:** Showing Baseline SUV Vs Post-treatment SUV of NHL Patients



**Figure 6:** FDG PET-CT of 33/M patient with NHL showing residual active disease in post-chemo PET-CT, which progressed in follow-up PET-CT (Non-Responder)

**Clinical and PET/CT follow up results**

All patients underwent clinical follow-up. In addition, 32 of 52 patients also underwent third PET/CT scan. Based on the results of clinical and PET/CT follow-up, sensitivity, specificity and accuracy was calculated. The diagnostic values of PET/CT are given in table 6.

**Table-5 Showing final results of PET/CT**

Parameters	HD	NHL	Total
Post-Chemo PET/CT			
Normal	16	27	43
Residual Disease	03	06	09
Follow-up			
True Negative(TN)	15	25	40
False Negative(FN)	01	02	03
True Positive(TP)	02	05	07
False Positive(FP)	01	01	02

**DISCUSSION**

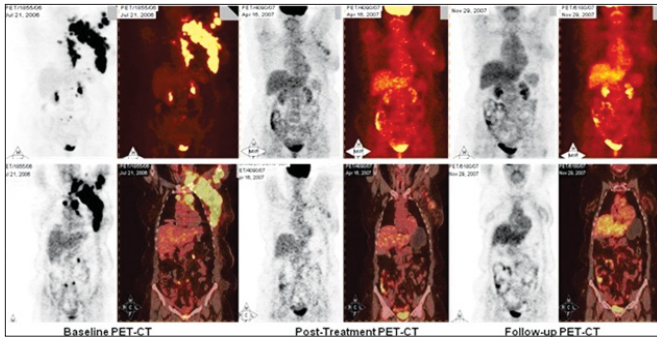
<sup>18</sup>F-FDG PET is an excellent imaging technique, in particular for cancer staging and therapy control, and probably the one clinical imaging technique that truly deserves the label “molecular imaging”. Nevertheless it has taken CT added to PET, that is, PET/CT to make this obvious to the medical community. The reason why PET/CT has been so successful are plentiful: PET and CT are highly synergistic. There is biological, biochemical,

technical, medical, and financial advantages of using PET/CT over PET. PET imaging is an excellence modality for lymphoma staging because when <sup>18</sup>F-FDG, it is able to demonstrate glucose uptake/metabolism is much more sensitive to demonstrate tumor response to therapy that are morphologic changes. This makes PET is not only excellence for staging but also very useful for the assessment of therapy. PET/CT currently represents the best of clinical molecular imaging. <sup>18</sup>F-FDG traces one of the dominant metabolic processes in the body clearly different from perfusion which can also be assessed to a certain degree with MR and CT. <sup>18</sup>F-FDG is also relatively easily quantified. There are several reasons in this category for integrating PET/CT, namely adding anatomic landmarks, “improving” spatial resolution, using CT for attenuation correction of emission PET data, increasing the efficiency of FDG use, and less well documented-possible complementary aspects of FDG.<sup>14-18</sup>

<sup>18</sup>F-FDG PET/CT has potential value in monitoring the response to treatment in patients with both NHL and HD. PET/CT provides functional and anatomical details in same setting. In addition, CT data is utilized for attenuation correction of PET images. Thus PET/CT offers several advantages including shorter image acquisition time, improve lesion localization and identification and more accurate. <sup>18</sup>F-FDG PET/CT may play an important role in evaluation and management of malignant lymphoma. After completion of chemotherapy, residual abnormalities representing either residual tumor or necrotic or fibrotic tissue are not uncommon, and FDG PET may be more accurate.

In this study, we included 52 patients, of which 19 were of HD and 33 were of NHL. All patients were of high-grade lymphoma as PET has been found to have lower sensitivity in detection of the disease of the disease in patients with low-grade lymphoma patients.<sup>19-23</sup> That is why all patients underwent pre-treatment and post-treatment PET/CT scans on the same dedication PET/CT scanner. Therefore, a bias factor of different machine was ruled out. The results of post-treatment PET/CT were compared with the results of CT and clinical outcome; the presence of relapse was determined on the basis of positive biopsy results of clinical follow-up data.





**Figure 7:** FDG PET-CT of 61/F patient with NHL showing residual active disease in post-chemo PET-CT, which was normal in follow-up PET-CT (False Positive)

In HD group, maximum SUV was 55.5 with a range 55.5-4.7. The average mean of SUV was 13.22. Most of the patients of HD had active disease in cervical, axillary and mediastinal L/Ns. In 10 patients of HD, active disease in L/Ns was noted above and below the diaphragm. In half of patients there were involvements of bone marrow, bone, spleen and liver. Post treatment PET/CT scans demonstrated complete resolution of baseline abnormal FDG uptake in 16 of 19 in this group.

Three patients had positive PET/CT. Maximum SUV of was 9.8 of HD patients and average was 2.1 (range 9.1-1). The sensitivity, specificity, positive and negative predictive values and accuracy of post therapy PET/CT scan in HD group was 67%, 94%, 67%, 94%, and 90% respectively. In NHL group, maximum SUV among NHL patients was 42.7 with range 42.7-3.1. The average mean of SUV WAS 9.9. Approximately, 75% of patients of NHL had active disease in L/Ns of both above and below the diaphragm. Approximately 75% patients of NHL had active disease in cervical, axillary, mediastinal, retroperitoneal and pelvis L/Ns. Post treatment PET/CT scan demonstrated complete resolution of baseline abnormal FDG uptake in 27 of 33 NHL group. Six patients showed positive PET/CT. Maximum SUV of NHL patients was 6.9 and average was 2.1 (range 6.9-0.5). The sensitivity, specificity, positive and negative predictive values and accuracy of post therapy PET/CT scan in NHL group was 71%, 96%, 83%, 93%, and 91% respectively. If we combined two groups, of 52 patients, 43 showed no pathologic FDG uptakes, whereas 9 showed persistent uptakes. Overall combined sensitivity, specificity, positive and negative predictive values and accuracy of post therapy PET/CT scan was 70%, 95%, 78%, 93%, and 90% respectively.

**Table-6 Showing Diagnostic Values of PET/CT**

	HD	NHL	Combined
Sensitivity(Sn)	67%	91%	70%
Specificity(Sp)	94%	96%	95%
Positive Predictive Value (PPV)	67%	83%	78%
Negative Predictive Value (NPV)	94%	93%	93%
Accuracy(Ac)	90%	91%	90%

Many of the studies showed <sup>18</sup>F-FDG PET is a powerful tool for the imaging of aggressive lymphoma. Their results indicate that FDG PET showed reasonable sensitivity and high specificity for evaluation of post-therapy in lymphoma.<sup>24-28</sup> These studies showed a sensitivity ranging 70-100% and specificity ranging 78-100%. Our results are similar to already existing data when sensitivity and specificity are compared. These results are very much in concordance with already published data. These studies also emphasize that high incidence of infection and inflammation does not affect diagnostic value of PET/CT in developing countries where an incidence of infections is high if carefully reporting is done.

Nowadays, PET/MRI is a principle imaging tool on experiments for oncology. Heacock et al studied to assess patency of PET/MRI for the evaluation of patients with lymphoma. They found similar results of PET/MRI as PET/CT.<sup>29</sup> There were several studies done with PET/MRI on oncology including lymphoma and results were also acceptable.<sup>30-33</sup> But we know that there are several limitations with MRI which still make PET/CT in choice.<sup>34</sup>

Only few studies were done on PET/CT for evaluation of treatment response in lymphoma. Zhao J et al assessed the value of hybrid PET/CT with <sup>18</sup>F-FDG after 3-4 cycles of chemotherapy for early evaluation of response to therapy and prediction of progression free survival (PFS) in NHL.<sup>35</sup> Sixty one consecutive NHL patients were included. After 3-4 cycles of chemotherapy, positive FDG lesions were found in 28 patients, minimal residual uptake (MRU) in 8 and negative scans in 25 patients. In FDG positive group, 22 patients showed progress and three died. Nine FDG negative patients and 4 patients from the MRU group relapsed. They concluded that early interim FDG imaging is an excellent and independent





predictor of PFS in NHL. An early assessment of chemotherapy response with FDG scans may provide useful information for selection of patients for alternative therapeutic strategies.

There are so many limitations of PET over PET/CT. Similar to Kazama et al, we also feel that post treatment FDG PET had lower sensitivity and cannot exclude the presence of minimal residual disease completely, which may lead to disease relapse. In the present study we also found 3 false negative PET/CT scans.<sup>36</sup> Furthermore, FDG is not a tumor specific substance, and increased accumulation may be seen in a variety of benign entities and scenarios (e.g. infection, drug toxicity, granulocyte colony-stimulating factors therapy, radiation therapy, physiologic activity, postoperative or post biopsy changes, fracture, degenerative change, injection leakage), which may yield false-positive findings.<sup>37-39</sup> We also share similar experience of false positive result of PET/CT. We also share similar experience of false positive results of PET/CT. We also had 2 false positive cases; both of these cases were false positive due to infections and inflammation.

## CONCLUSION

- <sup>18</sup>F-FDG PET/CT has potential value in monitoring the response to treatment in patient with both Non-Hodgkin's lymphoma (NHL) and Hodgkin's disease (HD).
- PET/CT provides functional and anatomical details in same setting and CT data is utilized for attenuation correction of PET image. Therefore, PET/CT offers several advantages including shorter image acquisition time, improve lesion localization and identification and more accurately.
- Minimal residual disease activity or low glycolytic activity can cause false negative results. Since FDG not being a cancer-specific agent, false positive results have also been noted in inflammatory lesions.

## REFERENCES

1. National Cancer Institute Publications. "What You Need To Know About™ Non-Hodgkin's Lymphoma." 06/25/1999; (1) 1-4.
2. "National Cancer Institute Publications" What You Need To Know About™ Non-Hodgkin's Lymphoma. 06/25/1999; (1) 2-5.
3. Rahmouni A, Divine M, Lavaud A, Hayoun C, Reyes F, Vasile N "Role of x-ray computed tomography in the follow-up of the course of Hodgkin's disease" J Radiol. 1993; 74(2):99-103.
4. Spaepen K, Stroobants S, Dupont P, Vandenberghe P, Thomas J, de Groot T, Balzarini J, De Wolf-Peeters C, Mortelmans L, Verhoef G. Early restaging positron emission tomography with (18) F-fluorodeoxyglucose predicts outcome in patients with aggressive non-Hodgkin's lymphoma. *Ann Oncol.* 2002; 13(9):1356-1363.
5. Herrmann K, Wieder HA, Buck AK, Schöffel M, Krause BJ, Fend F, Schuster T, Meyer zum Büschenfelde C, Wester HJ, Duyster J, Peschel C, Schwaiger M, Dechow T. Early response assessment using 3'-deoxy-3'-[18F] fluorothymidine-positron emission tomography in high-grade non-Hodgkin's lymphoma. *Clin Cancer Res.* 2007;13(12):3552-8.
6. Zhao J, Qiao W, Wang C, Wang T, Xing Y "Therapeutic evaluation and prognostic value of interim hybrid PET/CT with (18)F-FDG after 3-4 cycles of chemotherapy in NHL". *Hematology* 2007; 52(3):386-92.
7. Gaurav K, von Schulthess, Positron emission Tomography Verses Positron emission Tomography/Computed Tomography; From "unclear" to "New Clear" Medicine, Molecular Imaging and Biology. 2004; 6(4) :183-7.
8. Heacock LI, Weissbrot J, Raad R, Campbell, N, Friedman KP, Ponzio F, Chandarana H." PET/MRI for the evaluation of patients with lymphoma: initial observations" *AJR Am J Roentgenol.* 2015; 204(4):842-8.
9. Chavdarova LI, Tzonevska AD, Piperkova EN." Discrepancies and priorities in staging and restaging malignant lymphoma by SPET, SPET/CT, PET/CT and PET/MRI." *Hell J Nucl Med.* 2013;16(3):223-9.
10. Punwani S, Bainbridge A, Humphries P. "Accuracy of ADC estimates: response to letter by Priola et al. re Diffusion-weighted MRI of lymphoma: prognostic utility and implications for PET/MRI?" *Eur J Nucl Med Mol Imaging.* 2013;40(7):1110-1.
11. Probst S1, Mayo J, Moskovits T, Friedman K. "The appearance of epidural extranodal marginal zone lymphoma (MALToma) on F-18 FDG PET/CT and post hoc PET/MRI fusion" *Clin Nucl Med.* 2011; 36(4):303-4.
12. Maisey NR1, Hill ME, Webb A, Cunningham D, Flux GD, Padhani A, Ott RJ, Norman A, Bishop

- L. "Are 18fluorodeoxyglucose positron emission tomography and magnetic resonance imaging useful in the prediction of relapse in lymphoma residual masses?" *Eur J Cancer*. 2000;36(2):200-6.
13. Wieder HA, Buck AK, Schöffel M, Krause BJ, Fend F, Schuster T, Meyer zum Büschenfelde C, Wester HJ, Duyster J, Peschel C, Schwaiger M, Dechow T. Early response assessment using 3'-deoxy-3'-[18F] fluorothymidine-positron emission tomography in high-grade non-Hodgkin's lymphoma. *Clin Cancer Res*. 2007;13(12):3552-8.
  14. Filmont JE, Gisselbrecht C, Cuenca X, Deville L, Ertault M, Brice P, De Kerviler E, Briere J, Larghero J, Moretti JL, Mounier N. The impact of pre- and post-transplantation positron emission tomography using 18-fluorodeoxyglucose on poor-prognosis lymphoma patients undergoing autologous stem cell transplantation. *Cancer*. 2007; 110(6):1361-9.
  15. Gayed I, Eskandari MF, McLaughlin P, Pro B, Diba R, Esmali B. Value of positron emission tomography in staging ocular adnexal lymphomas and evaluating their response to therapy. *Ophthalmic Surg Lasers Imaging*. 2007; 38(4):319-25.
  16. Bishu S, Quigley JM, Bishu SR, Olsasky SM, Stem RA, Shostrom VK, Holdeman KP, Paknikar S, Armitage JO, Hankins JH. Predictive value and diagnostic accuracy of F-18-fluoro-deoxy-glucose positron emission tomography treated grade 1 and 2 follicular lymphoma. *Leuk Lymphoma*. 2007; 48(8):1463-4.
  17. Gustav K. von Schulthess, Positron emission Tomography Verses Positron emission Tomography/Computed Tomography; From "unclear" to "New Clear" Medicine, Molecular Imaging and Biology. 2004; 6 (4):183-7.
  18. Kumar R, Maillard I, Schuster SJ, Alavi A. Utility of fluorodeoxyglucose-PET imaging in the management of patients with Hodgkin's and non-Hodgkin's lymphomas. *Radiol Clin North Am*. 2004; 42(6):1083-100.
  19. Carreras Delgado JL. [PET in lymphomas: a pattern for the treatment at measure] *An R Acad Nac Med (Madr)*. 2004; 121(4):739-50.
  20. Kazama T, Faria SC, Varavithya V, Phongkitkarun S, Ito H, Macapinlac HA. FDG PET in the evaluation of treatment for lymphoma: clinical usefulness and pitfalls. *Radiographics*. 2005; 25(1):191-207.
  21. Avril NE, Weber WA. Monitoring response to treatment in patients utilizing PET. *Radiol Clin North Am*. 2005; 43(1):189-204.
  22. Kelloff GJ, Hoffman JM, Johnson B, Scher HI, Siegel BA, Cheng EY, Cheson BD, O'shaughnessy J, Guyton KZ, Mankoff DA, Shankar L, Larson SM, Sigman CC, Schilsky RL, Sullivan DC. Progress and promise of FDG-PET imaging for cancer patient management and oncologic drug development. *Clin Cancer Res*. 2005; 15; 11(8):2785-808.
  23. Kasamon YL, Jones RJ, Wahl RL. Integrating PET and PET/CT into the risk-adapted therapy of lymphoma. *J Nucl Med*. 2007; 48 Suppl 1:19S-27S.
  24. Brepoels L, Stroobants S, Verhoef G. PET and PET/CT for response evaluation in lymphoma: current practice and developments. *Leuk Lymphoma*. 2007; 48(2):270-82.
  25. Specht L. 2-[18F] fluoro-2-deoxyglucose positron emission tomography in staging, response evaluation, and treatment planning of lymphomas. *Semin Radiat Oncol*. 2007; 17(3):190-7.
  26. MacManus MP, Seymour JF, Hicks RJ Overview of early response assessment in lymphoma with FDG-PET. *Cancer Imaging*. 2007; 7(3):10-8.
  27. van der Hiel B, Pauwels EK, Stokkel MP. Positron emission tomography with 2-[18F]-fluoro-2-deoxy-D-glucose in oncology. Part IIIa: Therapy response monitoring in breast cancer, lymphoma and gliomas. *J Cancer Res Clin Oncol*. 2001; 127(5):269-77.
  28. Heacock LI, Weissbrot J, Raad R, Campbell, N, Friedman KP, Ponzio F, Chandarana H." PET/MRI for the evaluation of patients with lymphoma: initial observations" *AJR Am J Roentgenol*. 2015; 204(4):842-8.
  29. Chavdarova LI, Tzonevska AD, Piperkova EN." Discrepancies and priorities in staging and restaging malignant lymphoma by SPET, SPET/CT, PET/CT and PET/MRI." *Hell J Nucl Med*. 2013;16(3):223-9.
  30. Punwani S, Bainbridge A, Humphries P. "Accuracy of ADC estimates: response to letter by Priola et al. re Diffusion-weighted MRI of lymphoma: prognostic utility and implications for PET/MRI?" *Eur J Nucl Med Mol Imaging*. 2013;40(7):1110-1.
  31. Probst S, Mayo J, Moskovits T, Friedman K. "The appearance of epidural extranodal marginal zone lymphoma (MALToma) on F-18 FDG PET/CT and post hoc PET/MRI fusion" *Clin Nucl Med*. 2011; 36(4):303-4.



32. Maisey NR, Hill ME, Webb A, Cunningham D, Flux GD, Padhani A, Ott RJ, Norman A, Bishop L. "Are 18fluorodeoxyglucose positron emission tomography and magnetic resonance imaging useful in the prediction of relapse in lymphoma residual masses?" *Eur J Cancer*. 2000; 36(2):200-6.
33. Mark Adrian, MD, FRCPC, "MRI: Understanding its limitations" *BCMJ*. 2005; 47(7), 359-361.
34. Kazama T, Faria SC, Varavithya V, Phongkitkarun S, Ito H, Macapinlac HA. FDG PET in the evaluation of treatment for lymphoma: clinical usefulness and pitfalls. *Radiographics*. 2005; 25(1):191-207.
35. 73 Gordon BA, Flanagan FL, Dehdashti F. Wholebody positron emission tomography: normal variations, pitfalls, and technical considerations. *AJR Am J Roentgenol* 1997; 169:1675-1680.
36. Zhuang H, Cunnane ME, Ghesani NV, Mozley PD, Alavi A. Chest tube insertion as a potential source of false-positive FDG-positron emission tomographic results. *Clin Nucl Med* 2002; 27: 285-286.
37. Meyer M, Gast T, Raja S, Hubner K. Increased F-18 FDG accumulation in an acute fracture. *Clin Nucl Med* 1994; 19:13-14.
38. Alibazoglu H, Megremis D, Ali A, LaMonica G. Injection artifact on FDG PET imaging. *Clin Nucl Med* 1998; 23:264-265.