

# Salivary Gland Swellings: A Retrospective Study of Cytological Findings

Swasti Sharma<sup>1</sup>, Laxman Banstola<sup>2</sup>

<sup>1</sup>Department of ENT-HNS, Western Regional Hospital, Pokhara Academy of Health Sciences

<sup>2</sup>Department of Pathology, Western Regional Hospital, Pokhara Academy of Health Sciences

Correspondence:

Dr. Swasti Sharma, MD

Department of ENT-HNS, Western Regional Hospital, Pokhara Academy of Health Sciences

**Email:** swastipoudel@yahoo.com

Article received : 2<sup>nd</sup> October, 2019

Article accepted : 16<sup>th</sup> October, 2019

## ABSTRACT

**Introduction:** Salivary gland disorders can arise from infection, inflammation, cystic changes, degenerative process and neoplastic etiologies. Most common conditions of salivary gland disease result from acute infection and inflammation. These swellings can usually be diagnosed clinically. Reports of salivary gland tumours are also on the rise, with one study revealing the incidence to be 6% of all head and neck tumors. **Materials and methods:** Retrospective analysis of salivary gland swellings, diagnosed by fine needle aspiration cytology from Kartik 2072 to Chaitra 2074, was done. **Result:** The most common age group with manifestation of salivary gland pathology was 11-20 years (19.4%). Non neoplastic swellings comprised 56% of the cases, while the rest comprised of neoplastic swellings. **Conclusion:** Chronic infection and pleomorphic adenoma were the most common diseases involving salivary glands are, among nonneoplastic and neoplastic group respectively. **Keywords:** salivary gland, malignancy, benign tumours, sialdenitis

## INTRODUCTION

Salivary glands are exocrine glands. They are responsible for production and secretion of saliva. They consist of parotid, submandibular, sublingual, and the minor glands that are numerous and widely distributed throughout the mouth and oropharynx.<sup>1-2</sup> Salivary gland disorders can arise from infection, inflammation, cystic changes, degenerative process and neoplastic etiologies.<sup>3-4</sup>

Most common conditions of salivary gland disease arise from acute infection and inflammation.<sup>5-6</sup> Salivary glands can be involved in a number of systemic diseases including connective tissue diseases. <sup>7</sup>Reports of salivary gland tumours are also on the rise, with one study revealing the incidence to be 6% of all head and neck tumors. <sup>8</sup>

Usually, these swellings can be diagnosed clinically. Sometimes, it can be difficult to establish as to whether pathology arises from the salivary gland

itself or from adjacent structures such as lymph nodes, soft tissues or skin.<sup>2</sup>

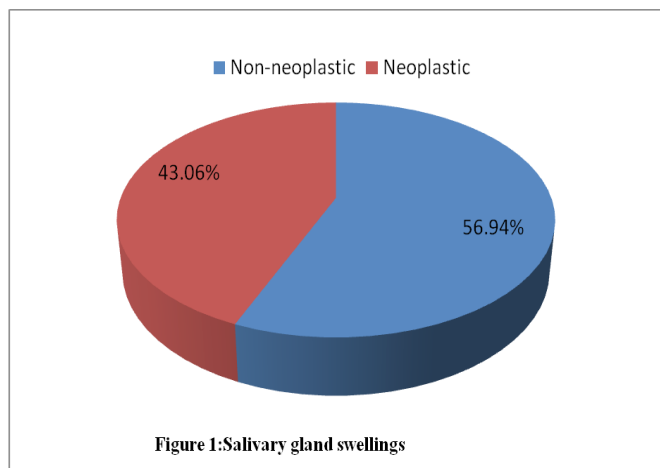
Fine needle aspiration cytology (FNAC) is a useful method for evaluating suspicious salivary glands lesions due to its low cost, minimum morbidity, rapid turnaround time, high specificity, and sensitivity. By cytology, lesions can be divided into inflammatory, reactive, benign, or malignant and, if possible, specific diagnosis is given which helps in planning the management of the lesion.<sup>2</sup>

### MATERIALS AND METHODS

Records were studied from electronic database of Department of Pathology. Cases of salivary gland swellings diagnosed at the department from Kartik 2072 to Chaitra 2074 were taken for study. Demographic profiles (age, gender) were obtained from the data. The site of disease was also noted. The cytological diagnoses of salivary gland swellings were observed. All these data were compiled and entered in Microsoft Excel. Descriptive analysis was then done among the variables in the study. Ethical clearance was obtained from the hospital administration.

### RESULTS

Out of a total of 72 patients, 36 patients were males and 36 patients were females. The most common age group with manifestation of salivary gland pathology was 11-20 years (19.4%). Non neoplastic swellings comprised 56.94% of the cases, while the rest comprised of neoplastic swellings (43.06%).



There were 31 cases in neoplastic group. 25 cases out of these were pleomorphic adenoma, which was 80.64% of the neoplastic swellings. 19 cases of pleomorphic adenoma presented as parotid mass and 6 presented as submandibular mass. 4 patients were diagnosed with Warthin’s tumour. All of these were observed in submandibular glands. Mucoepidermoid carcinoma was detected in 2 patients who underwent FNAC for submandibular swellings. Mucoepidermoid carcinoma was diagnosed in patients of seventh decade.

There were 41 patients in non neoplastic group. Chronic sialadenitis was the commonest condition in this group. Chronic sialadenitis was found in 26.82 % of the non neoplastic swellings. It comprised of 15.2% of all salivary gland swellings. Sialadenosis was observed in 7 cases, acute sialadenitis in 6 cases, cystic lesion in 10 patients and benign lesion in 7 cases.

Parotid swellings accounted for 59.72% of total patients and submandibular swellings were observed in 40.27% of all patients.

Overall, pleomorphic adenoma was the commonest finding among salivary gland swellings (34.72% of all cases).

### DISCUSSION

One study observed the age range of 8 to 68 years with mean age of 40 years with male predominance in patients with salivary swellings.<sup>8</sup>The rate of nonneoplastic lesion their study was 53.22%. Most common age group for nonneoplastic lesions was 20 to 40 years and male to female ratio was 3.7: 1. In the present study, the commonest age group was found to be 11-20 years, with equal number of male and female patients. Non neoplastic conditions comprised 56% of all cases in the present study.

According to the study by Anita et al, most

common nonneoplastic lesion was chronic sialadenitis followed by benign cyst and most of the nonneoplastic lesions involved the submandibular gland. <sup>8</sup>Benign neoplasms accounted for 39 cases (31.45%). The rate of benign neoplasm was lower than other reports which ranged from 49 to 83%. Pleomorphic adenoma was observed as the commonest benign neoplasm. In the present study too, chronic sialadeneitis was the most common finding among nonneoplastic swellings and pleomorphic adenoma was the most frequent observation among neoplastic swellings.

Pleomorhic adenoma and Warthin's tumour were the two benign tumours diagnosed in the present study. Four cases of Warthin's tumour were found. Similar findings were observed by Veneet Kaur Sandhu et al.<sup>3</sup>

A study analysed 58,880 specimens of salivary gland tumours arising from major and minor salivary glands. <sup>9</sup>Of these, 741 cases (1.3% of all cases) were diagnosed as salivary gland tumours. 481 (64.9%) were benign tumours and 260 (35.1%) were malignant tumours, with the most common tumors being pleomorphic adenoma and mucoepidermoid carcinoma respectively. The present study also revealed pleomorphic adenoma as the most common benign tumour. Mucoepidermoid carcinoma was observed in 2 patients, which was the only malignant tumour seen in this study.

Another study conducted retrospective analysis of 684 cases of salivary gland tumours. <sup>10</sup>Of these, 62% were benign and 38% were malignant. The most common benign tumour was pleomorphic adenoma and the most common malignant tumour was adenoid cystic carcinoma. Next common malignant tumour was mucoepidermoid carcinoma.

In one study, it was reported that the three most commonly diagnosed salivary gland diseases are infections, sialolithiasis and mucoseles. <sup>6</sup>In

the present study, sialolithiasis and lesions from minor salivary glands were not included, because these cases were diagnosed clinically. So only the swellings arising from major salivary glands were taken for the study.

## CONCLUSION

A wide range of diseases can involve the salivary glands. In this retrospective study, the most common diseases involving salivary glands were observed to be chronic infection and pleomorphic adenoma, among nonneoplastic and neoplastic group respectively.

## REFERENCES

1. Barnes L, Eveson JW, Reichart P, Sidransky . Pathology and genetics of head and neck tumours. Lyon:IARC/Press; 2005.
2. Fernandes H,D'souza CR, Khosla C, George L, Katte NH. Role of FNAC in the preoperative diagnosis of salivary gland lesions. J Clin Diagn Res. 2014 Sep;8(9).
3. Sandhu VK, Sharma U, Singh N, Puri A. Cytological spectrum of salivary gland lesions and their correlation with epidemiological parameters. JOMFP. 2017 Aug;21(2): 203-10.
4. Wilson KF, Meier JD, Ward PD. Salivary gland disorders. Am Fam Physician. 2014 Jun;89(11):882-8.
5. Porter SR. Non-neoplastic salivary gland diseases. In: Gleeson M, Browning G, Burton MJ, Clarke R, Hibbert J, Jones N et al. Scott-Brown's Otorhinolaryngology, Head and Neck Surgery. 7 nd ed. London: Hodder Arnold; 2008. p 1898-1916.
6. Delli K, Spijkervet FK, Vissink A. Salivary

- gland diseases:infections,sialolithiasis and mucoceles. *Monogr Oral Sci.* 2014 May;24:135-48.
7. Pandey A, Pandey M, Pandey VP, Ravindran V. Oral manifestations of autoimmune connective tissue diseases. *Indian J Rheumatol* 2018;13:264-72.
8. Omhare A, Singh SK, Nigam JS, Sharma A. Cytohistopathological Study of Salivary Gland Lesions in Bundelkhand Region, Uttar Pradesh, India. *Pathology Research International.* 2014 Aug;5.
9. Jones AV, Craig GT, Speight PM, Franklin CD. The range and demographics of salivary gland tumours diagnosed in a UK population. *Oral oncology.* 2008 Apr; 44(4): 407-17.
- 10.Subhashraj K. Salivary gland tumors:a single institution experience in India. *British Journal of oral and maxillofacial surgery.* 2008 Dec; 46(8):635-8