

Original Investigation

Morphological Study of Right and Left Coronary Artery: A Cadaveric Study

Ajeevan Gautam^{1*} | Rajib Chaulagain² | Chandan Sintakala³ | Kun Hing Yong¹

¹PhD Scholar, Griffith University, Queensland, Australia; ² Associate Professor, Department of Oral Pathology, Chitwan Medical College, Chitwan, Nepal; ³ Assistant Professor, Department of Anatomy, Lumbini Medical College, Palpa, Nepal

ARTICLE INFO

Article history:

Received: 5 April 2023

Revised: 17 May 2023

Accepted: 21 May 2023

*Correspondence:

Dr. Ajeevan Gautam,


PhD Scholar,

Griffith University, Queensland,
Australia

E-mail:

ajeevan.gautam@griffithuni.
edu.au;

gautamaajeevan@gmail.com

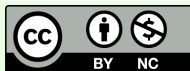 0000-0001-7673-181X

Citation:

Gautam A, Chaulagain R,
Sintakala C, Yong KH.Morphological study of
Right and Left Coronary

Artery: A Cadaveric study.


MedS. J. Med. Sci.2023;3(5):20-23.



ABSTRACT

INTRODUCTION: The coronary arteries furnish the heart with its special arterial supply. The right coronary artery descends into the coronary sulcus after emerging from the right aortic sinus. The left coronary artery, which arises from the left aortic sinus, travels briefly via the coronary sulcus before splitting into two or three branches at the atrioventricular groove. This study aimed to estimate the standard size of the cadaveric heart and assess the morphological variation of the coronary artery. **MATERIALS AND METHODS:** An observational cross-sectional study was conducted at the dissection hall of the Anatomy department at Chitwan medical college. Twenty four (24) human hearts present at the dissection hall and museum were used for the study. The weight of the heart was taken; a complete tracing of the coronary artery was done. Photographs were taken at different sites of dissection to find anomalies. Deformed specimens were excluded. **RESULTS:** Among 24 human hearts studied, the average weight was between 243gm to 322gm. The length of the heart was 11.02 to 11.89cm and the width was 7.97 to 8. 56cm. The study reported right coronary dominance in 96% and left coronary dominance in 4% respectively. The study did not report any splitting of the right coronary artery but trifurcation of the left coronary artery was commonest (58%). **CONCLUSIONS:** This study concludes that the right coronary dominance is most common and the left coronary artery shows several variations than the right. The findings may be helpful in academic, medical, and surgical management like open heart surgery angioplasty.

Keywords: Anomalies, branching patterns, coronary dominance

 This is an open access article distributed under the terms of the Creative Commons Attribution License, which permits unrestricted use, distribution, and reproduction in any medium, provided the original author and source are credited <https://doi.org/10.3126/mjmms.v3i5.60039>

INTRODUCTION

The coronary arteries furnish heart with its special arterial supply. The myocardial and epicardium of the heart are supplied by the right and left coronary arteries, which branch off the aorta [1]. The right coronary artery descends into the coronary sulcus after emerging from the right aortic sinus. Before continuing to the posterior side of the heart, the right coronary artery emits a right marginal branch that travels towards the top of the heart [2]. The posterior interventricular branch is then formed by the right coronary artery as it travels between the interatrial and interventricular junction of the heart's crux before it terminates in the coronary sulcus [3,7]. The left coronary artery, which arises from the left aortic sinus, travels briefly via the coronary sulcus before splitting into two or three branches at the atrioventricular groove [1,3]. A diagonal branch emerges from the anterior interventricular branch of the left coronary artery, which proceeds in the direction of the apex.

Before reaching the crux, the left coronary arteries circumflex branch splits off a left marginal branch and comes to an end on the posterior portion [1,3,4,6]. The posterior interventricular artery oversees supplying the left ventricle's inferior and posterior walls, as well as the back portion of the interventricular septum. The vessel often develops from either the right circumflex artery (left dominant) or the right coronary artery (right dominant), or both (codominant) [1,3,5]. In case reports, physiologic variants have been discussed, including one with a "superdominant" origin from the left anterior descending artery. According to estimates, the posterior interventricular artery originates from the right coronary artery, and between 70 to 80 per cent of the population has a dominant right heart. The posterior interventricular artery originates from the left circumflex artery, with left cardiac dominance occurring in 5 to 10% of the population. The posterior interventricular artery fed by both the left circumflex

artery and right coronary artery dominates in about 10 to 20% of cases [5]. These branches collectively ensure that all regions of the heart receive the oxygen and nutrients necessary for proper functioning. Any blockage or impairment in these arteries can lead to serious cardiac issues, including heart attacks and other cardiovascular diseases. It is crucial to maintain a healthy lifestyle and to seek medical attention if there are any indications of heart-related problems.

Coronary artery anomalies are frequent [9]. The first description of a single coronary artery was published in 1903[8]; since then, other examples have been reported. In 1987, a double right coronary artery was described [9]. It is generally known that congenital cardiovascular defects such as transposition of the major vessels, coronary fistulas, bicuspid aortic valve, and tetralogy of Fallot are frequently linked to single coronary arteries. Coronary artery anomalies can hinder healthy lifestyles by necessitating precautions in physical activity, potentially requiring medical intervention, and introducing psychological stress [8]. When the anterior interventricular branch and circumflex arteries emerge straight from the left aortic sinus rather than bifurcating from a single trunk, the left coronary artery is absent entirely [10,4]. The distribution patterns of the vessels are otherwise normal, and this aberration is more common when there is left coronary artery dominance and aortic valvular disease [11,4]. Secondary absence of the left coronary artery refers to situations when the anterior interventricular branch and circumflex arteries originate outside the left coronary sinus or ectopically [10].

This study plays a vital role in advancing research by providing a detailed understanding of cardiac anatomy and pathology and serves as a foundational resource for medical education and technological innovation. No data exists about the standard dimension of the Nepalese Heart. Hence, the objective of the study was to evaluate the standard size of the cadaveric heart and to assess the morphological variation of the coronary artery.

MATERIALS AND METHODS

Study design and setting

This was an observational study conducted at Chitwan Medical College. Data collection was done at Chitwan Medical College from 10th September 2022 to 14th February 2023 and analysis and report writing was done at Griffith University Brisbane, Australia.

Data collection procedure and study variables:

Twenty-four (24) isolated, properly embalmed formalin-fixed cadaveric hearts preserved in the dissection hall were taken into consideration for the study. All intact hearts present in the department were studied and age estimation of the heart was not done. Tracing of the coronary artery was done. A well-designed proforma was used to collect the study variables. The heart with cuts, tears in the blood vessels and deformities were excluded from the study. The parameters noted were the weight of the heart, Length and width of the heart, origin of the coronary artery and number of branches from the right and left coronary artery. Photographs were taken as a record.

Statistical analysis and data management:

The findings were expressed as absolute numbers and 118 percentages. Analysis was done with MS Excel.

Ethical consideration:

The Ethical approval was obtained from institutional Review Committee (Reference No: CMC-IRC/079/080-055)

RESULTS

The heart along with its great vessels were intact in the samples of investigation. The apex, base, sternocostal, diaphragmatic and left lateral surfaces were identified. Atrioventricular and interventricular sulcus were assessed during the study. The blood clot was present in the inner part which might be because of the cause of death. On examining the weight of the Heart, we found that it was from 243gm to 322gm in the studied sample.

Table 1 showed the length of the cadaveric heart was from 11.02cm to 11.89cm and its width was between 7.97cm to 8.56cm. Our study was also focused to see the branching of the right and left coronary arteries.

Table 1 Showing the length and width of the heart.	
Characteristics	Measurement(cm)
Length	11.02-11.89
Width	7.97-8.56

We could not report any splitting of the right coronary artery. Similarly splitting of the left coronary artery was as shown in Table 2.

Table 2 Showing the frequency distribution of the branching pattern of the Left Coronary Artery (LCA)	
Frequency	Branching Pattern LCA(n)%
Bifurcation	10(42)
Trifurcation	14(58)
Quadrification	0(0)

We reported bifurcation of the left coronary artery in 42% of the specimen whereas Trifurcation was seen in 58%. Similarly, the study was also focused to study coronary dominance. The findings were as reported in Table 3. We reported that almost all ie.96% of the studies specimen showed right coronary dominance. Only 4% of the study reported Left coronary dominance. Our study could not report co-dominance type.



Figure 1| Heart with a left coronary artery and its branches

Table 3 | Showing coronary dominance of the heart.

Frequency	Coronary Dominance(n)%
Right Coronary Dominance	23(96)
Left Coronary Dominance	1(4)
Co-Dominance	0(0)




Figure 2| Heart with right coronary artery and its branches

DISCUSSION

The goal of this research was to investigate the weight, length and weight of the heart. Also, we were focused on the coronary artery. The detailed knowledge regarding the anatomy of the heart and its artery is of great significance for planning operative strategies for various procedures of the heart and coronary artery. Surgeons should exclude the possibility of the presence of any obstruction in any branches before the surgical procedure [13]. The findings of the study suggest that there are significant variations in the formation and branching pattern of coronary arteries. A study on normal weight in Men was conducted among 232 healthy men who died from sudden traumatic death and reported the average weight of the heart to be between 188gm to 575 gm with an average of 331 gm [14].

Our study reported the weight of the heart to be 243gm to 322gm. The findings of the study are like the findings of ours. This similarity might be because of genetic and environmental factors. A cross-sectional study conducted in Iran among 550 cadavers the average weight of the heart as 247.78 ± 62.27 grams. They also reported the mean values of the heart length, width as 11.41 ± 2.15 cm, 8.21 ± 4.38 cm [15]. Their findings are like the findings of ours. We reported the weight of the heart between 243gm to 322gm. Our findings showed the length as 11.02-11.89cm and

width as 7.97-8.56cm. This similarity might be because of the genetic factor, whereas environmental factors may also a major role in it. In the south Indian population, Aricatt DP et al. [16] reported right coronary dominance in 85.5%, they found left coronary dominance in 9.7% and co-dominance in 4.8% of cases. Similarly, Santos JCCD et al. [17] in their study on morphological analysis of myocardial bridges and coronary artery dominance among the north Brazilian population reported 52.6% as right coronary dominance and 22.8% as left coronary dominant. Also, a study conducted by Khwansang N et al. [18] reported right coronary dominance in 93% of the studied cadavers. Left coronary dominance and co-dominance were just 5% and 2% respectively.

The result from the present study and the study done in India, Thailand Iran, and Brazil demonstrated the variation in coronary dominance [15,16,17,18]. khwansang N et al. [18], also commented on the splitting of the right and left coronary arteries in their study. They reported trifurcation of the left coronary artery was most common (57%) followed by bifurcation (34%) and quadrification (9%). Singh S et al [4] reported Bifurcation was the most frequent branching pattern in the LCA (65.8%), followed by trifurcation and quantification (20.4% and 1.6%, respectively). The result from the present study and

the study done in Thailand and South Africa show there exists variation in the splitting of the coronary artery. This variation might be because of developmental factors, and to some extent, it might be the result of genetic and environmental factors. This is a single centered study, and it cannot be generalised. The generalised study from all the medical schools could have been conducted, however, it was limited by the objectives of the study.

CONCLUSIONS

Awareness of such variation is important from academic, surgical, and radiological aspects. With the increased number of cases of cardiac surgery, our findings would help surgeons to reduce the incidence of accidents during cardiac surgeries

ADDITIONAL INFORMATION AND DECLARATIONS

Acknowledgements: We would like to thank Chitwan Medical College for providing us with the consent to conduct this study at this esteemed institute.

Competing Interests: The authors declare no competing interests.

Funding: No funding was received for this research.

Author Contributions: Concept and design: AG, RC; Statistical analysis: AG, KHY; Writing of the manuscript: AG, CS; Data collection: AG; Revision and editing: AG, RC, CS, KHY. All authors have read and agreed with the contents of the final manuscript towards publication.

Data Availability: Data will be available upon request to corresponding authors after valid reason.

REFERENCES

- Bannister LH, Berry M, Collins P et al. Grays Anatomy: The anatomical basis of medicine and surgery. 38th edition.
- Moore KL, Dalley AF, Agur AMR. Clinically Oriented Anatomy. Sixth Edition. Lippincott Williams and Wilkins, (Wolters Kluwer) 2010.
- Datta AK. Essentials of human anatomy, part 1—thorax and abdomen, 3rd ed. Current Books International, Calcutta: 1994.
- Singh S, Ajayi N, Lazarus L, Satyapal KS. Anatomical study of the morphology of the right and left coronary arteries. *Folia Morphol.* 2017;76(4):668-674. [DOI][Full Text]
- Shahoud JS, Ambalavanan M, Tivakaran VS. Cardiac Dominance. [Updated 2022 Sep 26]. In: StatPearls [Internet]. Treasure Island (FL): StatPearls Publishing; 2022 Jan. Available from: <https://www.ncbi.nlm.nih.gov/books/NBK537207/> [Full Text]
- Lujinovič A, Ovčina F, Voljevica A, Hasanovič A. BRANCHING OF MAIN TRUNK OF LEFT CORONARY ARTERY AND IMPORTANCE OF HER DIAGONAL BRANCH IN CASES OF CORONARY INSUFFICIENCY. *Bosn J Basic Med Sci.* 2005 Aug;5(3):69-73. PMID: PMC7202155. [Full Text][PubMed]
- Waleed T. Kayani, Glenn N. Levine, Chapter 13 - Coronary Angiography and Intracoronary Imaging and Physiologic Assessment, Editor(s): Glenn N. Levine, Cardiology Secrets (Fifth Edition), Elsevier, 2018, Pages 111-121, ISBN 9780323478700 <https://doi.org/10.1016/B978-0-323-47870-0.00013> (<https://www.sciencedirect.com/science/article/pii/B9780323478700000131>).
- Villa AD, Sammut E, Nair A, Rajani R, Bonamini R, Chiribiri A. Coronary artery anomalies overview: The normal and the abnormal. *World J Radiol.* 2016 Jun 28;8(6):537-55. [Full Text] [PubMed]
- Gautam A, Dhital BM, Pokhrel M, Kafle A. Collateral Development in Patients Undergoing Coronary Angiography in a Tertiary Care Centre: A Descriptive Cross-sectional Study. *J Nepal Med Assoc.* 2022 Aug 1;60(252):707-709. [Full Text] [PubMed]
- Angelini P, Villason S, Chan AV, Diez JG. Coronary Artery Anomalies: A Comprehensive Approach. Lippincott Williams & Wilkins, (Wolters Kluwer) 1999: 27-79. [Full Text] [PubMed]
- Tomar S, Aga P, Sharma PK, et al. 2013. Normal and variant anatomy of a left coronary artery: 64 slices multi detector computed tomography (MDCT) coronary angiographic depiction in North Indian population. *Int J Scien Res Publications.* 2013; 3(8): 1-17. [Full Text]
- Dvir D, Kornowski R, Gurevich J, et al. Degrees of severe stenoses in sigma-shaped versus C-shaped right coronary arteries. *Am J Cardiol.* 2003; 92(3): 294-298, indexed in Pubmed: 12888136. [Full Text][PubMed]
- Gautam A et al. Variation in the formation of the renal artery. *Journal of College of Medical Sciences-Nepal,* 16(1), 41-43. <https://doi.org/10.3126/jcmsn.v16i1.24472>. [Full Text] [DOI]
- Molina DK, DiMaio VJ. Normal organ weights in men: part I-the heart. *Am J Forensic Med Pathol.* 2012 Dec;33(4):362-7. doi 10.1097/PAF.0b013e31823d298b. PMID: 22182983. [Full Text] [DOI]
- Mohammadi S, Hedjazi A, Sajjadian M, Ghoroubi N, Mohammadi M, Erfani S. Study of the normal heart size in Northwest part of Iranian population: a cadaveric study. *J Cardiovasc Thorac Res.* 2016;8(3):119-125. doi: 10.15171/jcvtr.2016.25. Epub 2016 Sep 26. PMID: 27777697; PMID: PMC5075360. [PubMed] [Full Text]
- Aricatt DP et al. A study of coronary dominance and its clinical significance. *Folia Morphol.* 2023 Vol. 82, No. 1, pp. 102-107 DOI: 10.5603/FM.a2022.0005 [Full Text]
- Claudino Dos Santos JC, Barreto JEF, Fernando de Sousa Rodrigues C, Serra de Lima Júnior FA, de Sá Braga Oliveira A. Morphological analysis of myocardial bridges and Coronary arterial dominance in northeast Brazil. *Morphology.* 2022 Jun;106(353):92-97. doi 10.1016/j.morpho.2021.03.003. Epub 2021 Mar 26. [Full Text] [PubMed]
- Natatcha Khwansang, Vilai Chentanez. Anatomic variations of coronary arteries: origins, branching patterns, and abnormalities. *Asian Biomed (Res Rev News)* 2018; 12(3 Anat issue Pt 1):117-123 [Full Text]

Publisher's Note

MJMMS remains neutral with regard to jurisdictional claims in published materials and institutional affiliations.



CCREACH will help you at every step for the manuscript submitted to MJMMS.

- We accept pre-submission inquiries.
- We provide round the clock customer support
- Convenient online submission
- Plagiarism check
- Rigorous peer review
- Indexed in NepJOL and other indexing services
- Maximum visibility for your research
- Open access

Submit your manuscript at:
Website: www.medspirit.org
e-mail: editormjmms@gmail.com

