



Case Report

Duodenal Ulcer Perforation in Pediatric Population: A Rare Entity

Rai Binod Kumar,¹ Alam MD Shahid^{1*}, Sah Chandrika¹, Yadav Aditya Prakash¹

¹Department of Surgery, National Medical College Teaching Hospital Birgunj, Nepal.

Date of Submission: March 09, 2020

Received in Revised Form: April 05, 2020

Date of Acceptance: April 24, 2020

Date of Publishing: July 30, 2020

ABSTRACT

In pediatric age group peptic ulcer disease and duodenal perforation are usually rare condition. We report here a case of 3 years old girl who presented with upper abdominal pain, fever. On examination, she was febrile, tachycardia, with the feature of peritonitis. X-ray Abdomen revealed pneumoperitoneum. After resuscitation and investigating the child, a provisional diagnosis of peritonitis due to hollow viscus perforation was made. The child was planned for laparotomy. Intraoperative diagnosis of first portion of duodenum perforation was made and she underwent repair of perforation.

Key words: Duodenal perforation, Peritonitis, Laparotomy.

***Corresponding Author:** Dr. MD Shahid Alam, Lecturer, Department of General Surgery, National Medical College, Birgunj, Parsa, Nepal, Mob No: 9804280091, Email: shahidalam10143@gmail.com.

INTRODUCTION

Rare cause of life-threatening abdominal pain in children is Peptic ulcer disease (PUD), which may be complicated by severe hemorrhage or perforation. Perforation is the second most common complication of peptic ulcer disease.^{1,2} The disease is characterized by a loss of tissue penetrating gastrointestinal mucosa. Exact etiology of perforation still remains unclear, but some factors such as stress, an underlying disease, drugs like corticosteroid and non-steroidal anti-inflammatory drugs.³ It is often localized on the anterior wall of the first part of duodenum. It is diagnosed by the presence of free air under diaphragm on radiological examination.^{3,4} However, an absence of free air under the diaphragm does not rule out the diagnosis of perforation. The incidence of duodenal perforation/peptic ulcer perforation is less in pediatrics population. However in earlier times, the mortality for duodenal ulcer perforation in childhood was very high as in one of the report shows only 50 cases out of 118 survived.⁴

Here we are reporting a case who presented in emergency with feature of peritonitis. X-ray shows free gas under diaphragm. On exploration duodenal perforation was found and was repaired successfully.

CASE REPORT

3 years old female patient was brought in the emergency by her parents with the history of fever for 17 days which was not documented, partially relieved by the medication, and was not associated with chills and rigors. She also complained of pain abdomen which was generalized, without any relieving or aggravating factors and was not associated with vomiting. On examination, general condition was ill-looking, lying supine on bed, vital were within normal limit. Abdomen was distended, tender with generalized guarding and rebound tenderness. Liver dullness was obliterated and bowel sound was sluggish.

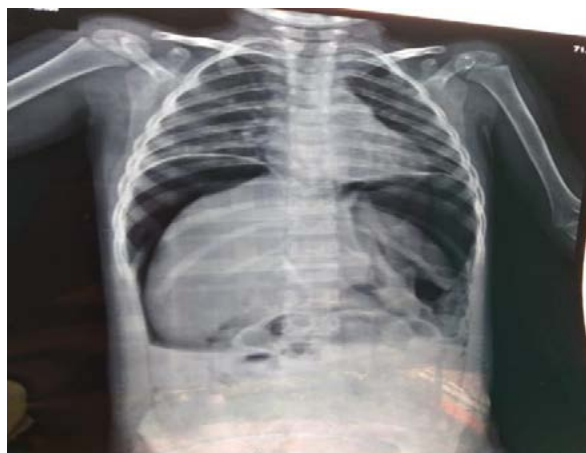

Fig 1: Free gas under both domes of diaphragm

DISCUSSION

Peritonitis due to hollow viscous perforation is the rare cause of acute abdomen in children. Exact etiology and pathology is not known but it have been reported that the incidence is 1.55 cases per year in the Indian population.⁵ Risk factors for duodenal perforation in children are as like the adults. Duodenal

Chest and cardiac examination was within normal limit. On review of her blood analysis there was high total leucocytes count of 28,400. Rest blood analysis was within normal limit. On Chest X-ray PA view, free gas was present on both dome of diaphragm (Fig 1). Ultrasound of abdomen revealed moderate ascites with internal septation and increased echogenicity in the upper quadrant. Patient underwent exploratory laparotomy and the intra-operative finding was perforation about 0.5x0.5 cm on anterior wall of first part of the duodenum (fig 2) with moderate peritoneal contamination. Stomach and pyloric region were unremarkable. Rest of bowel was normal. Classical Graham patch repair was done; abdomen was closed with drain in subhepatic and pelvic. The initial postoperative period was quite critical however patient recovery was uneventful and she was discharge on 12th day.

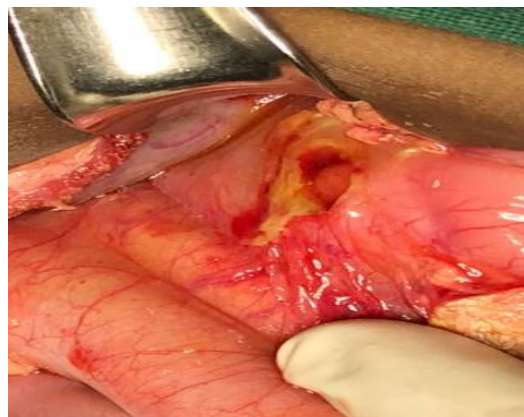


Fig 2: Perforation at first part of duodenum

ulcer in children can also be associated with Zollinger Ellison syndrome, sickle cell anemia, Helicobacter pylori infection and blood group "O" but in western countries it is due to the steroid administration, NSAIDS and in the Asian countries, it is due to the malaria, gastroenteritis or lymphoma.⁶

The other condition where gas under right diaphragm is found are right subphrenic abscess and Chiladiti syndrome the latter found to be very rare condition among children.

The clinical presentation after perforation of duodenal ulcer may be those of an acute abdomen, but the signs may be masked particularly in the presence of other illness. Among the investigations, plain X-ray of abdomen with free gas under both dome of diaphragm is usually pathognomonic of duodenal perforation. In our case patient with the clinical history and presentation was in accordance to the duodenal ulcer perforation as it was confirmed preoperatively.

There are various surgical procedures for duodenal perforation (laparoscopic/open) like Graham patch repair, truncal vagotomy, drainage procedure and hemigastrectomy.⁴ In the present case classical Graham patch repair was done.

In summary duodenal ulcer perforation is rare in pediatric population.

REFERENCES

1. Tam YH, Lee KH, To KF, Chan KW, Cheung ST. Helicobacter pylori-positive versus Helicobacter pylori-negative idiopathic peptic ulcers in children with their long-term outcomes. *Journal of pediatric gastroenterology and nutrition*. 2009 Mar 1;48(3):299-305.
2. Deckelbaum RJ, Roy CC, Lussier-Lazaroff J, Morin CL. Peptic ulcer disease: a clinical study in 73 children. *Can Med Assoc J* 1974;111:225-8.
3. Hua MC, Kong MS, Lai MW, Luo CC. Perforated peptic ulcer in children: a 20-year experience. *J Pediatr Gastroenterol Nutr* 2007;45:71-4.
4. Kadian YS, Rattan KN, Malik A. Perforated duodenal ulcer a rare cause of acute abdomen in infancy: A report of two cases. *African Journal of Paediatric Surgery*. 2008 Jan 1;5(1):46-7.
5. Maudar KK, Dutta J, Mitra S. Duodenal ulcer disease in children. *World J Surg* 1980;4:261-5.
6. Torres J, Perez PG, Goodman KJ. A comprehensive review of the natural history of helicobacter pylori infection in children. *Arch Med Res* 2000;31:431-69.

Cite this article as: Rai B K, Alam MDS, Sah C, Yadav A P. Duodenal ulcer perforation in paediatric population; A rare entity. *Medphoenix*, 2020;5(1): 79-81