



## Research Article

# Therapeutic Role of Gastrograffin In Adhesive Small Bowel Obstruction After Unsuccessful Conservative Treatment

Alam MD Shahid<sup>1\*</sup>, Bhatta Pashupati<sup>1</sup>, Raya Akash<sup>1</sup>, Rai Binod Kumar<sup>1</sup>

<sup>1</sup>Department of General Surgery, National Medical College, Birgunj, Parsa, Nepal.

**Date of Submission:** Feb 09, 2020

**Received in Revised Form:** March 21, 2020

**Date of Acceptance:** April 03, 2020

**Date of Publishing:** July 30, 2020

### ABSTRACT

**Background:** The management of adhesive small bowel obstruction is quite debatable. Gastrograffin, a water-soluble hyperosmolar contrast is used as a diagnostic tool widely but it also has impressive therapeutic role. Hence this study was to determine its therapeutic role in management of adhesive bowel obstruction after failure of conservative treatment.

**Methods:** This cross-section observational study of 42 patients was conducted in 1-year duration from 01 July 2018 to 30 June 2019 using non-probability purposive sampling technique. All the patients were first managed conservatively for 48 hrs, and then given 100ml of gastrograffin through NG tube and clamped. Appearance of dye in cecum on radiograph at different time frame (4, 8, 12 and 24 hours of administration) signifies the success and who failed to do so within 24 hrs. were planned for laparotomy.

**Results:** A total of 42 patients with their age ranged 14-80 years (mean 44.6) were

included. Among them 32(76.19%) were male and 10(23.80%) female. Most had open appendectomy followed by gynaecological surgery and exploratory laprotomy. Majority had midline incision followed by gridiron and pfanensteil incision. After 8 hrs of gastrograffin administration, it was positive in 12 patients while 19 had at 24 hrs. Total 31 patients showed complete resolution, while remaining 11 showed no improvement and undergone exploratory laparotomy.

**Conclusion:** Thus, the administration of gastrograffin is an effective approach in the management of adhesive small bowel obstruction after failed conservative management and prevents surgeries.

**Key words:** Adhesive bowel obstruction, Conservative treatment, Gastrograffin.

**\*Corresponding Author:** Dr. MD Shahid Alam, Lecturer, Department of General Surgery, NMCTH, Birgunj, Nepal, Mob No: 9804280091, Email: shahidalam10143@gmail.com.

## INTRODUCTION

The most common cause of intestinal obstruction is post-operative adhesions (6-30%)<sup>1</sup> and proved to be the major cause of post-operative morbidity. Gynaecological surgery and appendectomy are the most common cause of post-operative adhesions.<sup>2</sup> Conservative management of these patients without the features of strangulation is adapted to be the widespread treatment strategy. Most of the patients improve with this management but rest of the patient undergoes operative management. However, this approach leads to the delayed in operative treatment hence leads to increase in mortality (3-5% for simple obstruction and 30% in case of strangulation).<sup>3</sup>

Gastrograffin is a water-soluble contrast agent, hyperosmolar, radio-opaque composed of mixture of sodium diatrizoate & meglumine diatrizoate with an osmolarity of 1900 mosm/l. Its diagnostic property has well been proven to be highly effective in diagnosing the level of obstruction and planning the need for surgery. However, its therapeutic role has recently been proven and has impressive role in resolution of the symptoms and decreasing the need for surgery. Furthermore, it also reduces the unnecessary delay in planning for surgery.<sup>3</sup>

Gastrograffin, a hyperosmolar agent increases the osmotic gradient in the lumen of intestine which makes the fluid shift into the lumen, thus increasing the pressure gradient across the site of obstruction and results in release of obstruction. It also reduces the edema of the gut and increase the contractility of smooth muscle fiber hence increases the peristalsis.<sup>4,5</sup>

Thus, this study is to use this property of the contrast agent and determine its therapeutic role in management of adhesive small bowel

obstruction after failure of conservative management and also prevent from undergoing non therapeutic laprotomy and its complications.

## METHODOLOGY

This study was conducted on 42 patients in surgical wards of National medical college and teaching hospital in 1-year duration from 01 July 2018 to 30 June 2019. It was a cross-sectional observational study by design and patient selection was non probability purposive sampling. All patients both male and female of age 14-80 years who had previously undergone surgery and presented to our department with the feature of intestinal obstruction (abdominal distension, absolute constipation, vomiting, multiple air fluid level in abdominal x-ray erect position) were included in the study and those patients with the sign of strangulation, other causes of obstruction apart from post-operative adhesions (like hernia, stricture, volvulus, foreign body, trichobezoar, phytobezoar etc.), patient with abdominal malignancy, inflammatory bowel diseases, radiation to abdomen were not included in the study.

The detailed history and examination of patients were performed and abdominal x-ray erect and supine, chest x-ray including both dome of diaphragm, routine blood investigation (CBC, RFT's, serum electrolytes, blood sugar, serology) were done. Previous history of surgery was taken (type, incision scar, duration, any wound complications like SSI, burst abdomen). Patient was diagnosed as adhesive small bowel obstruction excluding any symptoms of strangulation and kept under conservative management. Nasogastric tube, Foley's catheterization was done. Fluid and electrolyte balance, intake output chart, abdominal girth monitoring, bowel movements

etc were recorded and observed 4 hours for any improvement. Patient was considered to be improving when distension reduces, pain decreases, decrease in nasogastric output, passed flatus/ feces, x-ray showed decrease in the number of air fluid level, and reduction in the diameter of bowel as compared to previous x-rays. The patients who did not improve after conservative management for 48 hours were then subjected for gastrograffin study after excluding any sign of strangulation.<sup>6,7,8</sup>

After obtaining an informed consent, gastric contents were aspirated and 100 ml of gastrograffin (sodium diatrizoate & meglumine diatrizoate with an osmolarity of 1900mosm/l) was administered through the nasogastric tube and clamped. Patient was kept in sitting position for some time and watched for any vomiting. Abdominal x-ray was taken at the interval of 4, 8, 12, and 24 hours to see the presence of dye in cecum. Presence of dye in cecum signifies that the obstruction has been relieved.<sup>9</sup> Patients who failed to have dye in cecum even after 24 hours were suspected to have complete obstruction and sent for exploratory laparotomy. The patients who responded to gastrograffin subsequently had their nasogastric tube removed and started sips to liquid followed by normal diet and then discharged.

## RESULT

A total of 42 patients with adhesive small bowel obstruction which did not resolve after conservative management without the feature of strangulation were enrolled in the study after informed consent. Among them 32 were male (76.19%) and 10 (23.80%) female. Age ranged from 14 to 80 years with the mean age of 44.6 years. Overall median hospital stay was 6 days. In those patients who responded to gastrograffin, the median stay was only 4

days while that in an operated patient it was 13.4 days. (Table: 1)

All those patients had previous surgery among which majority had open appendectomy (40.47%, 17 patients) followed by gynaecological surgery (caesarean section and total abdominal hysterectomy) (28.57%, 12 patients) and exploratory laparotomy for duodenal ulcer perforation (19.04%, 8 patients), resection and anastomosis for ileal perforation (4.76%, 2 patients), traumatic abdominal injury (4.76%, 2 patients) and stoma reversal (2.4%, 1 patient). (Figure: 1)

On the basis of previous surgical scar marks, majority of the patient had midline incision (47.61%, 20 patients) followed by gridiron incision (28.57%, 12 patients) and pfannenstiel incision (23.80%, 10 patients). Among them 3(7.14%) of the patients had re-exploration previously and 5(11.90%) had surgical site infection. (Figure: 2)

After gastrograffin insertion through NG tube, the test was positive in 12 patients (28.57%) after 8 hr, 14 patients (33.33%) after 12 hrs and 5 patients (11.90%) after 24 hr. Total of 31 patients (73.80%) responded to gastrograffin and exploratory laparotomy was planned and performed in 11 patients (26.19%). Among which 9 (81.81%) had only single band and 2 (18.18%) had adhesions with bands who required resection and anastomosis. (Figure: 3)

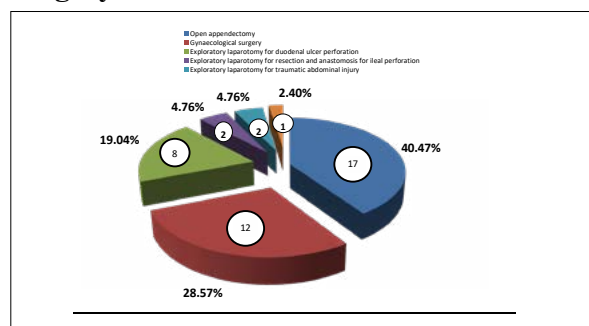
Resolution of sign and symptoms after administration of gastrograffin started with resolution of abdominal pain whose mean duration was 20.38 hrs followed by passage of flatus whose mean duration was 34.56 hrs and then passage of feces whose mean duration was 50.04 hrs. Mean duration of initiation of

oral feeding was 70.48 hrs (Table 2)

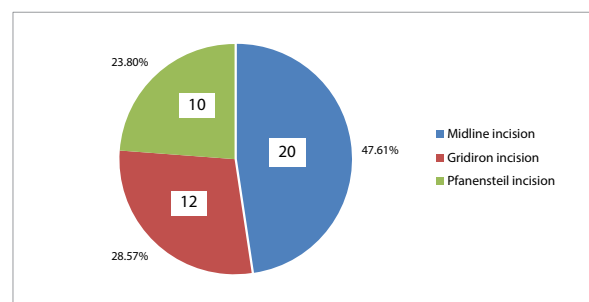
**Table 1: Frequency and percentage and total hospital stay of the patient**

Age (mean)	44.6(14-80 years)
<b>Gender</b>	
Male / Female	32(76.19%) / 10(23.80%)
<b>Total hospital stay (days)</b>	
Total patient (median)	6
Non-operative patient	4
Operative patient	13.4

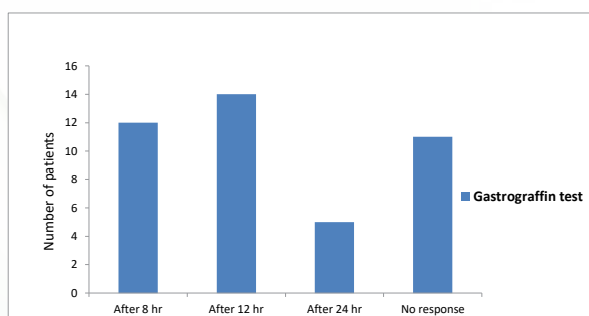
**Figure: 1 Patient distribution on previous surgery**



**Figure: 2 Distribution of patients based on previous surgical scar marks**



**Figure: 3 Gastrografin test at different time frame**



**Table 2: Mean duration of resolution of signs and symptoms after gastrografin administration**

Sign and symptom	Mean Duration
Resolution of abdominal pain	20.38 Hrs
Passage of flatus	34.56 Hrs
Passage of feces	50.04 Hrs
Initiation of oral feeding	70.48 Hrs

**DISCUSSION**

Adhesive small bowel obstructions are mostly seen in the patients who had undergone abdominal surgeries of any type. Most of the studies reported that appendectomy and gynecological surgeries to be the most common cause. The management of adhesive obstruction has remained controversial. Initially the management starts with the trial of conservative management provided that the suspicion of strangulation has been excluded. However, the optimal duration of conservative management is not clear which creates an unnecessary delay leading to poor outcome of the patient. It has been observed that 88% of the patients who undergoes conservative management have their obstruction relieved within 48 hours.<sup>6</sup> It has been recommended that, the patient in whom, the obstruction is not resolved after 48 hours of conservative management should undergo surgery.<sup>7</sup> Non operative management for adhesive bowel obstruction should be limited only for 24 to 48 hours as stated by Sosa and Gardner.<sup>8</sup> In our study patients were kept on conservative management not more than 48 hours.

In our study appendectomy and gynecological surgery is found to be the common cause of adhesive bowel obstruction (69%). Appendectomy and colorectal surgery was found to be the most common cause of adhesive small bowel obstruction in different studies.<sup>3,4,11</sup> Also obstetrics and

gynaecological surgery contributes 31.5 %, appendectomy and colorectal surgery 23% according to study conducted by Solomone et al.<sup>12</sup> Similarly appendectomy is considered to be the commonest preceding surgery (34.3%) by Vakil et al as compared to our study (40.47%).<sup>13</sup>

In our study, most of the patients were male (76.19%) which was similar to that observed in India (64%) and Saudi Arabia (65.7%).<sup>14,15</sup>

Positive gastrograffin test was seen in 73.8% of the patients which is slightly lower than other studies where success rate ranged from 80 to 90%.<sup>12,15,16,17</sup> All our positive gastrograffin patients responded well with conservative management without undergoing surgery. The resolution of clinical sign and symptoms after administration of gastrograffin in our study is similar to other studies.<sup>10</sup>

The reported operative rate for adhesive small bowel obstruction ranges from 27% to 42% which is comparable with our study.<sup>6,17</sup>

## CONCLUSION

Use of oral water-soluble contrast medium (gastrograffin) in selected group of patients with adhesive small bowel obstruction leads to its resolution avoiding surgery. Hence, this strategy should be considered as a safe and effective approach in the management of acute intestinal obstruction due to post-operative adhesions.

## REFERENCES

1. Farid M, Fikry A, Nakeeb AE, Fouda E, Elmetwally T, Yousaf M, et al. Clinical impacts of gastrograffin followthrough in adhesive small bowel obstruction. *J Surg Res.* 2009;1-7.
2. Abbas S, Bisset IP, Parry BR. Meta-analysis of oral water-soluble contrast agent in the management of adhesive small bowel obstruction. *Br J Surg.* 2007; 94:404.
3. Scwabas GM, Sarosi GA, Khan S, Michael G, Sarr MG, Behrns KE. Small bowel obstruction. In: Zinner MJ, Ashley SW, editors. *Maingot's abdominal operations.* New York: McGraw Hill Professional; 2013. pp. 585-610.
4. Assalia A, Schein M, Kopleman D, Hirshberg A, Hashmonai M. Therapeutic effects of oral gastrograffin in adhesive, partial small bowel obstruction: a prospective randomized trial. *Surg.* 1994;115: 433-437.
5. Chen SC, Chang KJ, Lee PH, Wang SM, Chen KM, Lin FY. Oral urograffin in postoperative small bowel obstruction. *World J Surg.* 1999; 23:1051-1054.
6. Cox MR, Gunn IF, Eastman MC, et al. The safety and duration of non-operative treatment for adhesive small bowel obstruction. *Aust NZ J Surg* 1993; 63:367-371.
7. Assalia A, Schein M, Kopleman D, et al. Therapeutic effect of oral Gastrograffin in adhesive, partial small-bowel obstruction: A prospective randomized trial. *Surgery* 1994; 115:433-437.
8. Sosa J, Gardner B. Management of patients diagnosed as acute intestinal obstruction secondary to adhesions. *Am Surg* 1993; 59:125-128.
9. Burge J, Abbas SM, Roadley G, Donald J, Connolly A, Bissett IP, et al. Randomized controlled trial of Gastrograffin in adhesive small bowel obstruction. *ANZ J Surg* 2005; 75:672-4.
10. Haule C, Ongom PA, Kimuli T. Efficacy of Gastrograffin® Compared with Standard Conservative Treatment in Management of Adhesive Small Bowel



- Obstruction at Mulago National Referral Hospital. *J Clin Trials* 2013;3(4).
11. Choi HK, Law WL, Chu KW. Therapeutic value of gastrografin in adhesive bowel obstruction after unsuccessful conservative treatment: a prospective randomized trial. *Ann Surg.* 2002; 236:1-4.
  12. Di Saverio S, Catena F, Ansaloni L, Gavioli M, Valentino M, Pinna AD. Water-soluble contrast medium (gastrografin) value in adhesive small intestine obstruction (ASIO): A prospective, randomized, controlled, clinical trial. *World J Surg* 2008; 32:2293-304.
  13. Vakil R, Kalra S, Raul S, Paljor Y, Joseph S (2007) Role of water-soluble contrast study in adhesive small bowel obstruction: a randomised controlled study. *Indian J Surg* 69: 47-51.
  14. Rahmani N, Mohammadpour RA, Khoshnood P, Ahmadi A, Assadpour S. Prospective evaluation of oral gastrografin(®) in the management of postoperative adhesive small bowel obstruction. *Indian J Surg* 2013; 75:195-9.
  15. Al Salamah SM, Fahim F, Mirza SM. Value of water-soluble contrast (meglumine amidotrizoate) in the diagnosis and management of small bowel obstruction. *World J Surg* 2006; 30:1290-4.
  16. Roadley G, Cranshaw I, Young M, Hill AG. Role of Gastrografin in assigning patient to a non-operative course in adhesive small bowel obstruction. *ANZ J Surg* 2004; 74:830-2.
  17. Srinivasa S, Thakore N, Abbas S, Mahmood M, Kahokehr AA, Hill AG. Impact of gastrografin in clinical practice in the management of adhesive small bowel obstruction. *Can J Surg* 2011; 54:123-7.

Cite this article as: Alam MDS, Bhatta P, Raya A, Rai BK. Therapeutic role of gastrografin in adhesive small bowel obstruction after unsuccessful conservative treatment. *Medphoenix*, 2020;5(1): 26-31