

# Immediate Implant Placement and Immediate Loading in the Aesthetic Zone: A Flapless Approach

Dr. Savvy Pokhrel,<sup>1</sup> Dr. Bhageshwar Dhama,<sup>1</sup> Dr. Shristi Poudel<sup>1</sup>

<sup>1</sup>Department of Periodontology and Oral Implantology, Kantipur Dental College and Hospital, Basundhara, Kathmandu, Nepal.

## ABSTRACT

Replacing missing or failing teeth with implants can be a clinical challenge, especially in the aesthetic area, because patients expect an esthetically ideal prosthesis besides the osseointegration of implants. In this regard, immediate placement of implants with immediate loading is preferred by the patients, for the fewer surgeries involved and the immediate restoration of the potential edentulous sites. This article aims to present a case report of immediate placement of implant and immediate loading of the maxillary right lateral incisor.

**Keywords:** Immediate implant; immediate loading; missing teeth.

## INTRODUCTION

Although multi-step traditional implant placement protocols provide long-term stability, especially in imperiled situations with reference to general health, bone support or local inflammation, they require long healing time, provisional phase with an oftentimes inadequate implant prosthesis, and multiple surgeries. Moreover, with the thorough understanding of dimensional ridge alterations following extraction, implant placement into healed sites has completely lost its dominance, particularly in the case of single tooth replacement.<sup>1</sup> In contrary, Considerably reduced treatment time, fewer surgeries, and immediate aesthetic rehabilitation, the key advantages of immediate implant protocols, have rendered immediate implant placement and immediate loading an attractive protocol from a patient perspective.<sup>2,3</sup>

## CASE REPORT

A 43-year-old female patient presented to the

Department of Periodontology and Oral Implantology with the chief complaint of spacing in the upper front region of the jaw which had progressed over time, along with loosening of the tooth adjacent to the space. No significant medical, dental or habit history was reported. Clinical examination revealed extrusion and Grade II mobility of the maxillary right lateral incisor, along with spacing mesial to it. (Figure 1)

Radiographic examination revealed bone loss with respect to 12 and 11, and periapical radiolucency in 12. Cone Beam Computed Tomography (CBCT) was further performed on the patient, which additionally gave out extensive bone loss and periapical radiolucency with respect to 12, in sagittal plane view. (Figure 2)

The CBCT analysis showed more than 50% bone loss on both the facial and lingual aspects of 12 as well as significant widening of the periodontal ligament space. Following thorough clinical and radiographic evaluation, as well as in view of aesthetic interest of the patient, extraction of 12 was planned followed by replacement with an implant supported prosthesis. Distance from the socket to nasal floor, faciopalatal bone width, buccal bone thickness, palatal bone thickness, and mesiodistal bone width were 11.1 mm, 7.3 mm, 1 mm, 1.1 mm, and 6.7 mm respectively. (Figure 3A, Figure 3B) The angulation of tooth, remaining alveolar bone support, and bone density

### Correspondence

Dr. Savvy Pokharel

Email: pokharelsavvy@gmail.com



### Citation

Pokharel S, Dhama B, Paudel S. Immediate Implant Placement and Immediate Loading in the Aesthetic Zone: A flapless Approach. J Nepal Soc Perio Oral Implantol. 2023 Jul-Dec;7(14):90-4.

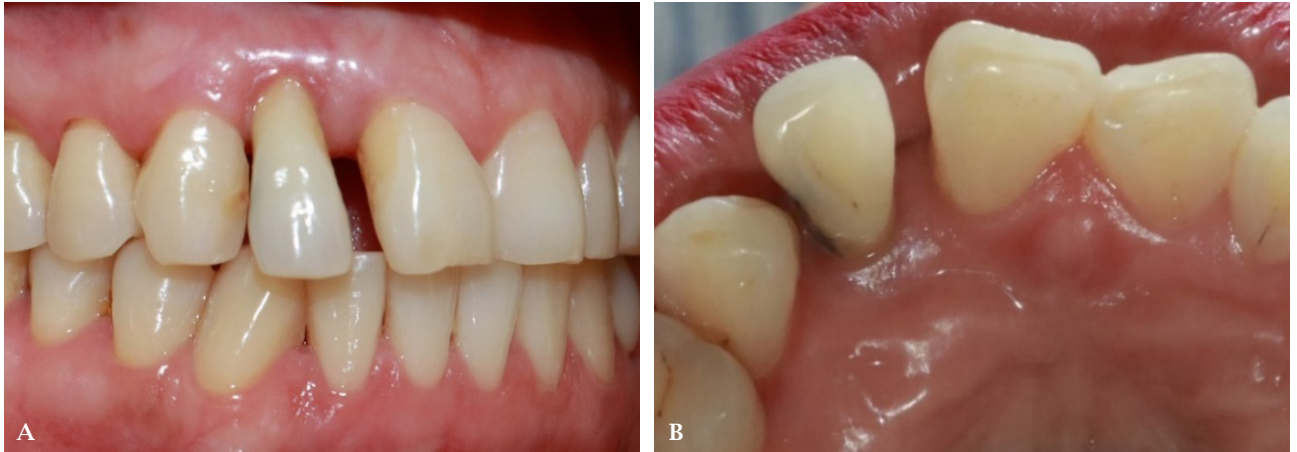

Figure 1: Pre-operative clinical photographs showing A) Right lateral view, B) Palatal view.

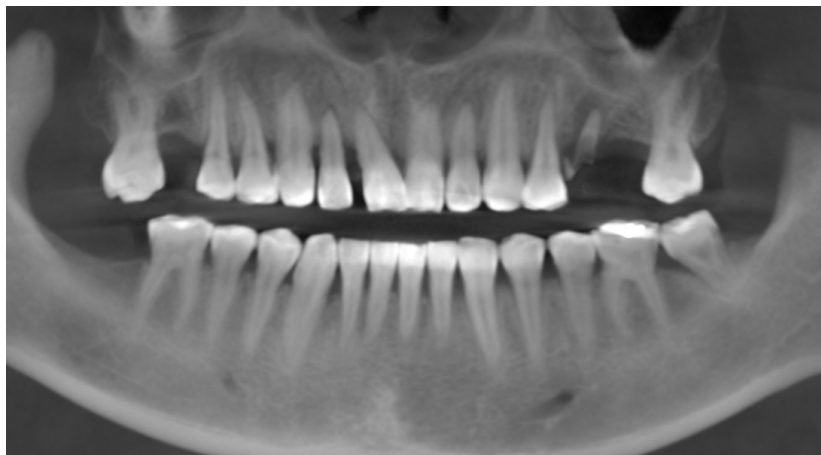

Figure 2: Cone beam computed tomography scan showing orthopantomographic view.

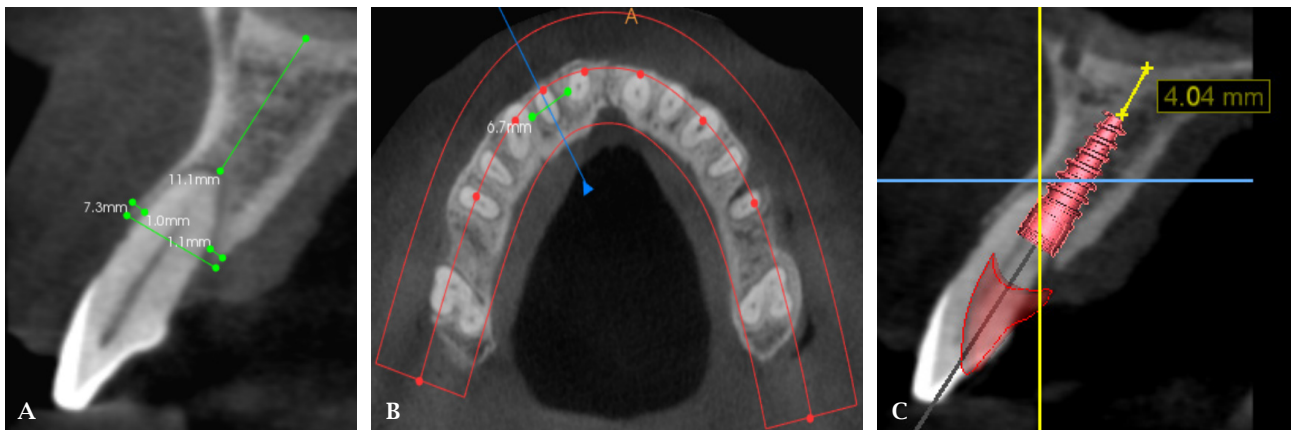
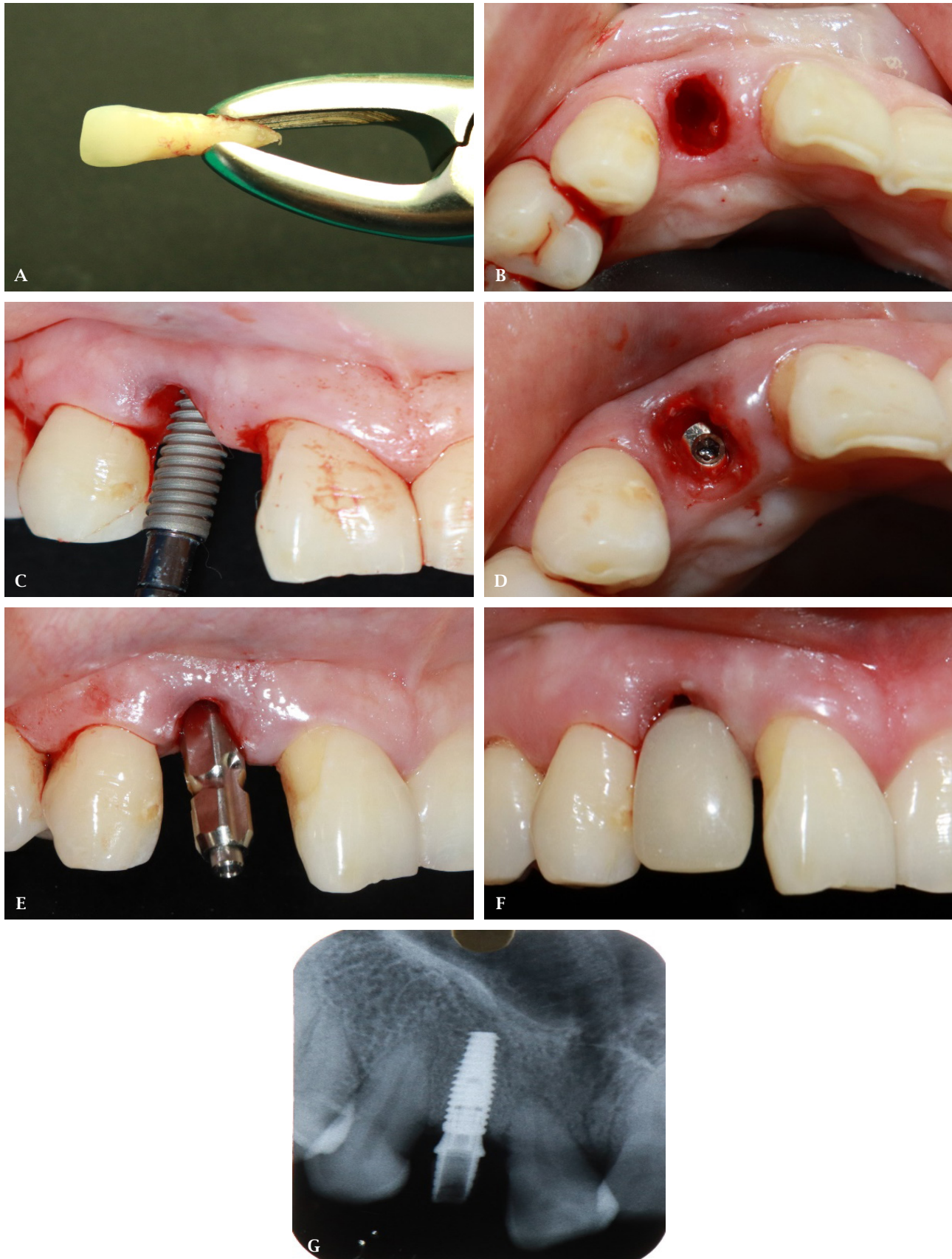


Figure 3: A, B) Evaluation of alveolar bone support. C) 3.5x11.5 mm implant.

assessed on the CBCT scan favoured the immediate implant placement protocol. A 3.5x11.5 mm implant was planned using the implant planning software (BlueSky plan). (Figure 3C)

After evaluation of coagulation profile, blood glucose level and blood pressure of the patient, written consent was taken. The surgical procedure

was performed in aseptic conditions under local anaesthesia (Infiltration with 2% Lidocaine with 1:200000 Epinephrine). Tooth was gently extracted without raising a flap, therefore causing minimal trauma to soft tissues. (Figure 4A) Degranulation of the socket was done with copious saline irrigation. (Figure 4B) Following sequential drilling, a 3.5x11.5 mm i-Fix® implant was placed into the osteotomy

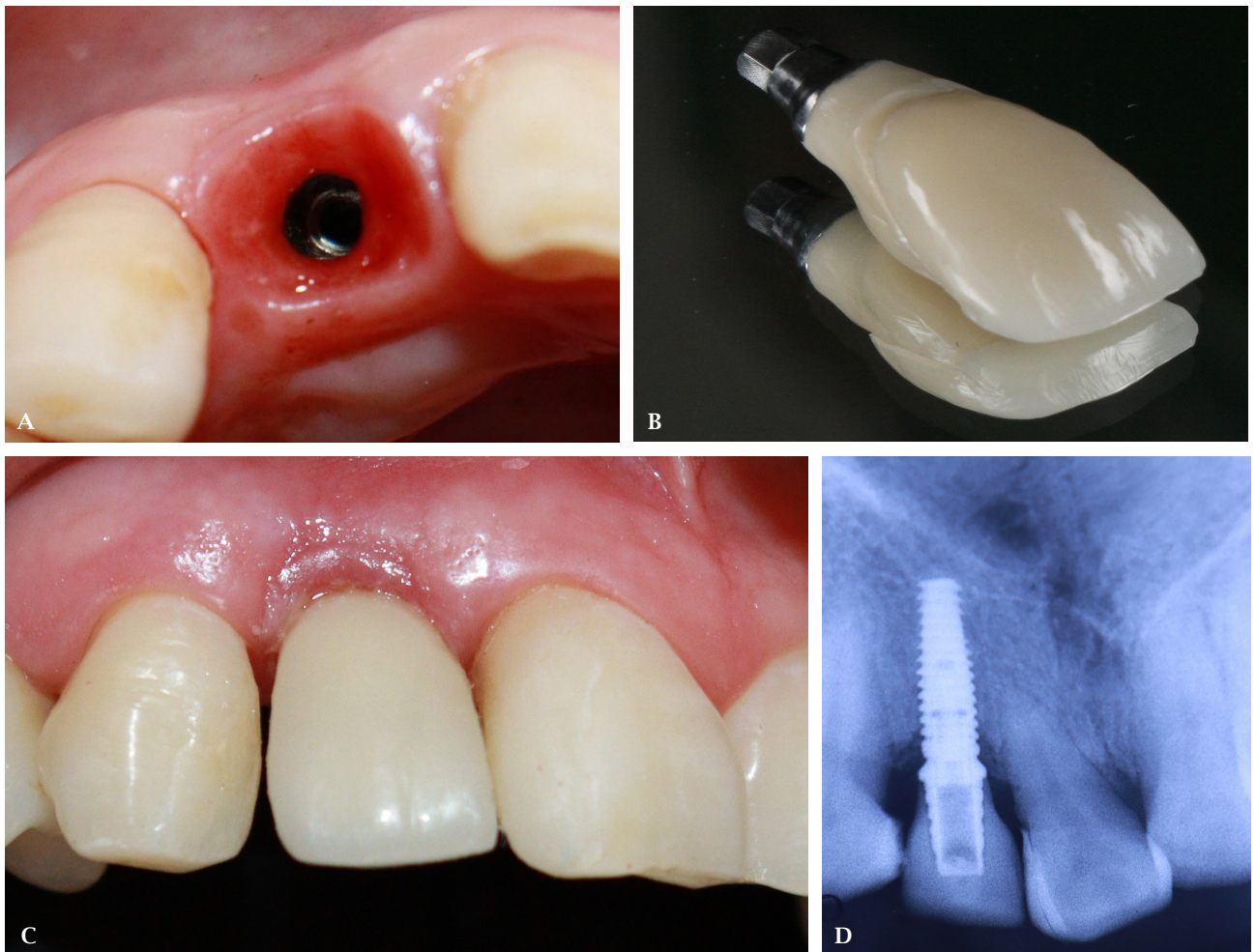


**Figure 4: A) Extracted tooth i.r.t. 12. B) Extraction socket. C) 3.5×11.5 Implant placement into osteotomy site. D) Fixture placed into the osteotomy site., E) Impression coping to make impression for temporary prosthesis. F) Temporary acrylic resin prosthesis. G) Radiograph of implant with temporary prosthesis.**

site. (Figure 4C, Figure 4D) Greater than 35 Ncm was obtained. Xenograft was placed to fill the gap between the implant and buccal bone. Since this was a flapless approach, no sutures were required. Impression was made with Putty and Light body impression materials and an acrylic temporary crown was delivered on the day of surgery. (Figure 4E, Figure 4F) Amoxicillin and Clavulanic acid combination 625 mg 8 hourly for 7 days, Serratiopeptidase 10 mg 6 hourly for 5 days, Paracetamol and Ibuprofen combination 8 hourly for 3 days followed by intake if necessary and 0.2% Chlorhexidine mouthwash for 2 weeks, were prescribed to the patient, with instructions on the proper oral hygiene and maintenance of the surgical site. Patient was assessed after one week, and kept on scheduled follow-up visits.

After three months, composite build-up was done in the distal aspect of 11 and implant-level impression of the maxillary arch was made with Putty and Light body impression materials using closed tray technique, for the fabrication of final prosthesis. An indirect composite (Ceramage) crown was fabricated and delivered to the patient. (Figure 5B, Figure 5C) The patient was satisfied with the aesthetics and function of the implant-supported prosthesis.

The patient was seen again at one year and two months. Clinical and radiographic evaluation, as well as oral prophylaxis were performed. (Figure 6A, Figure 6B) The patient was advised for future follow-ups.



**Figure 5: A) Peri-implant mucosa at 3 months. B) Prosthesis fabricated with Indirect Composite (Ceramage). C) Final prosthesis i.r.t. 12. D) Radiograph of implant with final prosthesis.**

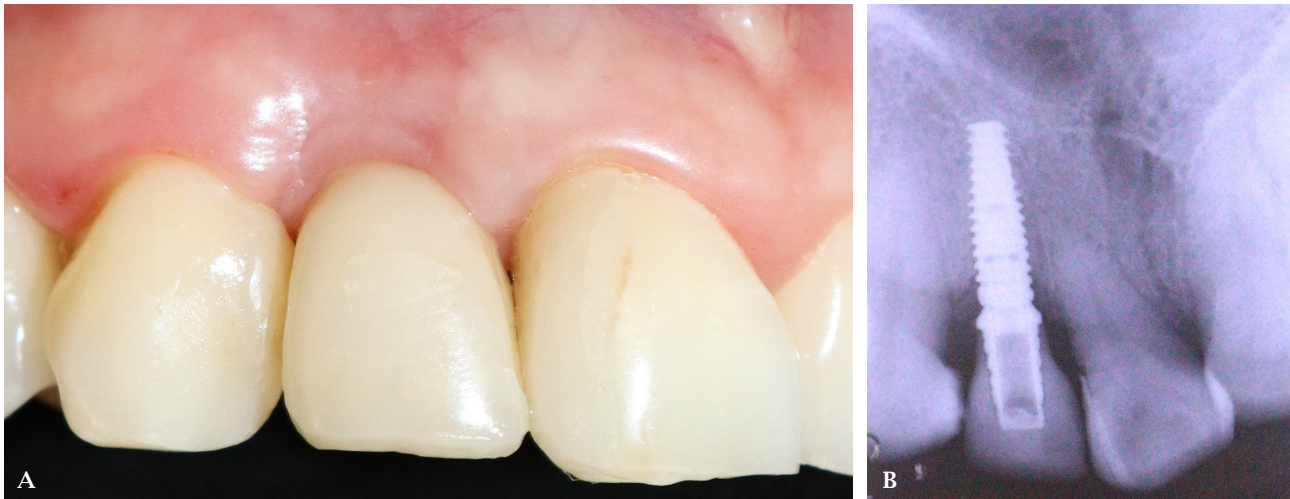

Figure 6: A) Fourteen months follow-up. B) Radiograph at 14 months.

## DISCUSSION

Thorough understanding of the dimensional ridge alterations following tooth extraction, has prioritized the immediate implant placement, particularly in the case of single tooth replacement.<sup>1</sup> From a biologic point of view, the main advantage of the flapless approach lies in the preservation of periosteum and supraperiosteal plexus, thereby maintaining the blood supply to the alveolar bone and ultimately preventing the marginal bone loss.<sup>4</sup> Vergara and Caffesse suggested that immediate implant placement with a flapless approach in the maxillary anterior teeth maintained the soft tissue architecture and minimized the alveolar bone alterations.<sup>5</sup>

Placing bone grafts into the void between the implant surface and socket walls, after immediate implant placement, has shown to preserve, at least in part, the

alveolar ridge dimensions. The advantages of such grafting are more evident in the anterior maxilla, where the majority of patients have a thin buccal bone plate i.e.  $\leq 1$  mm.<sup>8,9</sup> Moreover, a computed tomographic study by Nevins et al. has reported loss of less than 20% of buccal plate in sockets treated with deproteinized bone graft (Bio-Oss) as compared to the sites that were not grafted.<sup>10</sup>

Immediate loading is determined by the primary stability assessed via the insertion torque values. Insertion torque  $> 25$  Ncm is proposed if accelerated loading protocols are utilized.<sup>6</sup> Tortamano et al. has reported stability of the peri-implant soft tissue over 18-month period with immediate implant and provisional restoration in the aesthetic zone.<sup>7</sup>

**Conflict of Interest:** None.

## REFERENCES

1. Buser D, Chappuis V, Belser UC, Chen S. Implant placement post extraction in esthetic single tooth sites: when immediate, when early, when late? *Periodontol 2000*. 2017 Feb;73(1):84-102.
2. Gamborena I, Sasaki Y, Blatz MB. Predictable immediate implant placement and restoration in the esthetic zone. *J Esthet Restor Dent*. 2021;33(1):158-72.
3. Araújo MG, Silva CO, Souza AB, Sukekava F. Socket healing with and without immediate implant placement. *Periodontol 2000*. 2019;79(1):168-77.
4. Kan JYK, Rungcharassaeng K, Deflorian M, Weinstein T, Wang HL, Testori T. Immediate implant placement and provisionalization of maxillary anterior single implants. *Periodontol 2000*. 2018;77(1):197-212.
5. Vergara JA, Caffesse RG. Preservation of Esthetics with Implant Dentistry: a Clinical Report. *Clin Implant Dent Rel Res*. 2002 Dec;4(4):200-11.
6. Morton D, Pollini A. Evolution of loading protocols in implant dentistry for partially dentate arches. *Periodontol 2000*. 2017;73(1):152-77.
7. Tortamano P, Camargo LOA, Bello-Silva MS, Kanashiro LH. Immediate implant placement and restoration in the esthetic zone: a prospective study with 18 months of follow-up. *Int J Oral Maxillofac Implants*. 2010;25(2):345-50.
8. Liñares A, Dopico J, Magrin G, Blanco J. Critical review on bone grafting during immediate implant placement. *Periodontol 2000*. 2023 Oct 1;93(1):309-26.
9. Rijal AH, Dhami B, Ghimire P, Humagain M, Lamichhane S. Early Implant Placement with Immediate Loading in the Mandibular Anterior Region: A Rapid Solution to Edentulism. *Case Reports in Dentistry*. 2023 Dec 18;2023.
10. Nevins M, Camelo M, De Paoli S, Friedland B, Schenk RK, Parma-Benfenati S, et al. A study of the fate of the buccal wall of extraction sockets of teeth with prominent roots. *Int J Periodontics Restorative Dent*. 2006 Feb;26(1):19-29.