

Minimal Intervention Approach for Complicated Crown- root Fracture using Reattachment procedure: Three Years Follow-up

Dr. Sita Shrestha,¹ Dr. Mannu Vikram,² Dr. Ripu Singh,³ Dr. Shikha Bantawa⁴

¹Conservative Dentist and Endodontist;

²Department of Conservative Dentistry and Endodontics, B.P Koirala Institute of Health Sciences, Dharan, Sunsari, Nepal;

³Department of Periodontology and Oral Implantology, Kist Medical College, Imadol, Lalitpur, Nepal;

⁴Department of Dentistry, National Academy of Medical Science, Bir Hospital, Kathmandu, Nepal.

ABSTRACT

Crown-root fractures are commonly encountered in dental practice, and their management poses a challenge to clinicians. With the advent in adhesive dentistry, reattachment of the fractured segment became a viable restorative alternative. Reattachment is a conservative treatment option that allows for immediate restoration of function, esthetics and phonetics. This case report presents a minimal intervention approach to the management of a complicated crown root fracture. The tooth was endodontically treated followed by esthetic reattachment of the fractured fragment using composite fiber post. The patient was followed up for three years, and clinical and radiographic examinations showed a successful treatment outcome.

Keywords: Complicated crown root fracture; dental trauma; fiber post; tooth reattachment.

INTRODUCTION

Traumatic dental injuries are a common dental health problem resulting in damage to dental and peri-radicular structures that lead to esthetic, functional and psychological problems affecting quality of life.¹ The teeth most susceptible to traumatic injuries are maxillary incisors, forming 96% of all crown fractures.² Complicated crown-root fracture is defined as a fracture involving enamel, dentin, cementum and pulp occurring below the gingival margin.¹ This article presents a case of a complicated crown-root fracture of maxillary central incisor managed with reattachment of the fractured segment using dental adhesives and a fiber post, with three years of follow-up.

CASE REPORTS

A 26-year-old male patient came to the Department of Conservative Dentistry and Endodontics after

bike accident and suffering a traumatic injury to the upper front teeth one day back. His medical and dental history was noncontributory. Intra-oral examination revealed a complicated crown root fracture of the maxillary left central incisor (21), uncomplicated crown fracture of the maxillary left lateral incisor (22) and enamel infarction of maxillary right central incisor (11) (Figure 1A, B). The fracture line was oblique extending in apical direction from labial to palatal surface. The fractured segment of 21 (according to two-digit tooth numbering system) was loosely attached to root. Intraoral periapical radiographic investigation showed no evidence of periapical pathosis. Pulp sensibility test using cold and electric pulp test revealed normal response in respect to (irt) 11 and 22.

The adhesive reattachment of the coronal fragment using composite fiber post for 21, and composite restoration of 22 was planned. The patient accepted the treatment plan.

The fractured segment was loosely attached to the gingiva on palatal side. It was atraumatically removed and extension of fracture margin was assessed. In this case, the vertical difference between the alveolar bone crest and the fracture margin was 1 mm (Figure 2). So, the crown lengthening procedure was planned. The coronal fragment was cleaned to remove pulp remnants and was stored in normal physiological

Correspondence

Dr. Sita Shrestha

Email: sitashrestha21@gmail.com



Citation

Shrestha S, Vikram M, Singh R, Bantawa S. Minimal Intervention Approach for Complicated Crown- root Fracture using Reattachment procedure: Three Years Follow-up. J Nepal Soc Perio Oral Implantol. 2023 Jul-Dec;7(14):77-81.

This is an open access journal, and articles are distributed under the terms of the Creative Commons Attribution CC BY 4.0 Licence.

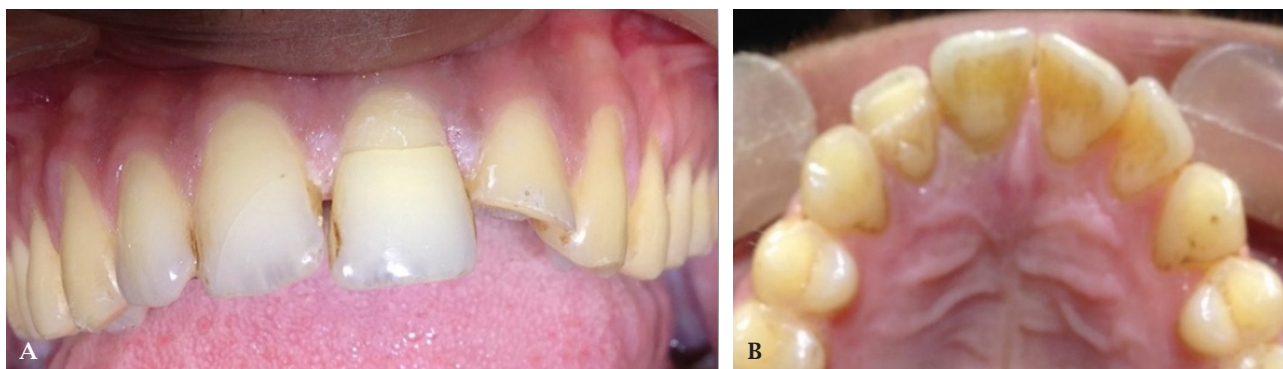


Figure 1: A) Close up view of fractured teeth. B) Palatal view.

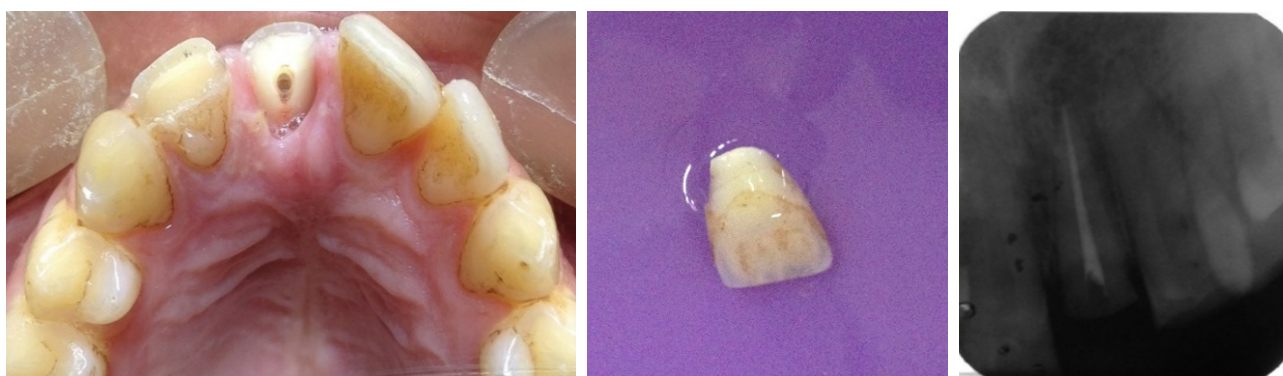

Figure 2: Clinical aspect showing extension the fracture.

Figure 3: Retrieved fractured segment.

Figure 4: Post endodontic treatment radiograph.

saline (Figure 3). Isolation was achieved using cheek retractor, cotton rolls and saliva ejector. Single visit root canal treatment was done with 21 and post space was prepared using Peeso reamers, leaving 5 mm of apical gutta percha (Figure 4). An enamel bevel was prepared all around the remaining tooth structure and the fractured margin of fragment. In the fractured segment internal dentinal groove was prepared to approximate the coronal end of fiber post. A composite fiber post of 1.1 mm diameter was selected. Coronal part of post was cut to fit into coronal fractured segment (Figure 4). Then surgical crown lengthening procedure was started. Palatal gingiva was separated and osteotomy and osteoplasty was done, so that the fracture line stayed at a 2 mm bone margin. Adequate isolation was maintained with the help of cotton pellets (Figure 5). After that, prepared post space was acid etched and bonded. The post was then luted with dual cure resin cement (Multilink, Ivoclar, Vivadent) with 2 mm of its coronal

portion extending into the chamber (Figure 6). The beveled part was restored with composite. The palatal gingiva was sutured. The fractured portion of 22 was provisionally sealed with GIC.

After 7 days, sutures were removed. The palatal gingiva showed adequate approximation and good healing (Figure 7). Pulp sensitivity testing of 11 and 22 using cold and electric pulp test confirmed the vitality of the tooth. 22 was restored with composite (Figure 8) and no treatment was done irt 11. Patient was recalled after 3, 6 and 12 months for follow-up. He was not able to make regular follow-up as he went abroad and reported only after three years. On examination the reattached tooth was clinically and radiographically sound (Figure 9, 10). But there was periapical radiolucency irt 11 and 22. Pulp sensibility testing of 11 and 22 using cold test and electric pulp test elicited no response. Then endodontic treatment was planned irt 11 and 22.

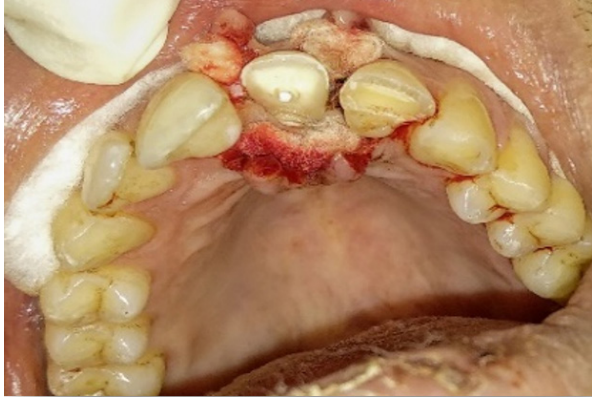


Figure 5: Isolation maintained with cotton pellets.

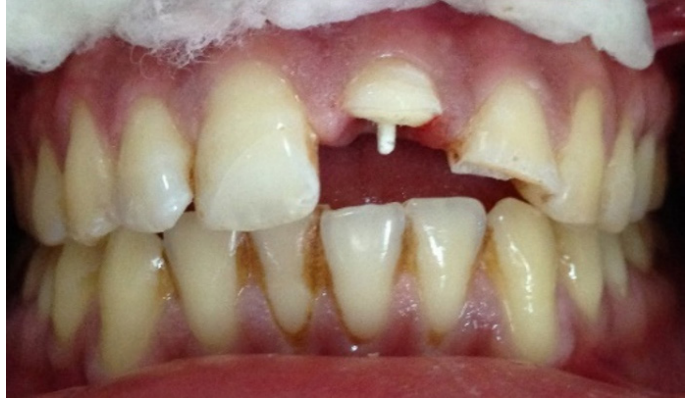

Figure 6: Cementation of fiber post.

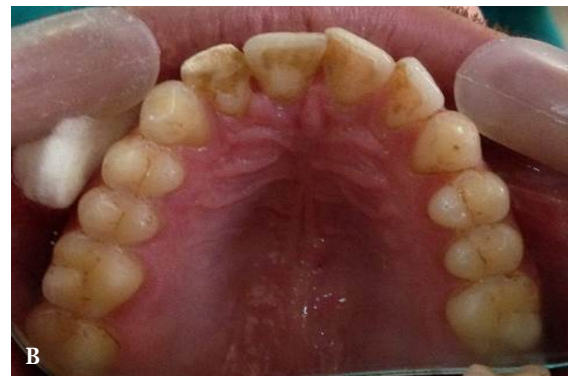
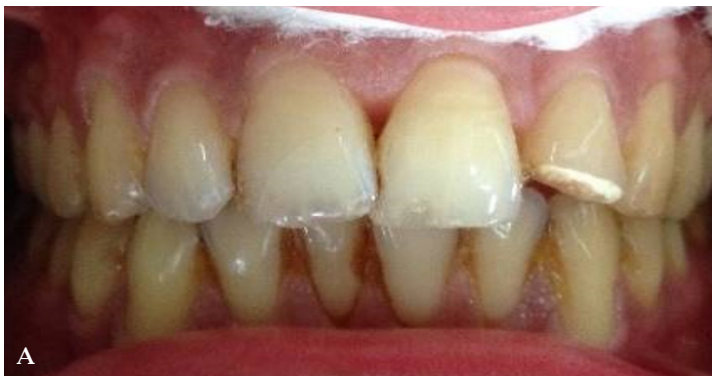
Figure 7: A) and B) Seven days after suture removal.

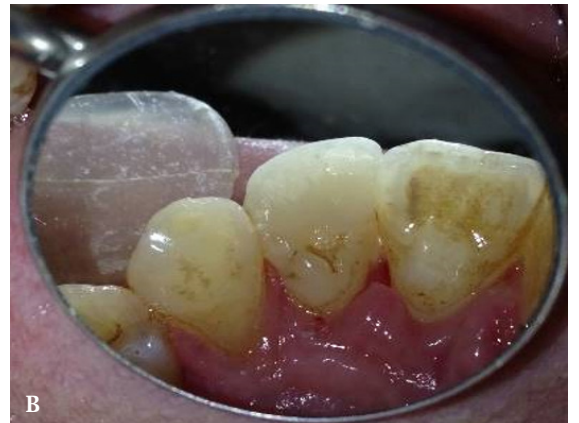
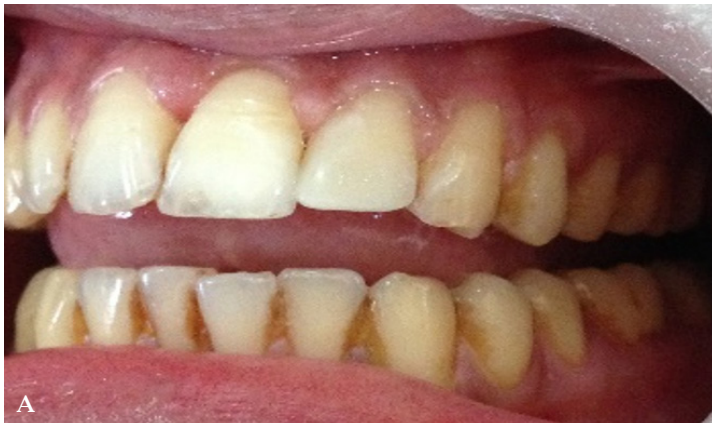
Figure 8: A) and B) Composite restoration of 22.

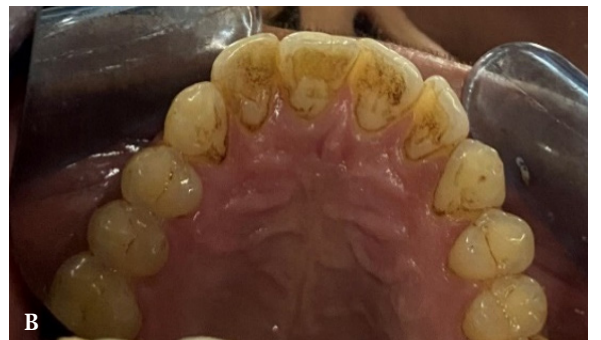
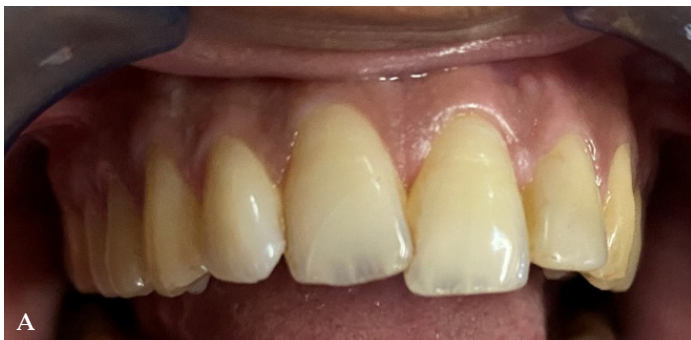
Figure 9: A) and B) Clinical presentation after three years.

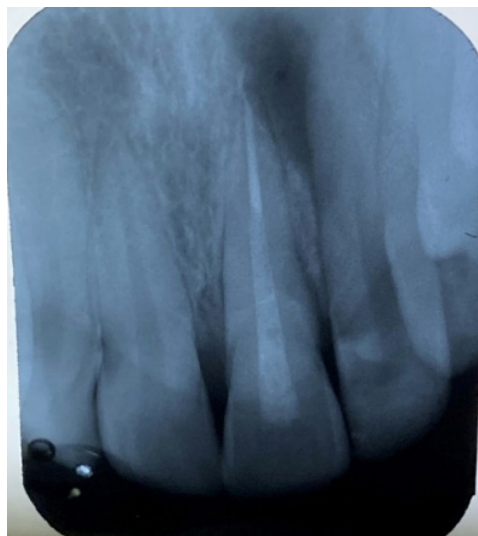


Figure 10: Intraoral periapical radiograph after 3 years.

DISCUSSION

There are various modalities to treat complex crown root fracture such as removal of fractured segment, exposure of subgingival margin, orthodontic or surgical extrusion followed by post and core supported prosthesis or extraction.³ With the availability of newer generation bonding agents, composites and esthetic posts, reattachment of the fractured segment has become reliable treatment modality. This is a “minimal intervention” and “biological restoration concept” which leads to maximum preservation of tooth structure and esthetics.²

Single visit root canal treatment was carried as pulp was vital and periapical radiograph revealed no pathology. Post space was prepared immediately after root canal obturation as there were no differences on apical seal after immediate or delayed post space preparation.⁴ The treatment of complicated crown-root fracture is compromised by subgingival fracture margin which violate biological width and pose difficulty in proper isolation. Clinical crown lengthening surgery is viable method to reinstate biological width and to maintain dry field during reattachment procedure.⁵

Survival rate of reattached tooth, determined by its fracture strength, is the major concern in the view of the success of the treatment.⁶ Reis et al. studied the effect of different reattachment technique on

fracture resistance and found that buccal chamfer, superficial overcountouring and internal groove placement restored 60.6%, 97.2% and 90.5% of intact tooth's fracture resistance respectively.⁷ In this case, internal dentinal groove was prepared to increase fracture resistance of the tooth and circumferential beveling of enamel margins of the tooth as well as fragment was done to increase the retention by an increase in surface area for bonding and to mask the fracture line.

When two-third or more of crown is involved in the fracture, reattachment using post is commonly used. Posts increase retention and distribute stress along the root.⁸ Fibre reinforced post have several advantage over metal posts. They are passive, tooth colored and have modulus of elasticity equal to that of dentin. A modulus of elasticity similar to that of dentin may increase the strength of the remaining tooth structure and reduce the risk of tooth fractures.^{9, 10}

After three years of follow up, reattached tooth was functionally and esthetically sound which indicate the success of the treatment procedure. However, 11 and 22 became nonvital and developed periapical radiolucency which is the most common sequel of traumatic dental injury. This necessitates the importance of regular follow-up in cases of traumatic injuries.

REFERENCES

1. Martins AV, Albuquerque RC, Lanza LD, Vilaça Ê L, Silva N, Moreira AN, et al. Conservative treatment of a complicated crown-root fracture using adhesive fragment reattachment and composite resin restoration: Two year follow-up. *Oper Dent*. 2018;43(3):E102-e9.
 2. Raut AW, Mantri V, Shambharkar VI, Mishra M. Management of complicated crown fracture by reattachment using fiber post: Minimal intervention approach. *J Nat Sci Biol Med*. 2018;9(1):93-6.
 3. Bagis B, Korkmaz YT, Korkmaz FM, Durkan R, Pampu AA. Complicated subgingivally fractured central and lateral incisors: case report. *J Can Dent Assoc*. 2011;77:b145.
 4. Grecca FS, Rosa AR, Gomes MS, Parolo CF, Bemfica JR, Frasca LC, et al. Effect of timing and method of post space preparation on sealing ability of remaining root filling material: in vitro microbiological study. *J Can Dent Assoc*. 2009;75(8):583.
 5. Jagannath-Torvi S, Kala M. Restore the natural - A review and case series report on reattachment. *J Clin Exp Dent*. 2014;6(5):e595-8.
 6. Macedo GV, Diaz PI, De OFCA, Ritter AV. Reattachment of anterior teeth fragments: a conservative approach. *J Esthet Restor Dent*. 2008;20(1):5-18:9-20.
 7. Reis A, Francci C, Loguercio AD, Carrilho MR, Rodriques Filho LE. Re-attachment of anterior fractured teeth: fracture strength using different techniques. *Oper Dent*. 2001;26(3):287-94.
 8. Bosso K, Gonini Júnior A, Guiraldo RD, Berger SB, Lopes MB. Stress generated by customized glass fiber posts and other types by photoelastic analysis. *Braz Dent J*. 2015;26(3):222-7.
 9. Stojanac I, Ramic B, Premovic M, Drobac M, Petrovic L. Crown reattachment with complicated chisel-type fracture using fiber-reinforced post. *Dent Traumatol*. 2013;29(6):479-82.
 10. Rollings S, Stevenson B, Ricketts D. Posts--when it all goes wrong! Part 1: case assessment and management options. *Dent Update*. 2013;40(2):82-4.
-