

## Prosthetic rehabilitation with immediate single complete denture for periodontally compromised maxillary teeth: A case report

Rai A<sup>1</sup>, Subba A<sup>2</sup>, Suwal P<sup>3</sup>, Parajuli PK<sup>4</sup>, Limbu IK<sup>5</sup>, Basnet BB<sup>5</sup>

<sup>1</sup>Senior Resident, Department of Prosthodontics, College of Dental Surgery-BPKIHS, Dharan, Nepal

<sup>2</sup>Consultant Prosthodontist, Gaighat District Hospital, Gaighat, Nepal

<sup>3</sup>Professor, Department of Prosthodontics, College of Dental Surgery-BPKIHS, Dharan, Nepal

<sup>4</sup>Associate Professor, Department of Prosthodontics, College of Dental Surgery-BPKIHS, Dharan, Nepal

<sup>5</sup>Assistant Professor, Department of Prosthodontics, College of Dental Surgery-BPKIHS, Dharan, Nepal

### ABSTRACT

The total loss of teeth due to aggressive periodontitis is very traumatic for patient and immediate rehabilitation of such cases becomes a necessity. It is a challenging situation for a prosthodontist to rehabilitate such patient in order to preserve their aesthetic, psychological and functional wellbeing. One of the affordable and accessible options for rehabilitation of such condition is conventional immediate complete denture. The immediate replacement of missing teeth without a period of complete edentulism while maintaining the original vertical dimension and centric relation is one of the major advantages of these modality. This case report explains the method of fabrication of a conventional immediate complete denture with satisfactory retention, stability, support and aesthetics.

**Key words:** Aggressive periodontitis; Conventional immediate denture; Immediate complete denture; Prosthetic rehabilitation.

### INTRODUCTION

The replacement of missing teeth immediately after extraction is always a challenge to a prosthodontist. The immediate rehabilitation of extracted teeth helps the patient in psychologically atraumatic transition from dentulous to edentulous state.<sup>1,2</sup> The various options to rehabilitate such cases includes implant supported prosthesis, conventional complete denture and immediate complete denture.<sup>3</sup> Among these, immediate denture is one of the best provision due to its several advantages. This immediate denture not only prevent patient from social embarrassments but also preserve facial appearance, muscular

tone, speech, mastication and shape and height of the ridge. It acts like a bandage which applies negative pressure over the extraction wound, thus, controlling hemorrhage and contaminations. The patient also experiences less postoperative pain because of its protective action. The diet of a patient though limited to soft food initially is not interrupted because of the presence of denture. The immediate replacement of extracted teeth with a prosthesis helps the patients with easier adaptation to it.<sup>3</sup> This case report illustrates the clinical procedure for fabrication of conventional immediate denture in case of teeth loss due to aggressive periodontitis.

### CASE REPORT

A twenty-eight years old female diagnosed with generalized aggressive periodontitis was referred to Department of Prosthodontics, College of Dental Surgery, B. P. Koirala Institute of Health Sciences for oral rehabilitation. Clinical

*Conflict of Interest: None*

#### **\*Corresponding Author**

Ankita Rai, Senior Resident, Department of Prosthodontics and Crown-Bridge, College of Dental Surgery, B.P. Koirala Institute of Health Sciences, Dharan, Nepal  
E-mail: ankiar91@gmail.com

examination showed missing 11, grade III mobility of remaining maxillary teeth and Grade I mobility of all mandibular teeth (Figure 1). The periodontitis of the maxillary teeth was progressive even after multiple periodontal therapies resulting in hopeless prognosis, in particular 21, which was lost during the course of treatment whereas, mandibular teeth showed considerable improvement with successive treatments.

The preoperative orthopantomogram (Figure 2) showed generalized severe bone loss on maxillary teeth. After necessary clinical and radiographic evaluation, a maxillary conventional immediate denture was planned. Initially, the plan was to extract 15, 16, 17 and 25, 26, 27 leaving the first premolars on first and second quadrant intact, so that the vertical dimension of occlusion is maintained. However, 12, 13, 14, 15, 16 and 17 had to be extracted and the treatment plan was modified. The molars on the second quadrant were extracted with preservation of both premolars to provide posterior stop during jaw relation. On recall visit after 7 weeks, healing of the extraction socket was found to be satisfactory (Figure 3).

The primary impressions of both arches were made with irreversible hydrocolloid (Algitex) after blocking the interdental area of mobile teeth with modelling wax. Casts were poured with dental plaster (Kalabhai, Kaldent). A sectional custom tray covering the edentulous area was used for border molding with low fusing impression compound (DPI, Pinnacle) (Figure 4A) followed by secondary impression with light body elastomer (Densply, Reprosil) (Figure 4B). The pick-up impression was made in the stock tray using irreversible hydrocolloid (Zelgan 2002) (Figure 4B). Master cast was poured using Type III dental stone (Kalstone) followed by fabrication of wax occlusal rim on shellac base plate. A face-bow transfer (Figure 5A) was done (Figure 5B) along with the centric

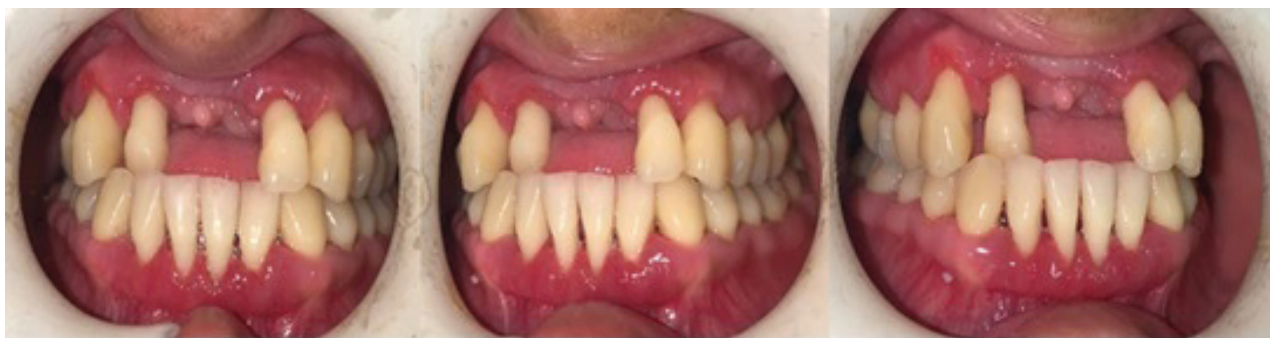relation interocclusal record with Alu wax for mounting the mandibular cast (Figure 5C).

After shade selection, teeth arrangement (Figure 6) was done. The remaining natural teeth were removed from the master cast (up to gingival margin level) with the help of wide fluted carbide burs on rotary instrument and B.P. blade one at a time and subsequently replaced by acrylic teeth from 22 to 25 (Figure 7). In this way, a single complete denture was waxed up from a partially edentulous cast. The maxillary single complete denture was processed using heat cure acrylic resin using conventional techniques without try-in appointment. The extraction of remaining maxillary teeth were carried out on the day of denture insertion. After half an hour the patient was given an analgesic to counter pain due to extraction. Before the insertion of maxillary immediate denture, it was kept in 2% glutaraldehyde for disinfection. The intaglio surface of denture was checked for any sharp impinging portions and modified.

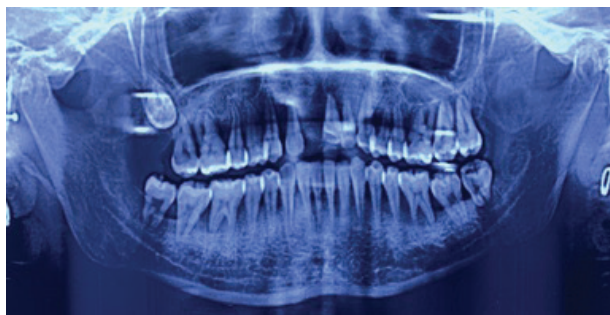The denture was seated and only gross occlusal prematurities were removed. After the insertion of the denture the patient was asked to continuously wear it for 7 days until the inflammation of the surgical site subsided. Proper oral hygiene maintenance and a soft diet was recommended. For at least 48 hours, the patient was not allowed to remove the denture from mouth, so gentle rinse with lukewarm saline water was recommended after every intake of food or drink. When the patient was able to remove the denture, warm saline rinse followed by thorough cleaning of the tissue surface of the denture was advised. The follow up were done after 24 hours and 48 hours, when evaluation of fit, comfort, retention and occlusion were checked. On one week follow up, the healing was found to be satisfactory and occlusal evaluation and modifications were done. After one month, there was no subjective complaints regarding fit and occlusion.

On 6 month follow up, the denture was found to be loose with unsatisfactory occlusion. So, before construction of a new definitive denture occlusal plane analysis with Broadrick plane analyser (Figure 10) was done. The first and

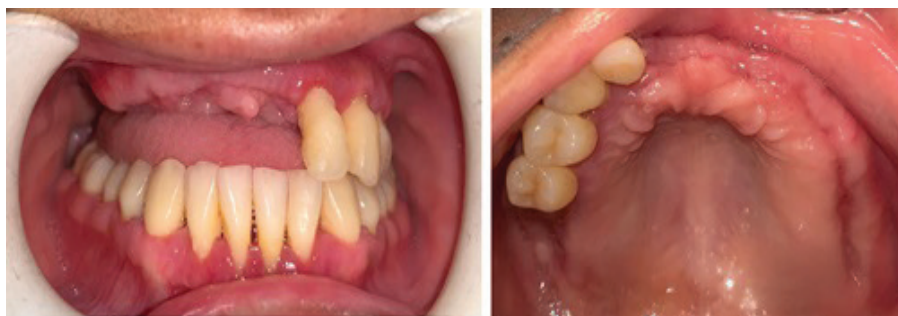second left mandibular molars were found to be inferior to occlusal plane. Hence, restorative buildup of the 36 and 37 was done with bulk fill composite (Figure 11) to achieve harmonious occlusion with new maxillary denture.



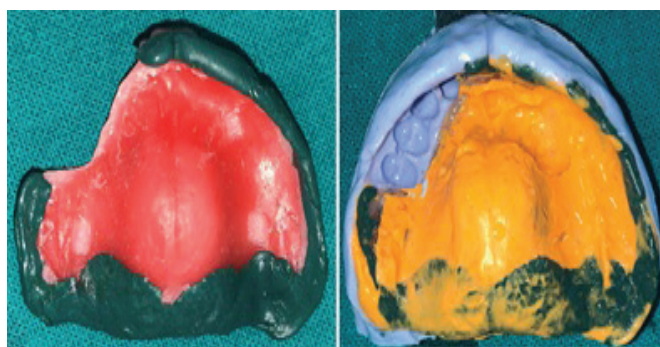
*Figure 1: Preoperative photograph with loss of 11, 21*



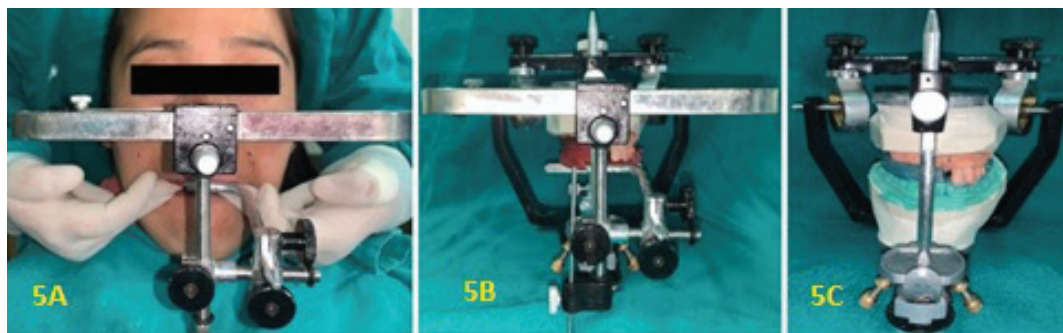
*Figure 2: Preoperative orthopantomogram (OPG)*



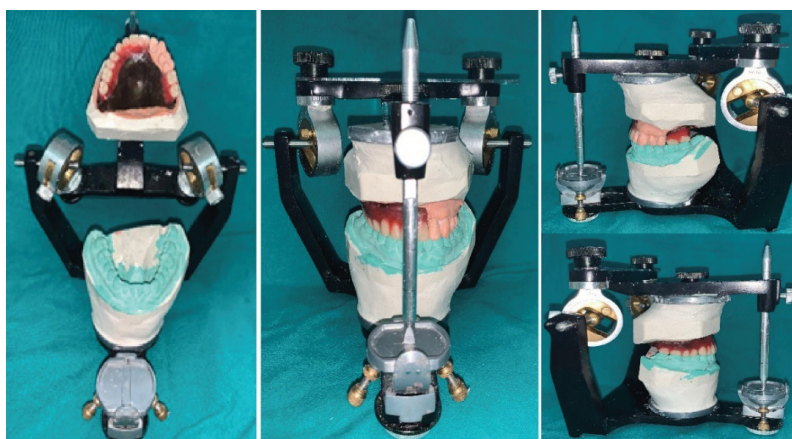
*Figure 3: After 1<sup>st</sup> surgical visit.*



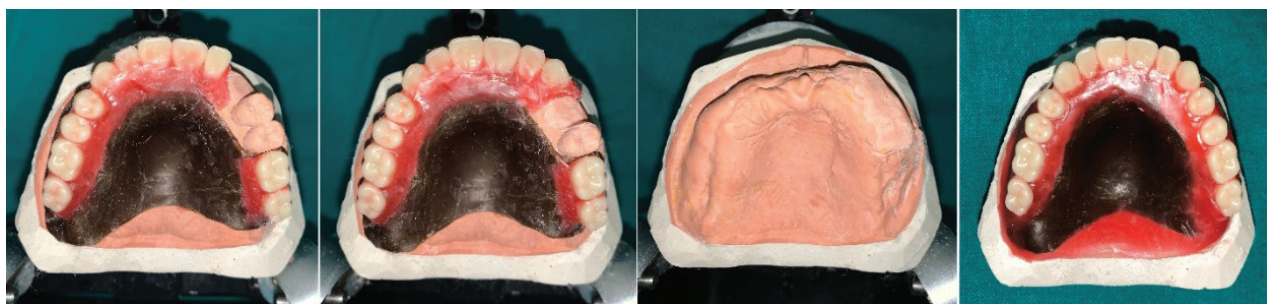*Figure 4: 4A: Border molding with sectional custom tray;  
4B: Pick-up impression*



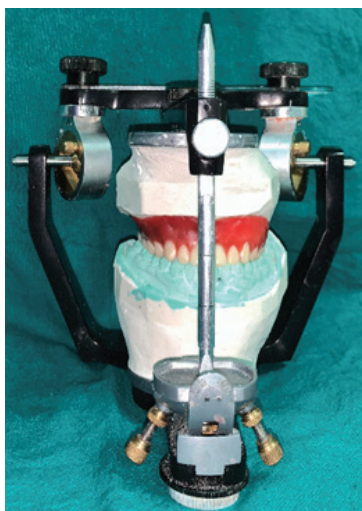
*Figure 5: 5A, 5B: Facebow transfer, 5C: Mandibular dentulous cast articulated with the help of Alu wax centric record*



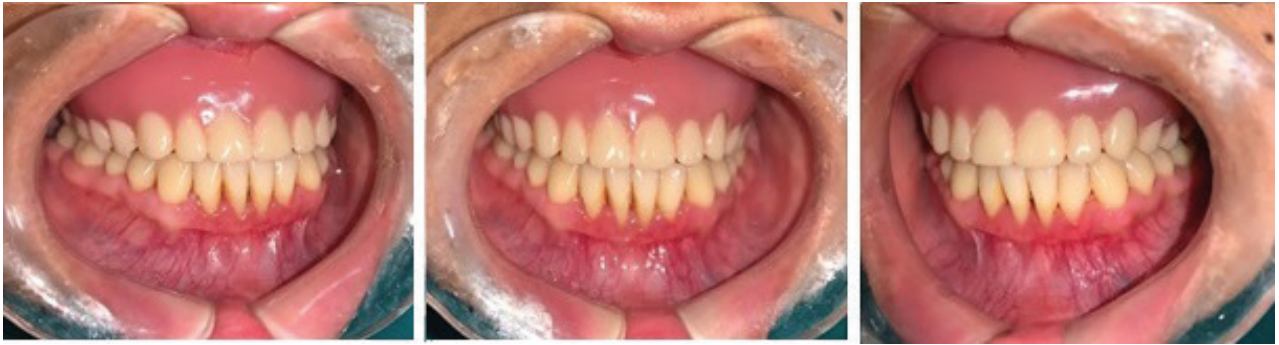*Figure 6: Teeth arrangement on edentulous areas.*




*Figure 7: Teeth arrangement by removing each tooth on the cast (from left to right).*



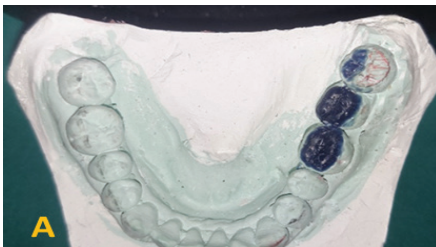
*Figure 8: Single denture complete teeth arrangement.*



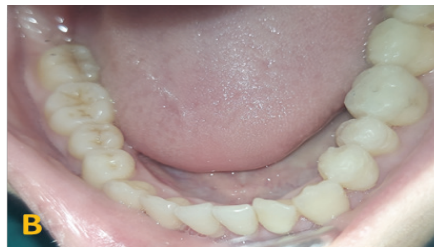*Figure 9: Insertion*



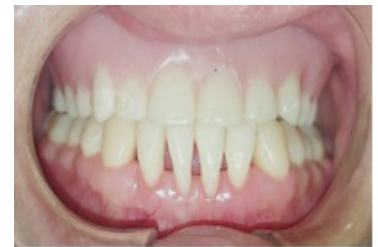*Figure 10: Occlusal plane analysis done with broadwick plane analser for final denture after 6 month*



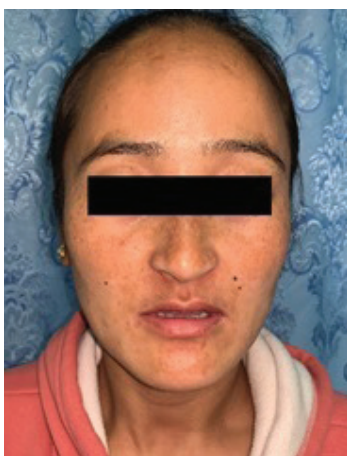*Figure 11: A: Wax build up (Blue) done in the area to be restored.*



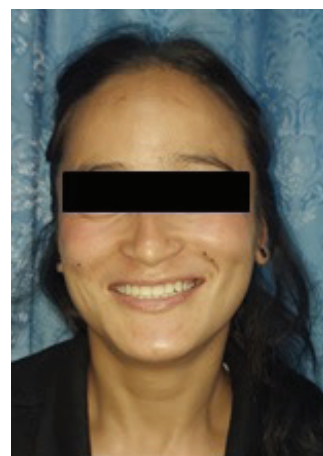*B: Restoration done wrt 36 and 37 with composite to achieve occlusal harmony.*



*Figure 12: Intraoral view with definitive denture after 6 months*



*Figure 13: Preoperative photograph*



*Figure 14: Postoperative photograph*

## DISCUSSION

The rehabilitation options when all teeth in an arch becomes hopeless and undergoes extraction are implant supported prosthesis or conventional complete denture or immediate complete denture.<sup>3</sup> Many a times, implant supported prosthesis is not opted due to economic problems or insufficient bone or underlying systemic diseases.<sup>5</sup> Karoussis et al. mentioned that more complication and decreased survival rates were seen when implants were placed in chronic periodontitis cases.<sup>6</sup>

The conventional complete denture fabrication may take months and can be stressful to the patients. Thus, a conventional immediate denture is one of the options where the denture is delivered immediately after extraction of the remaining anterior teeth.<sup>3</sup> Sears mentioned that it is wise to construct dentures before removal of teeth.<sup>1</sup> The advantages being easy record of original vertical dimension, preservation of facial appearance, decreased post-extraction pain and at no point of time patient is without teeth.<sup>3,7</sup>

In our case, the economic factor and history of periodontitis was the reason for considering immediate denture. An interim immediate denture was not opted because extraction of all teeth on one appointment could be traumatic to the patient and there could be problems with adaptation.<sup>7</sup> So, remaining anterior teeth and premolars on the left side were removed on the day the denture was inserted.

The fabrication of denture base using autopolymerising resin required more time so shellac base plate was used as it can be constructed in a minimal amount of time.<sup>8</sup> Nimmo A mentioned the use of impression plaster or Zinc oxide eugenol paste over occlusal rim for bite registration.<sup>3</sup> However, Alu wax was used for bite registration in this case because of its easy availability. The denture

finally fabricated was to be inserted on the same day of teeth extraction with open wound so for proper sterilization, it was disinfected by immersing it in glutaraldehyde prior to insertion for 10 minutes.<sup>9</sup>

After 6 months, the retention and occlusion with immediate denture was found to be unsatisfactory because of the natural mandibular teeth present. So, for establishment of better bilateral stability of definitive denture, occlusal plane analysis was done with custom made Broadrick occlusal plane analyser. The analyser was attached to the upper member of semi adjustable articulator as described by Lynch and McConnell.<sup>10</sup> The occlusal surface of 36 and 37 was found to be below the plane of occlusion. Therefore, similar to a study done by Foong et al. in 2019, the occlusal plane was corrected by composite build up on 36 and 37 to achieve a harmonious occlusion with the final denture to be fabricated.<sup>11</sup>

Many challenges are met while making immediate denture, like no provision for anterior try-in, longer appointments time and inadequate fit when compared to conventional complete denture. Therefore, the fabrication of immediate denture requires proper patient selection, preferably individuals with cooperative mental attitude.<sup>12</sup> along with adequate counseling prior to the start of treatment, addressing the steps of fabrication of immediate denture and the possibility of loss of retention on healing of the alveolar ridge.<sup>2</sup>

## CONCLUSION

The rehabilitation with immediate denture is an important treatment option when implant supported prosthesis or conventional complete denture is not feasible. Proper case selection, detailed examination and patient cooperation is a must for the successful treatment with immediate complete denture.

## ACKNOWLEDGEMENT

Dr. Bibha Pathak, Prosthodontist.

## REFERENCES

- Hasti K, Hasti A, Sharma R, et al. Immediate denture - An important treatment modality. *Kerala Dent J* 2016; 39: 6–9.
- Bhat V, Balaji SS. Immediate partial denture prosthesis - A case report. *Nitte Univ J Heal Sci* 2013; 3: 120–124. DOI:10.1055/s-0040-1703717.
- Nimmo A, Winkler S, Conventional immediate complete dentures. In: Winkler S. *Essentials of complete denture prosthodontics*. 3rd ed. AIBTS Publisher, India, 2015. 361-374. DOI: 10.1016/0022-3913(61)90227-X.
- Driscoll CF, Freilich MA, Guckes AD, et al. The glossary of prosthodontic terms. *J Prosthet Dent* 2017; 117: 1–105. DOI: 10.1016/j.prosdent.2016.12.001.
- Yeung C, Leung KCM, Yu OY, et al. Prosthodontic rehabilitation and follow up using complete conventional immediate denture. *Clin Cosmet Investig Dent* 2020; 12: 437–445. DOI: 10.2147/CCIDE.S271304
- Karoussis IK, Salvi GE, Heitz-Mayfield LJA, et al. Long-term implant prognosis in patients with and without a history of chronic periodontitis: a 10-year prospective cohort study of the ITI® Dental Implant System. *Clin Oral Implants Res* 2003; 14: 329–39. DOI: 10.1034/j.1600-0501.000.00934.x
- Caputi S, Murmura G, Ricci L, et al. Immediate denture fabrication: a clinical report. *Ann Stomatol (Roma)* 2013; 4: 273–277. PMID: [24611094](#)
- Morrow RM, Laboratory procedures for immediate overdentures. In: Morrow RM, Rudd KD, and Rhoads JE. *Dental laboratory procedures Complete Dentures*. First South Asia edition, Elsevier; 2016. 512-544.
- Bhathal M, Kukreja U, Kukreja N. Evaluation of efficacy of different denture disinfectants on biofilms formed on acrylic resin. *Dental Journal of Advance Studies*. 2018 Sep 17;6(1):020-7. DOI:10.1055/s-0038-1671696.
- Lynch CD, McConnell RJ. Prosthodontic management of the curve of Spee: use of the Broadrick flag. *The Journal of prosthetic dentistry*. 2002 Jun 1;87(6):593-7.
- Foong KW, Patil PG. Fabrication of maxillary single complete denture in a patient with deranged mandibular occlusal plane: A case report. *The Saudi Dental Journal*. 2019 Jan 1;31(1):148-54.
- Arbree NS, Immediate Denture. In: Zarb G.A., Bolender C.L., Hickey J.C. and Carlsson G.E. *Boucher's prosthodontics treatment for edentulous patients*. 12th Edition, CV Mosby, St. Louis; 2004. 123-159.