

Porosity in the Final Denture-A heartbreak !

Maskey B¹, Khanal G²

¹Associate Professor, Department of Prosthodontics and Maxillofacial Prosthetics, People's Dental College and Hospital, Kathmandu

²Intern, People's Dental College and Hospital, Kathmandu

ABSTRACT

Porosities in the aftermath of a polymerization defect occurring in a complete denture are incidental in some cases with time constraints, though unintentional. Such defects harbour microbial colonization, compromise mechanical and aesthetic properties and at times are even unserviceable to the patient. Remaking the denture right before insertion is disheartening in these instances, both for the patient and the attending clinician. This clinical report describes a rebasing technique which was undertaken to replace a fragile denture base.

Key words: Complete denture; Porosity; Rebasing

INTRODUCTION

The last consideration for a patient after the state of complete edentulism; the easiest way to rehabilitate the function of mastication, speech, aesthetics is via complete denture.^{1,2} Fabrication of these dentures involve several clinical and laboratory steps which has to be carried out as precisely as possible. Any slackness from the part of the dentist, student or the entrusted technician can compromise the final prosthesis.³⁻⁵

Errors during proportioning of monomer and polymer, improper mixing technique, inadequate pressure and material during packing and monomer vaporization during curing cycle can result in porosities which are undesirable.^{6,7} These porosities within a heat processed denture base can significantly compromise mechanical and aesthetic properties.⁶ Additionally, they are

also the nidus for harboring micro-organisms which account for poor hygiene of the final dentures.⁸

It is obvious that porosities can easily be avoided and every effort has to be made to fabricate a denture free of these flaws. However, they are still encountered routinely and needs attention. This case report describes one of these instances where extensive porosities were observed in the finished denture and had to be rebased.

Case report

A 62 years old male patient presented to the Department of prosthodontics and maxillofacial prosthetics, People's dental college and hospital, Kathmandu with a chief complaint of loss of all the teeth in the mouth and wanted a complete rehabilitation. Apparently, the denture was fabricated by an attending student as part of her clinical work but extensive porosities, both internal and external porosities were observed on the upper dentures after processing. (Fig.1 a, b) Considering that the patient had been in the capital for a month for the sole purpose of rehabilitation and the urgency to rectify the error was obvious, rebasing was planned.

Conflict of Interest: None

*Corresponding Author

Dr. Brijesh Maskey
Associate Professor, Department of Prosthodontics
and Maxillofacial Prosthetics,
People's Dental College and Hospital, Kathmandu
E-mail: bridgesmaskey@yahoo.com

Additionally, thorough appraisal of the upper denture was carried out for any shortcomings. The peripheral extension was optimum except for the distobuccal region bilaterally. The vertical dimension at occlusion (VDO) was satisfactory, centric occlusion (CO) coincident with the centric relation (CR) with no interferences on eccentric jaw movements. (Fig.2) The denture bearing area had no pathological changes, hyperplastic tissues or severe osseous undercuts.

The upper denture was then prepared for rebasing. The borders were reduced by 2mm approximately and border moulding was performed using a green stick thermoplastic compound. (Fig.3) The impression surface of the denture was then trimmed around 0.5mm except for the post dam area to provide space for the final impression material. The final impression was made with zinc oxide eugenol paste with lower denture in place. The existing maximum intercuspation was used as a means to seat the upper denture the avoid any movement.

Master cast, thus obtained was not separated from the denture at this point. It was further mounted on the upper member of the mean value articulator. (Fig.4) Petroleum jelly was applied to the surface of teeth after the plaster had set. On the lower member, occlusal index of upper teeth measuring 1-2mm in depth was made in plaster and left to set. The denture was then separated from the master cast and trimmed to the extent that the acrylic from the existing denture just held the teeth as one block. This teeth-acrylic block was then seated on the indexes and secured with sticky wax. (Fig.5) A temporary denture base was fabricated and reassembled in the master cast. The space between the denture base and the block was filled with modeling wax and this served as a trial denture. (Fig.6) After the try-in, the denture was processed, trimmed, finished and polished, following which delivery was done. Occlusal discrepancies were addressed on follow up and the patient education was reinforced.

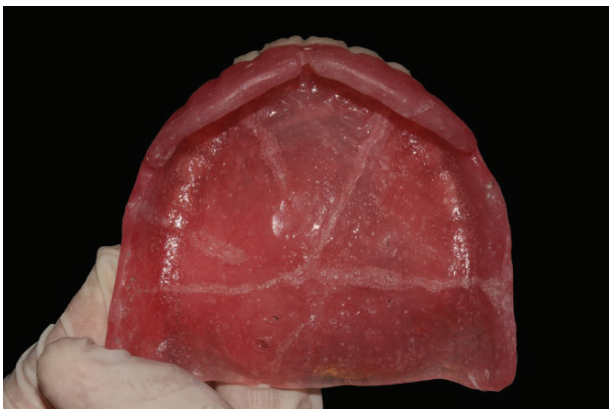


Figure 1: Porosities in the upper denture a. external porosity b. internal porosity

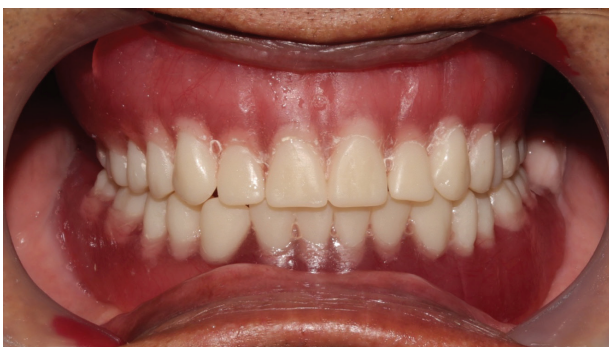

Figure 2: Acceptable VDO, CO coinciding with CR

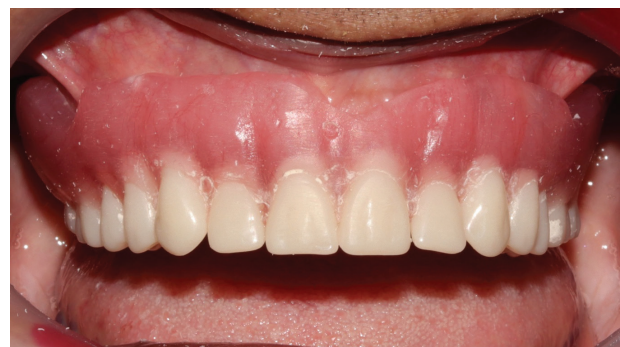

Figure 3: Preparation of the upper denture for border molding and final impression

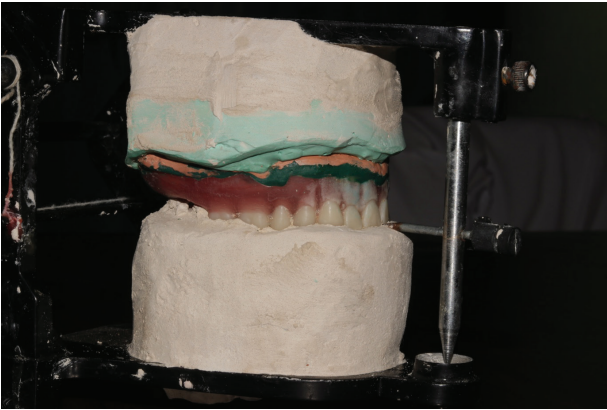


Figure 4: Upper denture mounted on articulator after border-molding and final impression

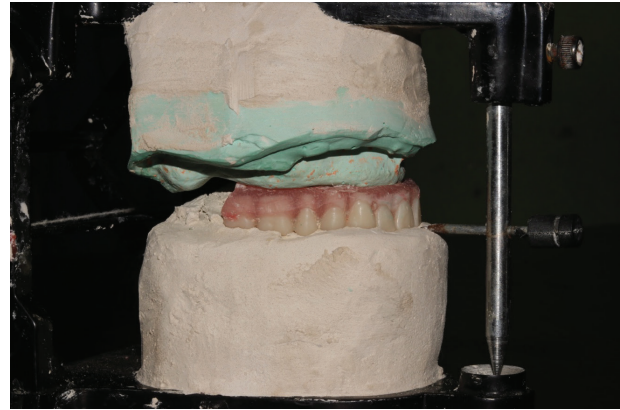


Figure 5: Teeth-acrylic block oriented on the occlusal index

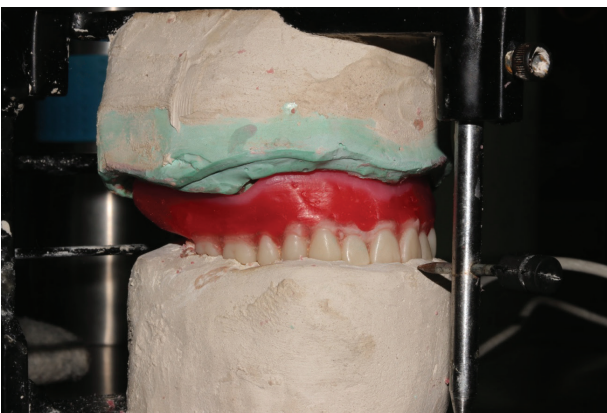

Figure 6: Trial denture

DISCUSSION

Porosity in a heat cure denture base resin is not desirable, yet very common during denture fabrication. According to a study, 66% of the students encountered porosities after processing dentures during pre-clinical training.⁹ It is disheartening, both for the attending clinician and the patient to consider a remake, just before the delivery. Alternatively, rebasing to replace the fragile denture base can be a practical solution in this situation.

The laboratory procedure for rebasing/relining includes articulator method, jig and the flask method. The technique used here is a jig method, but instead of using dedicated device like Hooper's duplicator or a Jectron jig, a conventional three point mean value articulator has been used to maintain the occlusal-mucosal distance.¹⁰ A simple articulator is available in

the minimalistic setup and can serve the same purpose with ease. In addition, the provision for a trial denture is very assuring for the patient as well as the clinician. However, like any rebasing technique, there is always the possibility of alteration in VDO and occlusion discrepancy which needs to be closely monitored.

CONCLUSION

Fabrication of a complete denture involves multiple steps which necessitates precision. Having said that, porosity is always a possibility and it should never be overlooked. The decision to rebase should always be considered over remake, especially when time constrained.

REFERENCES

1. Ellis JS, Pelekis ND, Thomason JM. Conventional rehabilitation of edentulous patients: the impact on oral health-related quality of life and patient satisfaction. *J Prosthodont.* 2007;16(1):37-42. doi:10.1111/j.1532-849X.2006.00152.x
2. Kattadiyil MT, AlHelal A, Goodacre BJ. Clinical complications and quality assessments with computer-engineered complete dentures: A systematic review. *J Prosthet Dent.* 2017;117(6):721-728. doi:10.1016/j.prosdent.2016.12.006
3. Rudd RW, Rudd KDA. Review of 243 errors possible during the fabrication of a removable partial denture: part I. *J Prosthet Dent.* 2001;86:251-61.

4. Rudd RW, Rudd KDA. Review of 243 errors possible during the fabrication of a removable partial denture: part II. *J Prosthet Dent.* 2001;86:262–76.
5. Rudd RW, Rudd KDA. Review of 243 errors possible during the fabrication of a removable partial denture: part III. *J Prosthet Dent.* 2001;86:277–88.
6. Anusavice KJ. *Phillip's Science of dental materials*, 11th ed. St. Louis:Elsevier; 2004.
7. McCabe, J.F., Walls, A.W.G. *Applied Dental Materials* UK: Blackwell Publishing Ltd. 2008 (9th ed.). 64-77.
8. Final report of the workshop on clinical requirements of ideal denture base materials. The Academy of Denture Prosthetics. *J Prosthet Dent.* 1968;20(2):101-105. doi:10.1016/0022-3913(68)90132-7
9. Nanda kumar E, Suresh V. Assessing the errors during the processing on complete denture. *Research J. Pharm. and Tech.* 2016;9(12):2287-2294. Doi:10.5958/0974-360X.2016.00461.3
10. Maskey B, Shrestha J. Let's Give Dentures Another Chance!. *J. Nep. Prosthodont. Soc.* 2020;3(1):49-53.