

Tooth and Gingival Display at Posed and Spontaneous Smile

Devkota G¹, Pradhan Joshi S², Shrestha P³, Sah S⁴, Verma A⁵

¹PG resident, NAMS, Bir Hospital, Kathmandu, Nepal

²Professor, NAMS, Bir Hospital, Kathmandu, Nepal

³Associate Professor, NAMS, Bir Hospital, Kathmandu, Nepal

^{4,5}Assistant Professor, NAMS, Bir Hospital, Kathmandu, Nepal

ABSTRACT

Introduction: Amount of gingival display is one of the important aspect of smile esthetics parameter which allows the clinician to accurately diagnose and select an appropriate treatment plan for the patient. The purpose of this study is to evaluate the amount of teeth and gingival display in posed and spontaneous smile by using videography method.

Methodology: A cross sectional, observational study was conducted among 144 participants. Standardized videography of the participants were taken with DSLR. Video clips were taken for tooth display at rest, posed smile and spontaneous smile. Digital recordings were transferred to laptop and measurements of the dentogingival display were made by importing frames in Adobe photoshop CS6 extended software. The type of smile line were recorded based on the dentogingival display at posed and spontaneous smile. Data were entered and analyzed in excel 2016. Parametric (quantitative) data were interpreted as mean \pm SD and Non parametric (qualitative) data were interpreted as percentile. To compare parametric data student t test was used and for non parametric data chi square test was used.

Result: There was a significant difference between dentogingival display during posed and spontaneous smile. In male participants, the mean tooth display at rest was 0.91 mm, mean dentogingival display at posed smile was 7.21 mm and at spontaneous smile was 9.02 mm. In female participants, the mean tooth display at rest was 1.26 mm, mean dentogingival display at posed smile was 7.39mm and at spontaneous smile was 9.48 mm.

Conclusion: Within the limitations of this study, dentogingival display in spontaneous smiles is higher than in posed evaluations. Clinical evaluations and restorative thoughts should be planned according to the spontaneous smile, as the gingival appearance increases when patients are smiling naturally rather than posing. Video recordings provides more comprehensive information for assessment of dentogingival display.

Key words: Gingival display, Posed smile, Spontaneous smile

INTRODUCTION

A smile is change in one's facial expression by spreading the lips, often to signal pleasure.¹ An esthetically pleasing smile depends not only on components such as tooth

size, shape, color, and position, but also on the amount of visible gingivae and the framing of the lips.² The higher the lip is elevated when smiling, the more visible the teeth and gingiva are, and greater their role in the esthetic value of the smile.

The visibility of the gingival tissues depends on the position of the smile line and the relationship between the upper lip and the size and visibility of teeth.³ Gingival displays within 0 to 2 mm and 2 to 4 mm have been reported to be esthetically pleasing, while higher or lower smile lines may present esthetic issues. Many authors have classified smile into different types,

Conflict of Interest: None

*Corresponding Author

Dr. Garima Devkota, PG Resident, Prosthodontic unit, Dental Department, National Academy of Medical Sciences (NAMS), Bir Hospital, Kathmandu, Nepal

Phone No: +977-9849385110

E-mail: gdevkota4.gd@gmail.com

Ackerman et al. classified smile into two basic types: social smile/posed smile and enjoyment smile/unposed smile based on reproducibility of smile, it's voluntary and involuntary nature and the contraction of lip elevator muscles.⁴ Tjan classified smile into high, average and low smile line based on amount of exposure of central incisors.⁵

Most often posed smile is considered by the clinician for diagnosis, treatment planning and research. This may cause false diagnosis because patient's spontaneous smile differs significantly by displaying more teeth and gingiva.³ Many studies done on the assessment of smile esthetics has used photographic method for evaluation of dentogingival display in posed and spontaneous smile. Tarantili et al. studied lip movements during spontaneous smiling in a sample of children using videographic method. Their findings about the dynamics of the spontaneous smile raised concern about the validity of a single photographic capture for esthetic assessment.⁷ 10.5 years With the photographic methods, only the posed smile was considered reproducible. The simple and reproducible registration of a posed smile is an advantage with disadvantage that it can be influenced in its expression by the individual's social skills and emotional background. Spontaneous smile is an authentic emotion compared to posed smiling and therefore a logical focus point in smile diagnostics, a digital videographic measurement method was tested by Van der Geld et al. for reliability during both spontaneous and posed smiling. Central ideas behind this technique were that a spontaneous smile of joy must be recorded precisely at the exact moment, and recording should be done with minimal patient interference. Digital videography facilitates patient observation during rest, conversation, and smiling, providing information that cannot be visualized with a static image.⁸ Moreover, the concept of the smile line and the normal or average display obtained from static photographs also require revision.

Till now, very few studies have been done in Nepal where association between gingival visibility during posed and spontaneous smile position have been evaluated using only static photographs. Therefore, this study was done to determine the amount of teeth and gingival visibility by using digital videography method during posed and spontaneous smile that would be helpful in treatment planning to achieve desirable facial esthetics in many fields of dentistry.

METHODS

A cross-sectional, observational study was conducted at Prosthodontic unit, Department of Dental Surgery, NAMS, Bir Hospital, Kathmandu after ethical clearance from Institutional Review Board (IRB) of NAMS. The Duration of study period was one year starting from March 2021 to February 2022. Sample size was calculated and convenience sampling was done. Sample included volunteers aged 18-32 years. Participant present with the maxillary and mandibular teeth till 1st molar having healthy periodontium were included in the study. Participants having congenital anomalies, lip trauma, facial surgery, history of orthodontic treatment, periodontal surgery in the region of incisors, missing teeth in anterior region and fracture or worn incisors were excluded from the study. Every participant was informed about the purpose of the study. Informed consent was. Personal data regarding each participant was recorded on the Proforma. The data was kept confidential and was used only for research purpose maintaining anonymity.

For each participants digital video clips were made for spontaneous smile and posed smile. The video recordings were made in a setup consisting of a chair with a digital video camera (Canon 250D with 55 mm lens), a laptop and 2 spotlights placed at 45 degree angle to the participant's chair. The laptop screen was placed at eye level. The digital camera was positioned 55cm from the tip of the nose on a tripod stand and continuously registered the face. The

accurate positioning of the tripod between the sessions was done by securing it on the marking made on floor with the help of adhesives. Two composite buttons were placed at an identifiable anatomical location in left central incisor and intraorally distance were measured with the help of Vernier caliper (Fig 1). This was done for the calibration purpose for pixel to millimeter conversion in the digital files.

For tooth display at rest, videography of the participants was taken after swallowing. For posed smile, participants were asked to smile while taking videography and for spontaneous smile, the participants were asked to watch video fragments of practical jokes. In this way, tooth display at rest, posed smile and spontaneous smile were recorded with minimal intrusion of the participants. After the video registration, the digital recordings were transferred to laptop. Then, the dynamics of smile were observed frame by frame (Fig 2).

For tooth display at rest, video frames with mandible at rest after swallowing were selected, for posed smile, video frame of smiling were selected and for spontaneous smile, frame with maximum visibility of teeth and gingiva were selected. The digital images were then imported into software (Adobe Photoshop CS6) and various measurements were made.

Measurements were performed in the captured digital files by means of an electronic millimeter ruler that were calibrated in the photographs according composite buttons distance placed in left maxillary central incisor previously measured intraorally with the help of caliper. The display zone were traced in the software and all the measurements were made in pixels. Pixel measurement were then converted into millimeters with help of conversion ratio.

Dental display at rest was measured in millimeters from the frame obtained from the video taken after asking the participants to swallow and calculated from the incisal edge to the stomion of the upper lip (Fig 3).

Dentogingival display in posed and spontaneous smiles was expressed by measuring (mm) the distance from the incisal edge of the left maxillary central incisor to the lower edge of the upper lip following a vertical line (Fig 4 and Fig 5). Dentogingival display were observed for posed and spontaneous smiles for women and men.

The type of smile parameters were classified according to the study by Liébart et al.²³ (Fig 6 and Fig 7). The type of smile were calculated as percentages for male and female at spontaneous and posed smiles. The prevalence of dentogingival display were considered for all the classes where gingiva display was visible (classes I, II, and III) and were compared between sexes for posed and spontaneous smiles.

Statistical analysis: Datas were entered and analyzed in excel 2016. Parametric (quantitative) datas were interpreted as mean \pm SD. Non parametric (qualitative) datas were interpreted as percentile. To compare parametric datas student t test was used. To compare non parametric datas chi square test was used.

RESULTS

The mean age of males and females are depicted in table 1. The data for mean tooth display at rest, dentogingival display at posed smile and spontaneous smile for male and female participant are depicted in table 2,3. There was significant difference in dentogingival display at posed and spontaneous smile in both male and female participants as depicted in table 4,5. In the posed smile type, most frequently seen type of smile was class III and least frequently seen smile type was class I in both males and females (table 6). In spontaneous smile, most frequently seen type of smile was class II and least frequently seen type was class IV in both males and females (table 7). The prevalence of dentogingival smile display in males was 84.72% in posed smile and 91.67% in spontaneous smile and in females was 86.11% in posed smile and 97.22% in spontaneous smile (Table 8).

Table 1: Participants Characteristics

Participants Characteristics	Males Mean (years) \pm SD	Females Mean (years) \pm SD	P-value
Age	23.81 \pm 3.58	24.11 \pm 3.55	0.61

Table 2: Tooth display at rest, dentogingival display at posed and spontaneous smiles in male participants

Smile Characteristics	Males Mean (mm) \pm SD
Tooth display at rest	0.91 \pm 0.25
Dentogingival display at posed smile	7.21 \pm 1.16
Dentogingival display at spontaneous smile	9.02 \pm 1.69

Table 3: Tooth display at rest, dentogingival display at posed and spontaneous smiles in female participants

Smile Characteristics	Female Mean (mm) \pm SD
Tooth display at rest	1.26 \pm 0.29
Dentogingival display at posed smile	7.39 \pm 0.88
Dentogingival display at spontaneous smile	9.48 \pm 0.88

Table 4: Dentogingival display at posed and spontaneous smile

Smile Characteristics	Dentogingival display at posed smile (mm) \pm SD	Dentogingival display at spontaneous smile (mm) \pm SD	P-value
Male	7.21 \pm 1.16	9.02 \pm 1.69	<0.001*
Female	7.39 \pm 0.88	9.48 \pm 0.89	<0.001*

Table 5: Tooth display at rest, dentogingival display at posed and spontaneous smiles in male and female participants

Smile Characteristics	Male Mean (mm) \pm SD	Female Mean (mm) \pm SD	P-value
Dentogingival display at posed smile	7.21 \pm 1.16	7.39 \pm 0.88	0.28
Dentogingival display at spontaneous smile	9.02 \pm 1.69	9.48 \pm 0.88	0.04*

Table 6: Prevalence of type of smile (%) with respect to gender with posed smile

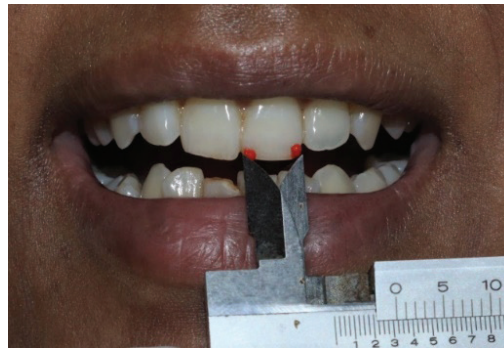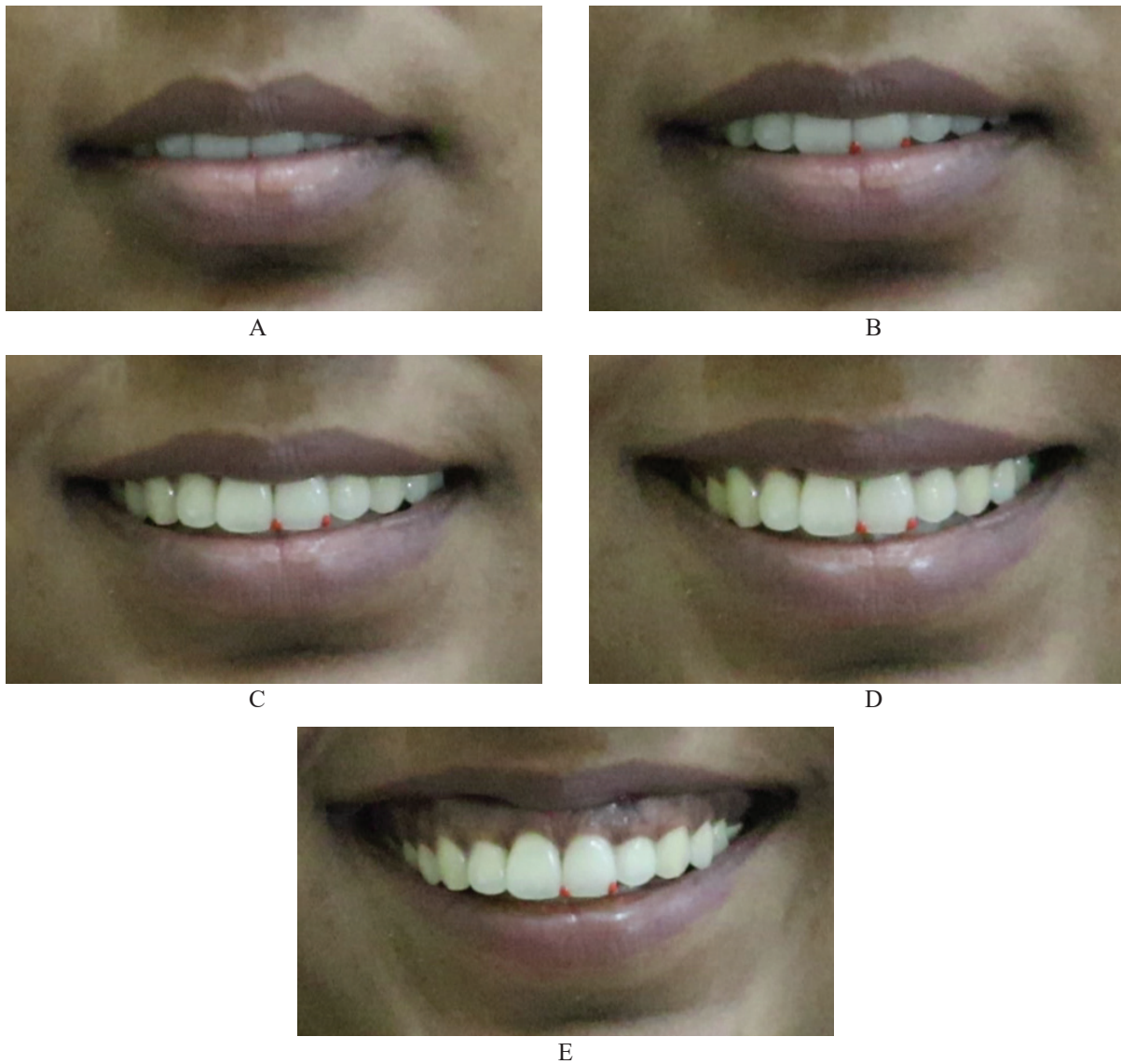Type of smile	Posed		P-value
	Male (%)	Female (%)	
Class I	1 (1.39%)	4 (5.55%)	0.18
Class II	16 (22.22%)	20 (27.78%)	0.50
Class III	44 (61.11%)	38 (52.78%)	0.51
Class IV	11 (15.28%)	10 (13.89%)	0.83

Table 7: Prevalence of type of smile (%) with respect to gender with Spontaneous smile

Type of smile	Spontaneous		P-value
	Male (%)	Female (%)	
Class I	12 (16.67%)	29 (40.28%)	0.0079*
Class II	34 (47.22%)	36 (50%)	0.81
Class III	20 (27.78%)	5 (6.94%)	0.0027*
Class IV	6 (8.33%)	2 (2.78%)	0.16

Table 8: Prevalence of dentogingival smile display with respect to gender with posed and spontaneous smiles

Dentogingival smile display	Posed (%)	Spontaneous (%)
Male	84.72%	91.67%
Female	86.11%	97.22%

**Figure 1:** Distance between composite buttons measured by Vernier caliper**Figure 2:** Representative digital images from video clip. Observe how smile line changes from first to last image.

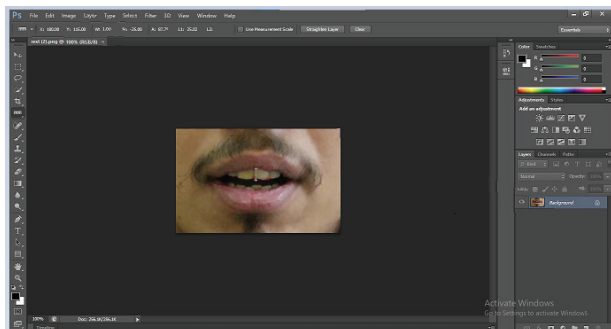


Figure 3: Measurement of tooth display at rest

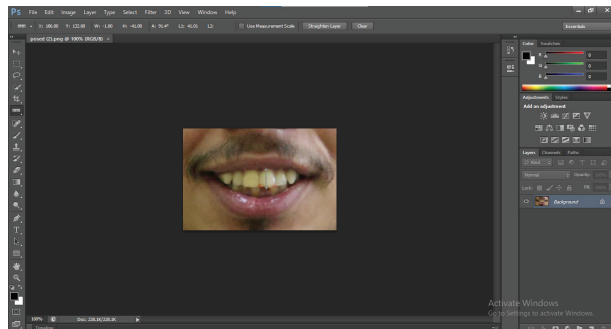


Figure 4: Measurement of dentogingival display at posed smile

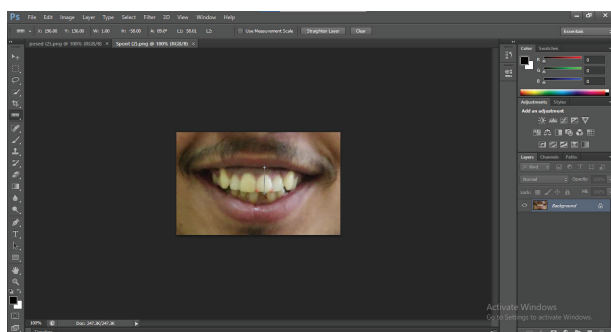
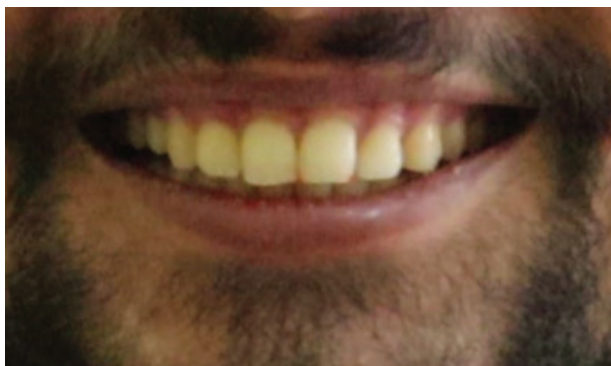
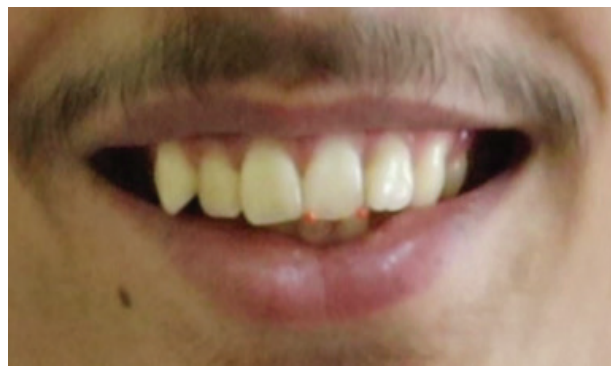
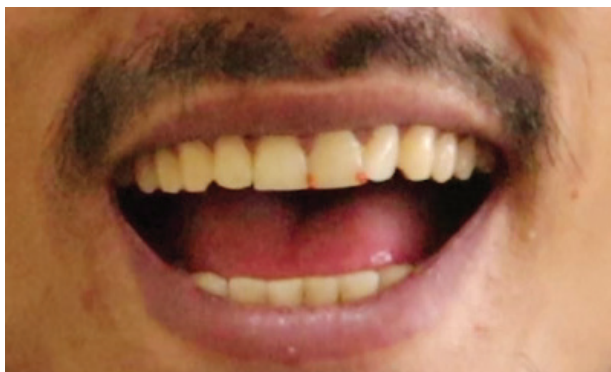Figure 5: Measurement of dentogingival display at spontaneous smile



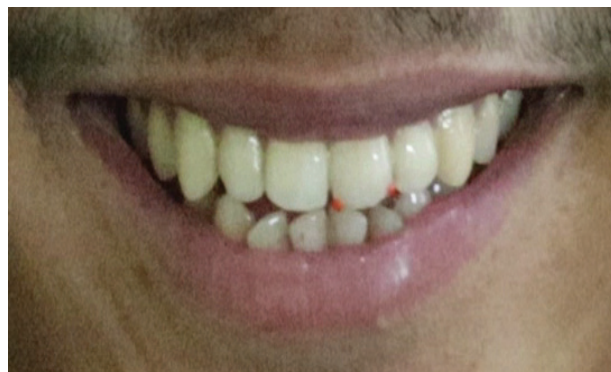A



B

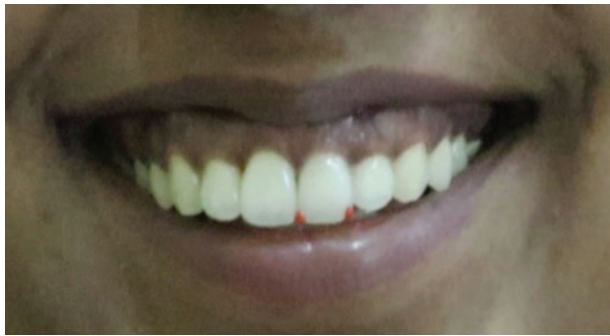

C

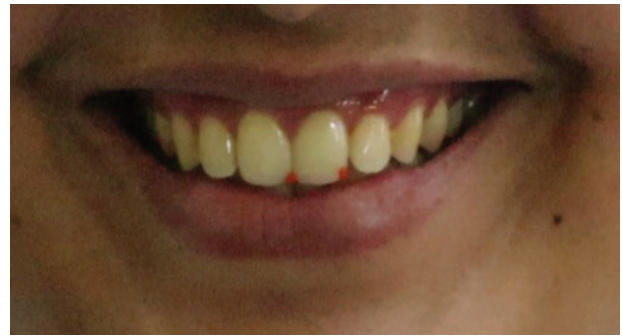

D

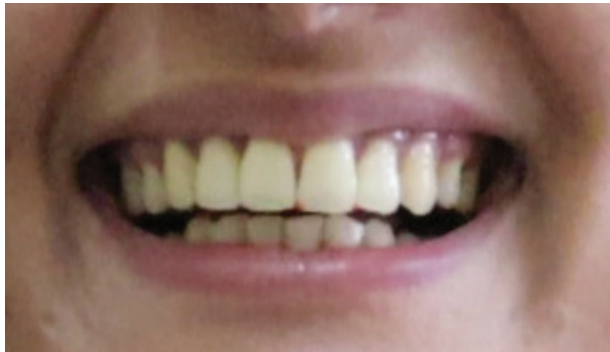Figure 6: Types of Spontaneous smile evaluated in males A, class I: very high smile line. B, class II: high smile line. C, class III: average smile line. D, class IV: low smile line



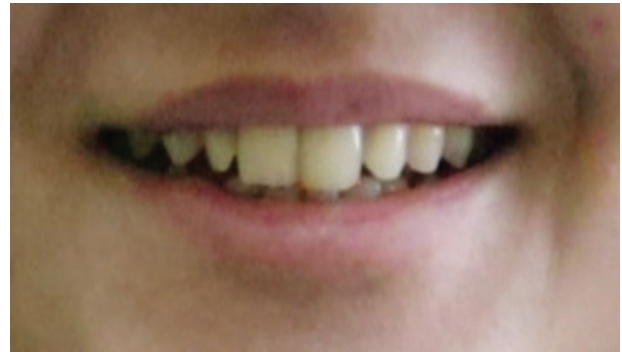A



B



C



D

Figure 7: Types of Spontaneous smile evaluated in females: A, class I: very high smile line. B, class II: high smile line. C, class III: average smile line. D, class IV: low smile line

DISCUSSION

The present study was conducted to evaluate the tooth and gingival display at posed and spontaneous smile in participant aged between 18-32 years. This age range was preferred because the gingival display changes as the age increases.²¹ There was a significant difference in dentogingival display at posed smile compared to spontaneous smile. In this study, in male participants, the mean dentogingival display at posed smile was 7.21 mm and mean dentogingival display at spontaneous smile was 9.02mm. In female participants, the mean dentogingival display at posed smile was 7.39 mm and mean dentogingival display at spontaneous smile was 9.48mm.

In the present study, the mean tooth display at rest was 0.91 mm in male participants and 1.26 mm in female participants. In the study done by Mahn et al³, the mean tooth display at rest was 1 mm and 1.26 mm in male and female participants respectively. Similar study done by

Al-Habahbeh et al¹⁹, Vig et al²⁴ and Connor et al²⁵ showed that the tooth display at rest was more in female compared to male. These findings were in agreement with the present study, although some variation may be explained by difference in measuring techniques.

In the study done by Mahn et al.³, mean dentogingival display in posed smile was 7.8 mm and 8.8 mm in male and female participants respectively and mean dentogingival display in spontaneous smile was 10.1 mm and 11 mm in male and female participants respectively. Similarly in the study done by Van der gald et al.⁸, dentogingival display in spontaneous smile was more than in posed smile having mean dentogingival display in posed smile 9.7 mm and in spontaneous smile 11.2 mm and. Their studies were in accordance with this study. All of these studies used videographic method to record the smile. In the study done by Roe et al.²⁶ mean dentogingival exposure at maximum smile was 8.9 mm in male subjects and 9 mm in

female subjects. In his study, maximum smile was mentioned as the smile with maximum dentogingival exposure. The dentogingival display even at maximum smile was less than that of dentogingival display in spontaneous smile of this study. This difference was because Roe et al used photographic method whereas digital videography method was used in this study, which provided the opportunity to select images that best reflect the specified function among numerous frames that are obtained over time.

The mean dentogingival display at posed and spontaneous smiles were more in female participants than in male participants in this study. These findings were in accordance with study done by Mahn et al.³, Basnet et al.¹¹ and Roe et al.²⁶ In their study also the mean dentogingival display at posed and spontaneous smiles were more in female participants than in male participants. Although the dentogingival display was measured from different anatomical location by different authors, the results were comparable. Maxillary central incisors are the key determinant in the evaluation of smile type and esthetics. Therefore, in this study, the dentogingival was evaluated by measuring the gingival display of the maxillary central teeth.^{27,28}

Different studies have observed the importance of type of smile and smile lines.²³ Smile line types can be classified as follows: a very high smile line (Class I), high smile line (Class II), average smile line (Class III), and low smile line (Class IV). The prevalence of the smile line types changed between the posed smile and the spontaneous smile. In present study, in posed smile type of smile line most frequently seen was class III for both genders, women (52.78%) and men (61.11%). The least frequently seen type was class I for both women (5.55%) and men (1.39%) but when evaluated in spontaneous smile, a greater part of the teeth

started to show in the smiling, presenting class II smile as the most frequently seen one for both genders (women 50%; men 47.22%) and the least frequently seen was class IV in both genders. In a study performed by Mahn et al.³, Class III was the most frequently seen smile type in posed smile and class II smile type most frequently seen during spontaneous smiling in both genders respectively. Another study done by Liébart et al.²³ reported the Class III smile line as the most frequent for both posed and spontaneous smile lines. All these studies are consistent with the present study.

The classifications of Tjan et al.⁵, Liebart et al.²³, and Jensen et al.²⁹ has given a range of dentogingival display and the threshold of display that tends to make smile less attractive. The evaluation of this threshold should be a matter for future investigations. When individuals smile spontaneously, this pattern changes, and what was previously considered a high smile line (Class II) is predominant, corroborating the importance of the dynamic assessment. It is nearly impossible to capture the highest smile line of a patient in a single photographic image, which is why video recording is indicated. This is consistent with this study and demonstrates that a video recording is indicated when the spontaneous smile requires evaluation. Also this study has shown that evaluation of gingival display and planning the esthetic restorations should be decided accordingly, because most of the participants showed a change in the type of smile between posed and spontaneous records. Moreover, treatments should be planned individually, as female usually present higher gingival display than males in both posed and spontaneous smiles.

Smile aesthetics has become paramount from patients perspective and therefore the clinicians have made it the cornerstone of their treatment mechanics. The amount of gingival display is an important parameter that directly affects

esthetics. Gingival display is the amount of gingival visibility during a smile. Usually, when the patient is asked to smile broadly during the clinical evaluation, the patient poses with a lower smile than usual. Clinicians often base their diagnosis, treatment planning, and research on patient's posed smiles at a single moment. For all those purposes, this static analysis can lead to misdiagnosis and non-ideal treatment because patients' spontaneous smiles may be significantly different from their posed smiles, displaying more teeth and/or gingiva. Spontaneous smiling should be the logical focus point for the esthetic diagnosis of lip-tooth relationship during smiling. Duchenne de Boulogne observed already in 1862, spontaneous and posed smiles exhibit physiognomic differences. Further psychophysiological research has found more asymmetries in posed smiles than in spontaneous smiles and different dynamic time patterns. Capturing spontaneous smiles using a video camera recording can change the display of soft tissues and teeth compared to static images produced by a camera. Recording a video for dynamic smiles can allow a proper analysis of esthetics and function.

Studies in the psychology literature have found that people are better able to detect posed emotions from motion photography than from still photography as shown by Ekman et al. Videographic method showed to be a reliable method of smile quantification because a more standardized smile could be obtained minimizing the inherent error of a single snapshot. Natural head position is a standardized and reproducible orientation of the head in space. Establishment of the natural head position is important to eliminate measurement errors, and the simplest procedure to obtain facial photographs in natural head position is to instruct the patient to sit upright and look straight ahead to a point at eye level on the wall in front of them. Many authors have demonstrated various ways to standardize natural head positioning.

Showfety et al developed a fluid level device to record head posture prior to exposure of the head film. In our study, natural head posture was obtained by asking the participants to sit straight and look at the lens of camera placed at eye level. The subjects felt at ease because of the absence of interfering medical devices for head standardization as used in some other studies.

The results of this study showed that spontaneous and posed smiling are different. Spontaneous smiling should be taken for proper assessment of the smile esthetics. The fast onset and fading out of a spontaneous smile makes it impossible to capture in the right moment with a static photograph. Therefore it is proposed to switch from static to dynamic video recording of the smile for diagnostic purpose.

The limitations of this study are:

1. The limitations in this study was the poor resolution of the digital videography.
2. During spontaneous smile, there was some movement of the patient which could not be controlled as spontaneous smile is an involuntary action and it should be captured with minimal intrusion of the participants.

CONCLUSION

Within the limitations of this study, the following conclusions were drawn:

1. Dentogingival display during smiling presented significant differences between posed and spontaneous smile. There was increases dentogingival display in spontaneous smile compared to posed smile.
2. Mean dentogingival display at posed and spontaneous smile were more in female participants than in male participants.
3. In posed smile, most frequently seen smile type was class III in both genders.
4. In spontaneous smile, most frequently seen smile type was Class II in both genders.

5. The present study demonstrated that gingival tissue is typically shown when people smile naturally, a fact that should lead the clinician to consider it standard and not in need of treatment. Clinical evaluations and restorative thoughts should be planned according to the spontaneous smile, as the gingival appearance increases when patients are smiling naturally rather than posing.
6. Videography provides diagnostic information that cannot be obtained with still photography alone.

ACKNOWLEDGEMENTS

Prof. Dr Sarita Joshi, Associate Professor Dr. Pragya Shrestha, Assistant Professor Dr. Sanjay Sah, Assistant Professor Dr. Anand Verma (Department of Dental Surgery, NAMS)

REFERENCES

1. Desai S, Upadhyay M, Nanda R. Dynamic smile analysis: Changes with age. *Am J Orthod Dentofacial Orthop.* 2009 Sep;136(3):310.e1-10.
2. Van der Geld PAAM, Oosterveld P, van Waas MAJ, Kuijpers-Jagtman AM. Digital asurement of tooth display and lip position in smiling and speech: Reliability and clinical application. *Am J Orthod Dentofacial Orthop.* 2007 Mar 1;131(3):301.e1-e8.
3. Mahn E, Sampaio CS, Pereira da Silva B, Stanley K, Valdés AM, Gutierrez J, et al. Comparing the use of static versus dynamic images to evaluate a smile. *J Prosthet Dent.* 2020 May;123(5):739–46.
4. Ackerman MB, Ackerman JL. Smile Analysis and Design in the Digital Era. *J Clin Orthod.* 2002 Apr 1;36(4):221–36.
5. Tjan AHL, Miller GD, The JGP. Some esthetic factors in a smile. *J Prosthet Dent.* 1984 Jan;51(1):24–8.
6. Nohl FSA, Steele JG, Wassell RW. Crowns and other extra-coronal restorations: Aesthetic control. *Br Dent J.* 2002 Apr;192(8):443–50.
7. Tarantili VV, Halazonetis DJ, Spyropoulos MN. The spontaneous smile in dynamic motion. *Am J Orthod Dentofacial Orthop.* 2005 Jul 1;128(1):8–15.
8. Van Der Geld P, Oosterveld P, Bergé SJ, Kuijpers-Jagtman AM. Tooth display and lip position during spontaneous and posed smiling in adults. *Acta Odontol Scand.* 2008 Jan;66(4):207–13.
9. Bidra AS, Persenaire M, Kuo C. The Influence of Age and Facial Expression (Eye Open/ Closed) On Maxillary Dental and Gingival Display. *J Prosthodont.* 2021 Dec;30(9):769–75.
10. Arifağaoğlu Ö, Yılmaz Ü. Analysis of gingival display during static and dynamic smiles in a Turkish sample: a clinical study. *Eur Oral Res.* 2022 Jan 1;56(1):23–7.
11. Basnet BB, Giri J. Amount of Gingival Display in Smiles of Sample Population from Nepalese Population with High Upper Lip Position. *JNDA.* 2019 Jun;19(1):6–9.
12. Sapkota B, Srivastava S, Koju S, Srii R. Evaluation of Smile Line in Natural and Forced Smile Position: An Institution-based Study. *Orthod J Nepal.* 2017 Jun 30;7(1):27–32.
13. Wang C, Hu W jie, Liang L zhi, Zhang Y ling, Chung KH. Esthetics and smile-related characteristics assessed by laypersons. *J Esthet Restor Dent.* 2018 Mar;30(2):136–45.
14. Singh N, Abdulla R, Sable R, Bhosale V, Halli R. Smile analysis: A comparison between photographic and videographic methods. *J Indian Orthod Soc.* 2016 Jan 1;50(1):8–13.
15. Drummond S, Capelli J. Incisor display during speech and smile: Age and gender correlations. *Angle Orthod.* 2016 Jul 1;86(4):631–7.
16. Galagali G, Naik J, Nidawani P, Mk S. Measurement of visible teeth surface area of the upper and lower anterior teeth during speech, using video photographic method in young adults - a survey. *Indo-Eur J Dent Ther Res.* 2015 Dec 1;3(3):294–6.
17. Zhang Y ling, Le D, Hu WJ, Zhang H, Liang L zhi, Chung KH, et al. Assessment of dynamic smile and gingival contour in young Chinese people. *Int Dent J.* 2015 Aug;65(4):182–7.
18. Prasad V, Tandon P, Sharma VP, Singh GK, Maurya RP, Chugh V. Photographical evaluation of smile esthetics after extraction

- orthodontic treatment. *J Orthod Res.* 2015 Jan 1;3(1):49–56.
19. Al-Habahbeh R, Al-Shammout R. Effect of gender on tooth and gingival display in the anterior region at rest and during smiling. *Clin Res.* 2009 Dec 1;4(4):382–95.
 20. Walder JF, Freeman K, Lipp MJ, Nicolay OF, Cisneros GJ. Photographic and videographic assessment of the smile: Objective and subjective evaluations of posed and spontaneous smiles. *Am J Orthod Dentofacial Orthop.* 2013 Dec 1;144(6):793–801.
 21. Dindaroğlu F, Doğan S, Ertan Erdinç A. Smile Esthetics: Age Related Changes, and Objective Differences between Social and Spontaneous Smiles. *J Clin Pediatr Dent.* 2011 Sep 1;36(1):99–106.
 22. Schabel BJ, Baccetti T, Franchi L, McNamara JA. Clinical photography vs digital video clips for the assessment of smile esthetics. *Angle Orthod.* 2010 Jul;80(4):678–84.
 23. Liébart MF, Fouque-Deruelle C, Santini A, Dillier FL, Monnet-Corti V, Glise JM, Borghetti A. Smile line and periodontium visibility. *Periodontal practice today.* 2004 Jan 1;1(1).
 24. Vig RG, Brundo GC. The kinetics of anterior tooth display. *J Prosthet Dent.* 1978 May;39(5):502–4.
 25. Connor AM, Moshiri F. Orthognathic surgery norms for American black patients. *Am J Orthod.* 1985 Feb;87(2):119–34.
 26. Roe P, Rungcharassaeng K, Kan JYK, Patel RD, Campagni WV, Brudvik JS. The Influence of Upper Lip Length and Lip Mobility on Maxillary Incisal Exposure. *Am J Esthet Dent.* 2012;2(2):10.
 27. Menezes EBC, Bittencourt MAV, Machado AW. Do different vertical positions of maxillary central incisors influence smile esthetics perception? *Dent Press J Orthod.* 2017 Apr;22(2):95–105.
 28. Machado AW. 10 commandments of smile esthetics. *Dent Press J Orthod.* 2014 Aug;19:136–57.
 29. Jensen J, Joss A, Lang NP. The smile line of different ethnic groups in relation to age and gender. *Acta Med Dent Helv.* 1999;4(2):38-46.