

Cocktail Management of Flabby Tissue Using Window Technique with Glycerine Injected Prosthesis- A Case Report

Mishra K¹, Hegde D², Shetty S³, Vijayalakshmi CR⁴, Shah S⁵

^{1,5} PG Student, Department of Prosthodontics, Bangalore Institute of Dental Sciences, Bangalore, Karnataka, India

² Professor and Head of the Department, Department of Prosthodontics, Bangalore Institute of Dental Sciences, Bangalore, Karnataka, India

^{3,4} Senior Lecturer, Department of Prosthodontics, Bangalore Institute of Dental Sciences, Bangalore, Karnataka, India

Abstract

Flabby ridge is an area of moveable soft tissue disturbing the maxillary or mandibular alveolar ridges. In this case, a technique for fabrication of a complete denture prosthesis is explained in which window technique has been used for making a secondary impression in the area of flabby tissue and then glycerine-supported denture fabrication was carried out which eliminates the disadvantages of tissue conditioners and soft liners and preserves the remaining tissues.

Key words: Flabby tissue; Modified denture; Window technique; Liquid supported denture; Glycerine supported denture

Introduction

A flabby ridge develops when hyperplastic tissue replaces a bony ridge or structure, and it can be related to resorption of residual ridge eventually over a period. Many studies have been conducted in the past and it was evaluated that Flabby or movable ridges are present in 24% of edentulous maxillary arches and 5% of edentulous mandibles.^{1,2} And the difficulties arise when the standard of the denture bearing areas aren't suitable for the impression making procedures. This hyperplastic tissue displaces the denture and affects the denture stability, retention, and support.³ Hence, soft tissue changes occur which is due to the muscle dynamics.⁴

Conflict of Interest: No

*Corresponding Author

Dr. Khushboo Mishra
Post Graduate Student, Department of
Prosthodontics, Bangalore Institute of Dental
Sciences, Bangalore, Karnataka, India
E-mail: jhakhush1601@gmail.com

A perfect denture should be ready to take masticatory forces and it should be applicable in flabby ridge condition too. Moreover, it should not be rocking and have flexible tissue surface to scale back the stress on the underlying tissues.⁵

This case report describes the fabrication of a complete denture with a modified window impression making technique and a glycerine-supported thermoplastic sheet incorporated in denture.

Case Report

A 64-year-old male patient reported to the department of prosthodontics at Bangalore Institute of dental science and hospital for replacement of missing teeth. On intraoral examination, a totally edentulous maxillary and mandibular arch with flabby tissue existing within the anterior region of the maxillary arch was noticed [Figure 1]. A treatment plan of fabricating an entire denture with the modification within the impression technique with minimum displacement of the denture during function and maximum retention and stability was decided. It had

been decided to use the window impression technique for the maxilla. The window impression technique for the maxilla and as the patient was diabetic, a liquid-supported denture was planned.

1. The procedure was started with making of primary impressions with irreversible hydrocolloids.
2. Custom trays were fabricated in autopolymerizing resin with a spacer of 1-mm thickness [Figure 2]
3. A window was created over the custom tray in the anterior region where flabby tissue was seen and the markings were transferred over the custom tray [Figure 2].
4. Border molding after this was carried out using the sectional method for the maxillary and mandibular arch with greenstick compound [Figure 3].
5. The impression was made with zinc oxide eugenol paste over the palatal area.
6. The impression was placed in the mouth, and light body polyvinyl siloxane (3M ESPET™ II GARANT) was syringed on the flabby tissues exposed through the window, and the maxillary impression was completed [Figure 4].
7. Jaw relation and try in were done [Figure 5].
8. And all the procedures till packing was conventional.
9. 1 mm thick polyethylene sheet was used within the denture at the time of packing. This flexible sheet that was incorporated was 2 mm short of the borders [Figure 6].
10. This sheet was adapted over the master cast with the help of a vacuum heat-pressed machine.
11. After this, the foil was well fitted and with the use of heat-cure denture base resin it was heat cured and the denture was finished and polished [Figure 7].
12. The patient was asked to use the denture for at least fourteen days. The main aim was that patient should get adjusted to new dentures.
13. The denture was now ready to be converted into a liquid-supported denture. A putty impression of the tissue surface of the denture was obtained to get the junction of the sheet and denture base resin. The cast was poured into a dental stone and therefore the positive replica of the denture was obtained with the junction marked over it. A replacement polyethylene sheet of 0.5 mm thickness was adapted on this stone replica, and vacuum-pressed
14. Two inlets were made in the denture in the molar region. The permanent polyethylene sheet was then incorporated in the denture base with the aid of a cyanoacrylate adhesive and was sealed. A viscous liquid, i.e., glycerin, was filled through the inlets. After that, inlets were sealed with acrylic [Figure 8].
15. The seal was checked properly by blowing air around it. In areas of leakage, it was resealed until a perfect seal was obtained at the junction and the occlusion was checked in patient's mouth [Figure 9].

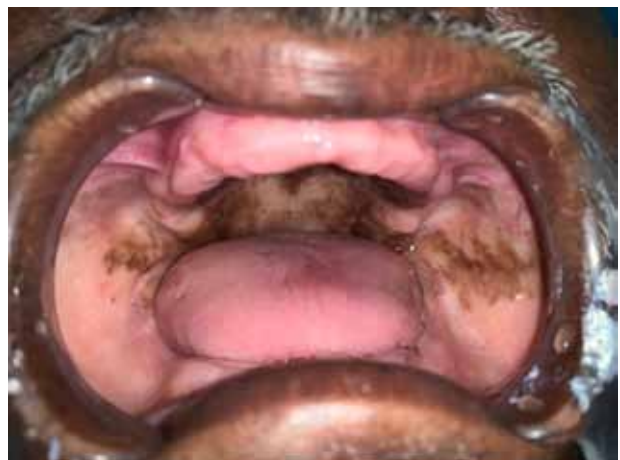

Figure 1 : Anterior flabby ridge present in maxilla

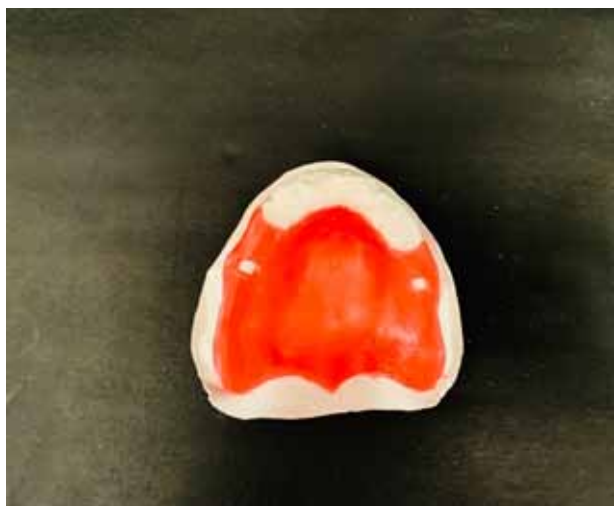

Figure 2: Spacer design excluding the flabby region in the anterior region



Figure 3: Border molding performed

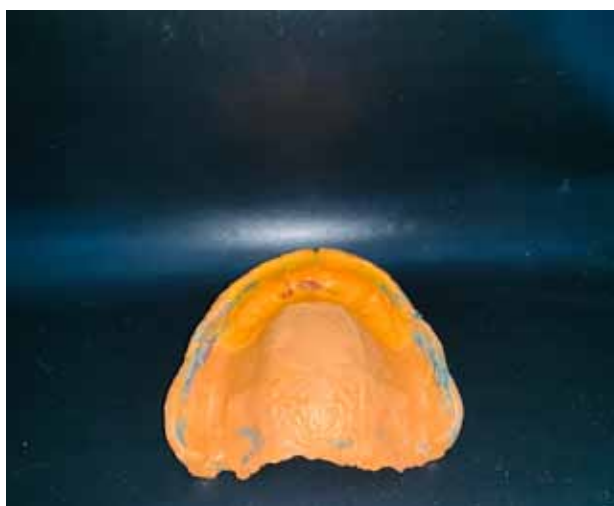

Figure 4: wash impression

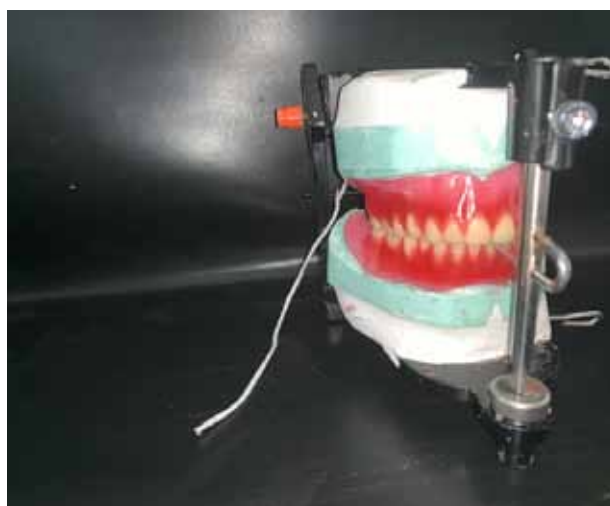


Figure 5: Try In



Figure 6: 1mm thick flexible polyethylene sheet incorporated in the maxillary denture which was 2mm short of borders

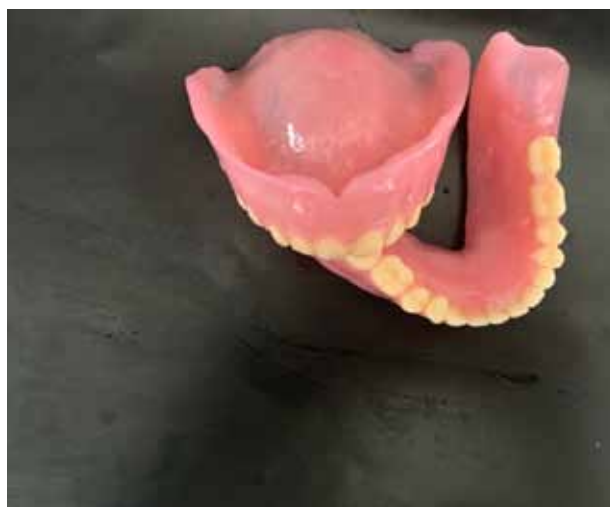

Figure 7: Finished and polished denture

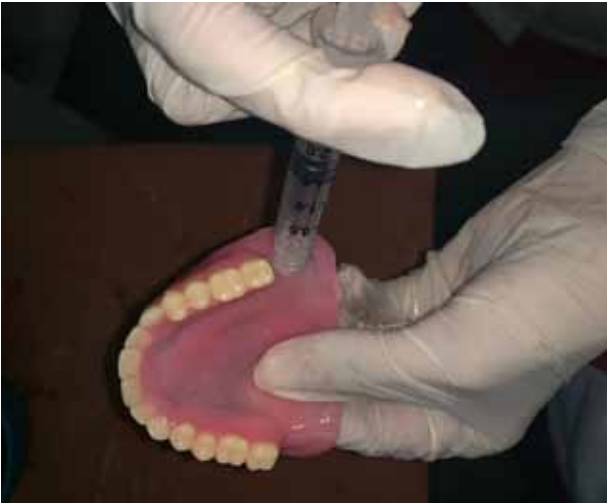

Figure 8: incorporation of glycerine in the denture



Figure 9: patient with final prosthesis

Discussion

Lynch et al in 2006 described an impression technique for management of a denture bearing area that contains flabby tissues. Lynch used those materials which are easily available. The technique which was described by him for management of flabby tissue does not require additional clinical visits compared to fabrication of a conventional complete denture.⁶ When dentures are fabricated using the conventional impression techniques for patients with flabby ridges, the patient often complains of “looseness” of the dentures. The nature of the tissue in flabby ridge is recoiling that it tries to rebound back. Therefore, when we are trying for the fabrication of prosthesis, it can be challenging.

In this case report we have modified the window technique with liquid supported denture which is flexible and it helps in adapting itself to the mucosa. And moreover, when polyethylene sheet is used under the denture, it protects the mucosa from irritation.

Amount of liquid which is injected should be done carefully so that the vertical dimension of patient remains unaltered.

We can even go for the excision of flabby tissues and the resultant ‘shallow’ ridge may provide

retention to lateral forces on the resultant denture. However, according to the concept put forward by DeVan ‘, conservation of what remains, rather than the meticulous replacement of what has been lost’ holds importance in the literature.⁷

Conclusion

Fabrication of retentive complete denture is a prosthodontic challenge in cases of flabby alveolar ridges. Liquid supported denture in these patients improves stability, retention and reduces trauma to the tissue. This modified technique of fabrication of liquid supported denture with window technique is expected to improve life of complete denture under the masticatory forces. Liquid-supported denture with its shock absorbing effect thus fulfils a valuable role in prosthetic dentistry.

References

1. Carlsson G E. Clinical morbidity and sequelae of treatment with complete dentures. *J Prosthet Dent* 1998; 79: 17–23.
2. Xie Q, Narhi T O, Nevalainen J M *et al.* Oral status and prosthetic factors related to residual ridge resorption in elderly subjects. *Acta Odontol Scand* 1997; 55: 306–313.
3. Raghavan R, Shajahan PA, Purushothaman P. Prosthodontic management of flabby tissue

- using modified custom tray design and single impression. *Int J App Sci* 2019; 5(4): 50-53
4. D. A. Atwood, "Post extraction changes in the adult mandible as illustrated by microradiographs of midsagittal sections and serial cephalometric roentgenograms," *J Prosthet Dent*, 1963, 810–824
 5. D. Kakade, S. Athavale, S. Shingote, and B. Dammani, "Liquid-supported denture: a gentle option," *J In Prosthet Sci*, 2007; 7: 35–39
 6. Lynch CD, Allen PF. Management of the flabby ridge: Using contemporary materials to solve an old problem. *Br Dent J* 2006; 200: 258-261
 7. DeVan M M. The nature of the partial denture foundation: Suggestions for its preservation. *J Prosthet Dent* 1952; 2: 210-218