

## TPI Lead Induced Cardiac Perforation, a Nightmare and Change of Practice

Samir Gautam<sup>1</sup>, Sachin Dhungel<sup>2</sup>, Bishal K C<sup>2</sup>, Majhar Khan<sup>1</sup>, Abhishesh Shakya<sup>1</sup>, Rajesh Panjiyar<sup>1</sup>, Deepanjali Sharma<sup>2</sup>

<sup>1</sup>Department of Cardiology, Gautam Buddha Community Heart Hospital, Butwal, Lumbini Province, Nepal, <sup>2</sup>Department of Cardiology, Universal College of Medical Sciences, Bhairahawa, Rupandehi, Nepal

Received: 28<sup>th</sup> February, 2026

Accepted: 25<sup>th</sup> March, 2026

Published: 28<sup>th</sup> June, 2026

### ABSTRACT

Inferior wall myocardial infarction is usually associated with bradycardia. Even sometimes they present with complete heart block or variable degree of heart block. We used to put temporary pacemaker whenever there was significant bradycardia with second or third degree heart block. It used to ease us to deal with bradycardia and hypotension which is usual during percutaneous intervention to right coronary artery. We had nightmare of acute cardiac tamponade and shock following removal of temporary pacemaker lead after successful PCI. Immediate bedside pericardiocentesis was done with fluid resuscitation with survival of patient. This made us change of practice to treat bradycardia and hypotension during PCI with medication rather than with TPI.

**Keywords:** TPI; Bradycardia; PCI; Cardiac Perforation

**Correspondence:** Dr. Samir Gautam, Department of Cardiology, Gautam Buddha Community Heart Hospital, Butwal, Rupandehi, Nepal, Email:samirgautam22@gmail.com, Phone: 977-9852047041.

## INTRODUCTION

Patients with STEMI with second- or third-degree atrioventricular block have higher in-hospital mortality than those without high-degree atrioventricular block.<sup>1,2</sup> Patients who present with ACS and complete heart block have a higher incidence of cardio-genic shock, ventricular arrhythmia, and death.<sup>3,4</sup> In a contemporary cohort of patients with AMI, the incidence of high-degree atrioventricular block has decreased from 4.2% to 2.1%; however, increased morbidity and mortality remain despite reperfusion therapy in those with high-degree atrioventricular block.<sup>5,6</sup> A pooled analysis of 30,000 patients found that high-degree atrioventricular block, asystole, and electromechanical dissociation are infrequent complications of NSTEMI but are associated with increased short-term mortality. High-degree atrioventricular block is not considered to be responsible for the increased mortality but is a surrogate marker of larger infarct size.<sup>7</sup> Temporary pacemaker insertion in the setting of ACS in patients with high-degree atrioventricular block and other pacemaker indications has been found to improve

post discharge survival.<sup>8-10</sup> Permanent pacemaker insertion is recommended with unresolved high-degree atrioventricular block that persists >72 hours.<sup>11</sup>

## CASE PRESENTATION

A 65 years old gentleman presented to nearby hospital with central chest pain for 4 hours duration. He was diagnosed as case of acute myocardial infarction, received antiplatelets Aspirin 300 mg, Clopidogrel 300 mg and Rosuvastatin 40 mg. He was referred to cardiac centre and came to our hospital. There was ongoing chest pain. He was exsmoker and hypertensive on Losartan potassium 50 mg once daily. **Examination:** Pulse 35/minute, BP 80/60 mmHg, SpO2 93% room air, Temp 98 F, RR 22/minute.

**ECG:** STE II,III, AVF, CHB, Bradycardia

**Echocardiography:** LVEF 40%, Hypokinetic inferoseptal and Inferior wall.

**Troponin:** 18.6 ng/ml

**Diagnosis:** Acute Inferior wall STEMI with Cardiogenic Shock with CHB

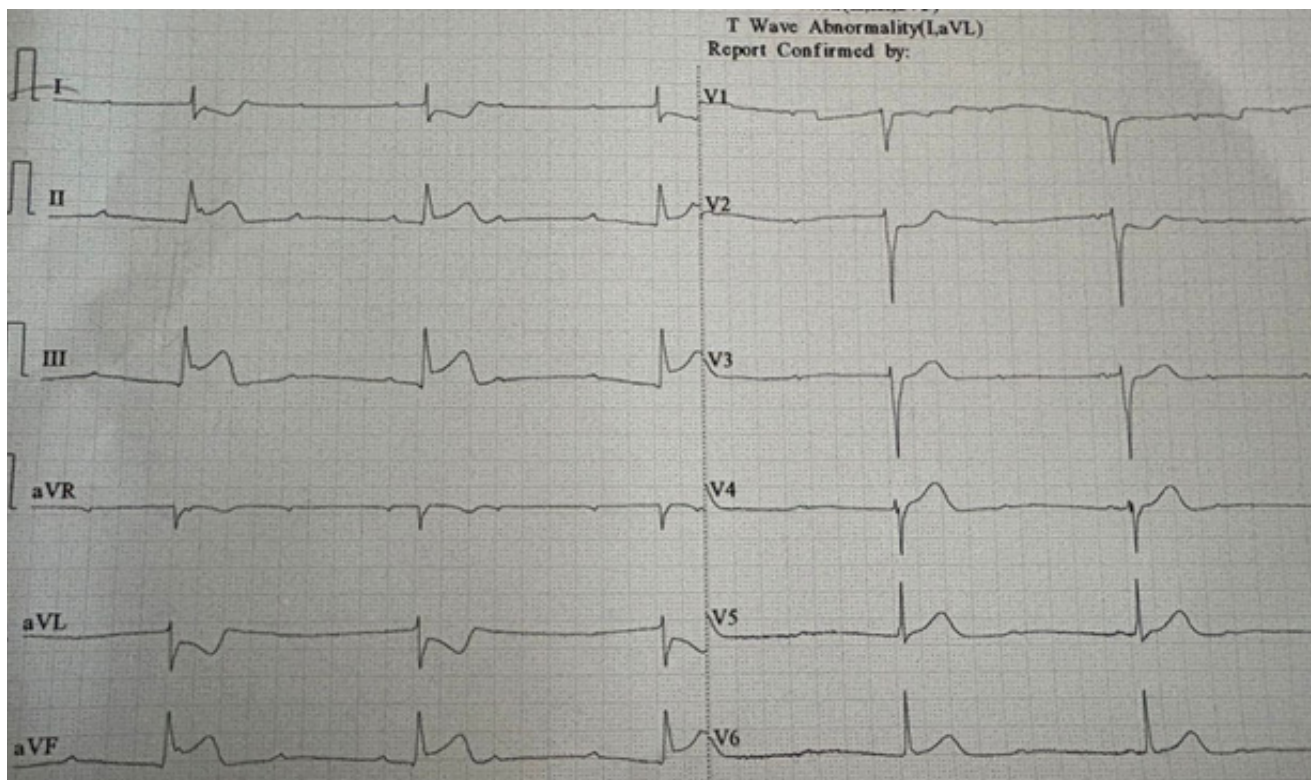
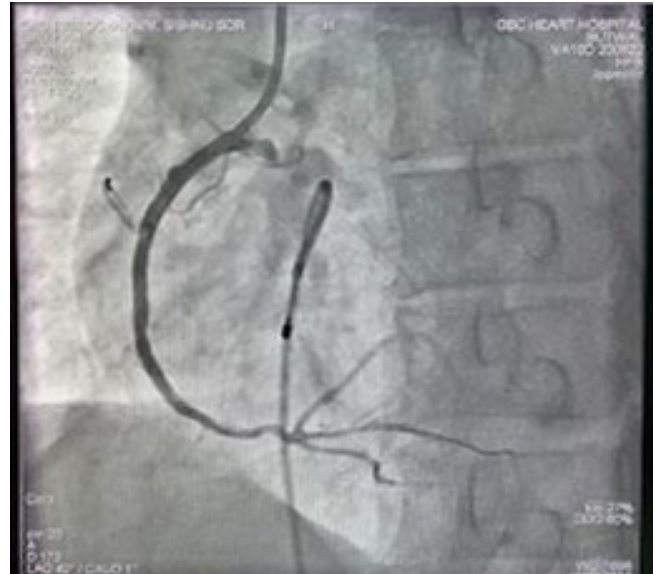
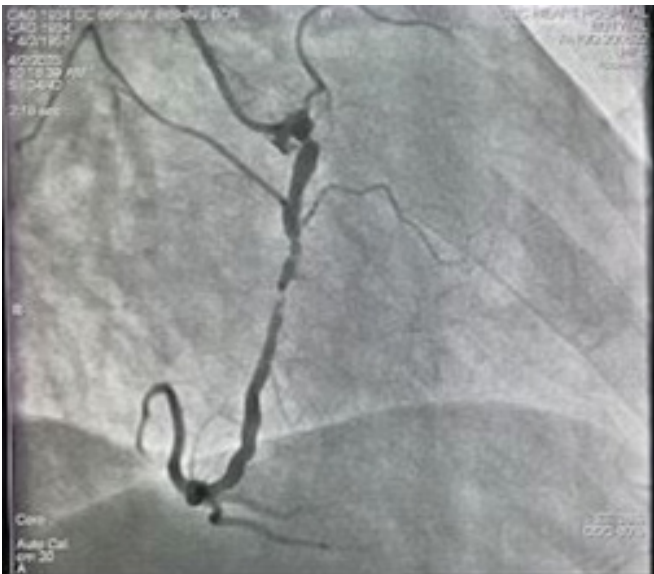
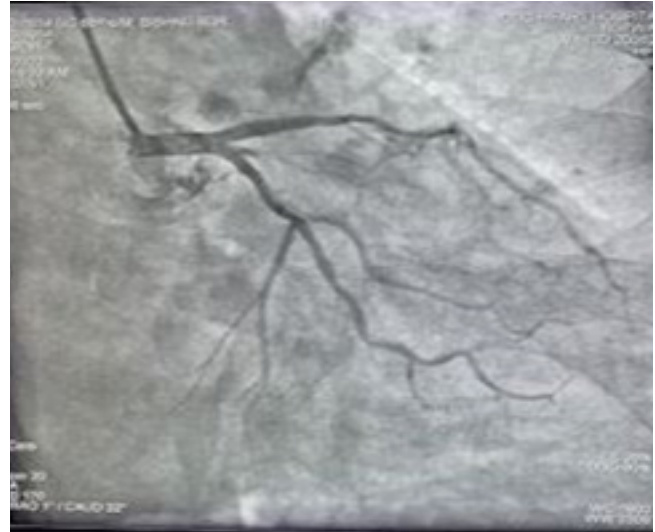
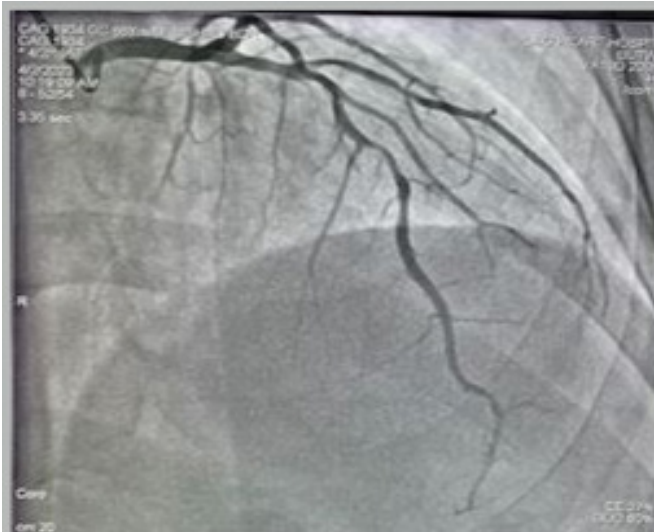Figure 1. Echocardiography of Patients

CAG was done which showed Double vessel disease with RCA mid 95% stenosis and LAD mid part 50-60% stenosis. Planned for Culprit vessel PCI to RCA with stenting. Considering complete heart block with

bradycardia we put on temporary pacemaker before PCI. PCI to RCA with stenting done with good end result and TIMI III distal flow establishment which was uneventful. Patient shifted to CCU. After 4 hours we



planned to remove TPI lead. After removal of TPI lead patient had severe chest discomfort and restlessness. BP 60 mmHg systolic. Fluid resuscitation started. Bedside echo was done which showed pericardial effusion with features of tamponade. Immediate bedside pericardiocentesis was done. Around 70 ml of hemorrhagic fluid (blood) was aspirated. Patient put on inotropes. After 2-3 hours gradually blood pressure improved. Shortness of breath improved. Gradually inotropes tapered over 48 hours. Minimal collection was seen in pericardial space without features of tamponade. He gradually recovered and

discharged on day 4. This was a learning case for us. Thereafter we started medical treatment with early opening of coronary artery even with complete heart block and bradycardia unless patient undergoes CPR with severe bradycardia or cardiac arrest.

## CONCLUSIONS

This case was an eye opener for us telling that putting temporary pacemaker lead in ischemic RV in inferior wall MI might lead to perforation of myocardium causing tamponade and may be life-threatening unless tackled immediately with pericardiocentesis

and resuscitative measures. This also emphasizes on post procedure care is also very important for better outcome. Judicious use of judgement and resources saves life.

**Conflict of interest:** None

**Funding:** None

#### REFERENCE

1. Kim KH., Jeong MH, Ahn Y, et al. Differential clinical implications of high-degree atrioventricular block complicating ST-segment elevation myocardial infarction according to the location of infarction in the era of primary percutaneous coronary intervention. *Korean Circ J.* 2016;46:315-323.[DOI]
2. Auffret V, Loirat A., Leurent G, et al. High-degree atrioventricular block complicating ST segment elevation myocardial infarction in the contemporary era. *Heart.* 2016;102:40-49. [Google Scholar]
3. Aguiar Rosa S, Timóteo AT, Ferreira L, et al. Complete atrioventricular block in acute coronary syndrome: prevalence, characterisation and implication on outcome. *Eur Heart J Acute Cardiovasc Care.* 2018;7:218-223.[DOI]
4. Gang UJ, Hvelplund A, Pedersen S, et al. High-degree atrioventricular block complicating ST-segment elevation myocardial infarction in the era of primary percutaneous coronary intervention. *Europace.* 2012;14:1639-1645. [DOI]
5. Alnsasra H, Ben-Avraham B, Gottlieb S, et al. High-grade atrioventricular block in patients with acute myocardial infarction. Insights from a contemporary multi-center survey. *J Electrocardiol.* 2018;51:386-391. [DOI]
6. Singh SM, FitzGerald G, Yan AT, et al. High-grade atrioventricular block in acute coronary syndromes: insights from the Global Registry of Acute Coronary Events. *Eur Heart J.* 2015;36:976-983. [Google Scholar]
7. Pokorney SD, Radder C, Schulte PJ, et al. High-degree atrioventricular block, asystole, and electro-mechanical dissociation complicating non-ST-segment elevation myocardial infarction. *Am Heart J.* 2016;171:25-32. [DOI]
8. Hynes JK, Holmes Jr DR, Harrison CE. Five-year experience with temporary pacemaker therapy in the coronary care unit. *Mayo Clin Proc.* 1983;58:122-126. [DOI]
9. Ozasa N, Kimura T, Morimoto T, Hou H, Tamura T, Shizuta S, Nakagawa Y, Furukawa Y, Hayashi Y, Nakao K, Matsuzaki M. Lack of effect of oral beta-blocker therapy at discharge on long-term clinical outcomes of ST-segment elevation acute myocardial infarction after primary percutaneous coronary intervention. *The American journal of cardiology.* 2010 Nov 1;106(9):1225-33. [DOI]
10. Wang P, Wang S, Liu Z, et al. Prognostic value of temporary pacemaker insertion in patients with acute myocardial infarction in the era of percutaneous coronary revascularization. *Rev Cardiovasc Med.* 2023;24:179. [DOI]
11. Kusumoto FM, Schoenfeld MH, Barrett C, et al. 2018 ACC/AHA/HRS guideline on the evaluation and management of patients with bradycardia and cardiac conduction delay: a report of the American College of Cardiology/American Heart Association Task Force on Clinical Practice Guidelines and the Heart Rhythm Society. *Circulation.* 2019;140:e382-e482. [Google Scholar]

**Citation:** Gautam S, Dhungel S, KC B, Khan M, Shakya A, Panjiyar R, Sharma D. TPI Lead Induced Cardiac Perforation, a Nightmare and Change of Practice. *JNHLS.* 2026; 5(1):72-75.