

Diagnostic Value of Bronchoalveolar Lavage in Sputum-Smear Negative Pulmonary Tuberculosis

Apar Pokharel,¹ Chhanya Bhandari,¹ Bibek Sharma,¹ Ramesh Bhandari,² Yubraj Paudel³

¹Department of ENT and Head and Neck Surgery, College of Medical Sciences, Chitwan, Nepal, ² Department of ENT and Head and Neck Surgery, Bharatpur Government Hospital, Bharatpur, Chitwan, Nepal, ³Department of Intensive Care Unit, College of Medical Sciences, Bharatpur, Chitwan, Nepal.

Received: 16th July, 2023

Accepted: 14th August, 2023

Published: 31th December, 2023

ABSTRACT

Background: Bronchoalveolar lavage has a high diagnostic utility for cytology and bacteriology. The aim of this study was to assess the diagnostic value of bronchoalveolar lavage (BAL) which underwent routine bronchoscopy for evaluation of lung disease.

Methods: This was a hospital based descriptive study done from July 1, 2022, to June 30, 2023. Eighty bronchoalveolar lavage (BAL) cases were analyzed for differential count, cytological evaluation and bacteriological examination. All cases were included which were sent as BAL specimen to the laboratory department. Bronchoscopy was done as an outpatient procedure and lavage fluid obtained was analyzed.

Results: Out of 80 cases, 51 were male and 29 were female. The age ranged from 10 to 80 years. The prevalence of tuberculosis in sputum smear negative cases was found to be 29%. Among 80 cases, eight cases were unsatisfactory, twenty-three cases were of tuberculosis, one case was of fungal infection, two cases were of malignancy, forty cases were of small airway infection and six cases were satisfactory but with no diagnostic value.

Conclusion: Bronchoalveolar lavage emerged as a valuable diagnostic tool, demonstrating efficacy in diagnosing tuberculosis, infections, and malignancies. The findings underscore the significance of incorporating BAL into routine bronchoscopy procedures for enhanced diagnostic accuracy in the evaluation of lung diseases. This study contributes valuable insights into the diagnostic utility of BAL, emphasizing its role in the comprehensive assessment of pulmonary conditions

Keywords: bronchoalveolar lavage (BAL); bronchoscopy; tuberculosis.

INTRODUCTION

Tuberculosis (TB) remains a major global health concern, causing 1.6 million deaths in 2017.¹ The primary diagnostic method, direct sputum smear microscopy, is widely used.² However, for patients unable to produce sputum or with negative smear results, bronchoalveolar lavage (BAL) provides an alternative for diagnosing pulmonary TB.³⁻⁵ Despite the high TB burden, limited studies in Nepal have explored the importance of BAL in smear-negative pulmonary TB cases.⁶⁻⁸ This study aims to fill this gap by assessing the significance of BAL in patients suspected to have pulmonary TB but with negative sputum smears. Given the dearth of research in this specific context, the findings of this study could contribute valuable insights into improving diagnostic strategies for TB in Nepal, potentially leading to enhanced detection and management of pulmonary TB in smear-negative cases.

METHODS

This study adopted a retrospective observational design to assess the diagnostic value of bronchoalveolar lavage (BAL) in patients suspected to have pulmonary tuberculosis (TB) with negative sputum smears. The research was conducted over a period of one year, with patient recruitment and data collection spanning from July 1, 2022, to June 30, 2023. The study was done in Department of ENT and Head and Neck Surgery. These cases were referred from the Department of Medicine for diagnostic bronchoscopy. Approval for the study was obtained from the Institutional Review Board (Ref. No. 2023/112). Patients aged more than 10 years and suspected of pulmonary TB with negative sputum smear results were included for the study. Individuals with contraindications for flexible bronchoscopy like acute exacerbation of asthma and chronic obstructive pulmonary disease,

Correspondence: Dr. Apar Pokharel, Department of Otorhinolaryngology and Head and Neck Surgery, College of Medical Sciences, Chitwan, Nepal. Email: aparpokharel@hotmail.com, Phone: +977-9841558234.

bleeding disorders and patients on warfarin therapy were excluded from the procedure. The sample size was calculated considering the prevalence of smear-negative pulmonary TB and the expected diagnostic yield of BAL. Convenient sampling technique was used for the study. Subsequent to bronchoscopy, the collected lavage fluid underwent analysis. Air-dried slides stained with Leishman stain were employed for total and differential cell counts. Routine Giemsa and Papanicolaou (PAP) stains were applied for cytology screening, while staining for acid-fast bacilli (AFB) was performed on all BAL samples. The study encompassed all cases sent as BAL specimens to the laboratory department within the stipulated time frame. The adequacy of samples was evaluated based on specific criteria i.e., utilizing Chamberlain et al.'s criteria to categorize samples as unsatisfactory for microscopic evaluation.⁹ These criteria included: 1) Paucity of alveolar macrophages (<10/hpf), 2) Extensive epithelial cells, 3) Mucopurulent exudates, 4) Laboratory artifacts, and 5) Cells altered by degeneration. Demographic information, clinical history, and bronchoalveolar lavage results was recorded using standardized data collection forms.

RESULTS

Bronchoalveolar lavage was performed on 80 cases, with patients ranging from 10 to 80 years old (Figure 1).

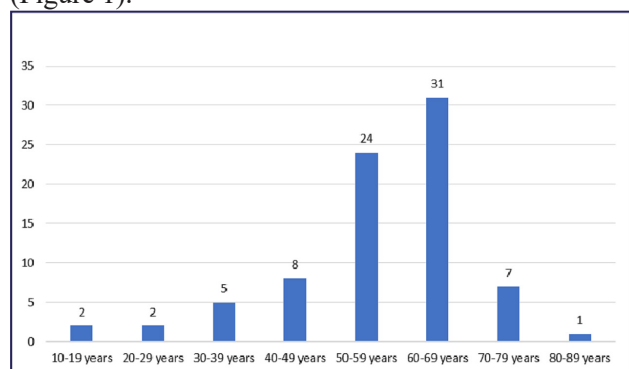


Figure 1. Age distribution of patients.

Among all 51 were males, and 29 were females. Among the cases, eight were deemed unsatisfactory for evaluation. Diagnoses included fungal infection in one case, tuberculosis in 23 cases, malignancy in two cases,

small airway infection in 40 cases, and satisfactory but with no diagnostic value in six cases. The prevalence of tuberculosis in sputum smear negative cases was found to be 29%. In the cellular differential count, a neutrophilic cellular pattern was observed in 42 cases, a lymphocytic cellular pattern in two cases, and an absence of any cellular pattern in 36 cases, including eight unsatisfactory cases. This comprehensive analysis provides insights into the diverse spectrum of conditions encountered through bronchoalveolar lavage across a varied patient demographic (Figure 2).

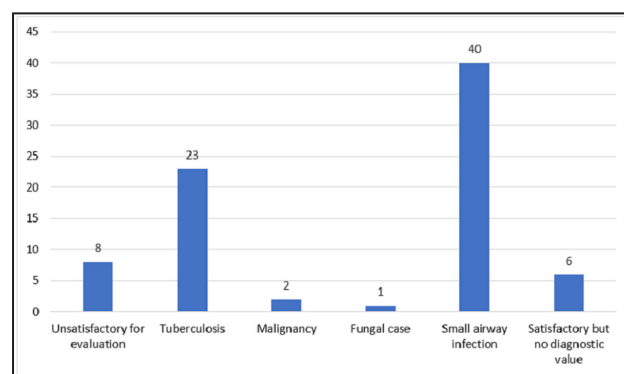


Figure 2. Diagnostic yield of BAL.

DISCUSSION

Bronchoalveolar lavage (BAL) conducted through early flexible bronchoscopy holds a crucial role in both diagnosing and ruling out various uncommon diffuse lung diseases. It is particularly effective in excluding infections in cases where pulmonary infiltrates are unexplained.¹⁰ BAL analysis proves to be a diagnostic tool for infections such as tuberculosis, nocardiosis, and fungal infections, aided by special stains and cultures.¹¹ Numerous studies emphasize the significance of bronchoscopic procedures in promptly diagnosing sputum smear-negative tuberculosis cases. The reported diagnostic yield of BAL in pulmonary tuberculosis ranges up to 57.1% in diverse studies, and the incorporation of nucleic acid amplification techniques can further enhance this yield while reducing diagnostic delays.¹²⁻¹⁵ This study showed only one case of fungal infection. However, diagnosing fungal pneumonia in an intensive care unit setting necessitates careful consideration of the patient's clinical background. The presence of *Candida* in

respiratory samples often indicates colonization rather than pneumonia. Therefore, assessing risk factors such as multiple lumen catheters, peritonitis, prior abdominal surgery, and the administration of broad-spectrum antibiotics becomes essential to determine the necessity of antifungal therapy.^{16,17}

In our investigation, a significant number of cases exhibited a neutrophil-rich pattern but tested negative for acid-fast bacilli on smears and GeneXpert, as well as mycobacterial and fungal cultures. This suggests an inflammatory or bacterial etiology. The average total cell count in these cases exceeded that of tuberculosis with a neutrophilic cellular pattern. Further exploration and management were tailored to the clinical profiles of the patients. Although a neutrophil count of $\geq 50\%$ strongly indicates infectious etiology or acute lung injury, BAL neutrophilia can sometimes signify a progressive course of certain interstitial lung diseases, such as idiopathic pulmonary fibrosis or connective

tissue disorder-associated ILD.^{12–15,18} Additionally, our study identified two cases of malignancy or suspicion of malignancy through BAL fluid analysis. The diagnostic yield for malignancy is reported to be higher in cases of endobronchial tumors or tumors situated in central regions. Furthermore, performing the procedure on affected lobes/segments, accompanied by high-resolution computed tomography (HRCT) correlation, can enhance the overall diagnostic yield of BAL.¹⁹

CONCLUSIONS

Bronchoalveolar lavage demonstrates a significant diagnostic yield for tuberculosis, fungal infections, and malignancies. Given its efficacy in establishing a definitive diagnosis in numerous previously undiagnosed cases, bronchoalveolar lavage should be incorporated as a routine diagnostic tool for lung diseases, particularly to exclude pulmonary tuberculosis.

REFERENCES

1. Geneva: World Health Organization. Global tuberculosis report 2018. <https://iris.who.int/handle/10665/274453>. 2018.
2. Geneva: World Health Organization. WHO. Automated real-time nucleic acid amplification technology for rapid and simultaneous detection of tuberculosis and rifampicin resistance: Xpert MTB/RIF system: policy statement. <https://apps.who.int/iris/handle/10665/44586>. 2011.
3. de Gracia J, Curull V, Vidal R, Riba A, Orriols R, Martin N, et al. Diagnostic value of bronchoalveolar lavage in suspected pulmonary tuberculosis. *Chest*. 1988 Feb;93(2):329–32. <https://doi.org/10.1378/chest.93.2.329>
4. Charoenratanakul S, Dejsomritrutai W, Chaiprasert A. Diagnostic role of fiberoptic bronchoscopy in suspected smear negative pulmonary tuberculosis. *Respir Med*. 1995 Oct;89(9):621–3. [https://doi.org/10.1016/0954-6111\(95\)90231-7](https://doi.org/10.1016/0954-6111(95)90231-7)
5. Theron G, Peter J, Meldau R, Khalfey H, Gina P, Matinyena B, et al. Accuracy and impact of Xpert MTB/RIF for the diagnosis of smear-negative or sputum-scarce tuberculosis using bronchoalveolar lavage fluid. *Thorax*. 2013 Nov;68(11):1043–51. <https://doi.org/10.1136/thoraxjnl-2013-203485>
6. Dhakal SS, Neupane A, Chaudhary S, Mishra N, Karki DB. Utility of Bronchoalveolar Lavage in the Diagnosis of Sputum Negative Pulmonary Tuberculosis. *Journal of Universal College of Medical Sciences*. 2020;8(01):21. <http://doi.org/10.3126/jucms.v8i1.29828>
7. Acharya S, Yogi S. Diagnostic Value of Bronchoalveolar Lavage. *Journal of Nepalgunj Medical College*. 2017;15(1):29–31.
8. Chaudhary R, Bhatta S, Singh A, Pradhan M, Shrivastava B, Singh YI, et al. Diagnostic performance of GeneXpert MTB/RIF assay compared to conventional Mycobacterium tuberculosis culture for diagnosis of pulmonary and extrapulmonary tuberculosis, Nepal. *Narra J*. 2021;1(2):e33. <https://doi.org/10.52225/narra.v1i2.33>
9. Chamberlain DW, Braude AC, Rebeck AS. A critical evaluation of bronchoalveolar lavage. Criteria for identifying unsatisfactory

- specimens. *Acta Cytol.* 1987;31(5):599–605.
10. Desai H, Smith J, Williams MD. Diffuse Alveolar Hemorrhage. In: Hyzy RC, McSparron J, editors. Evidence-Based Critical Care [Internet]. Cham: Springer International Publishing; 2020. p. 253–7. https://link.springer.com/10.1007/978-3-030-26710-0_33
 11. Zaidi A, Kaur H, Gupta P, Gupta N, Srinivasan R, Dey P, et al. Role of bronchoalveolar lavage in diagnosing pulmonary infections and malignancies: Experience from a tertiary care center. *Diagn Cytopathol.* 2020 Dec;48(12):1290–9. <https://doi.org/10.1002/dc.24574>
 12. Malekmohammad M, Marjani M, Tabarsi P, Baghaei P, Sadr Z, Naghan PA, et al. Diagnostic yield of post-bronchoscopy sputum smear in pulmonary tuberculosis. *Scand J Infect Dis.* 2012 May;44(5):369–73. doi/full/10.3109/00365548.2011.643820
 13. Kalawat U, Sharma KK, Reddy PNR, Kumar AG. Study of bronchoalveolar lavage in clinically and radiologically suspected cases of pulmonary tuberculosis. *Lung India.* 2010 Jul;27(3):122–4. doi: 10.4103/0970-2113.68307
 14. Radha S, Afroz T, Prasad S, Ravindra N. Diagnostic utility of bronchoalveolar lavage. *J Cytol.* 2014 Jul;31(3):136–8. doi: 10.4103/0970-9371.145636
 15. Bhatia GC, Hemvani N, Chitnis DS. Role of bronchoalveolar lavage in pulmonary infections. *Lung India.* 2006;23(4):147–50.
 16. Shamim S, Agarwal A, Ghosh BK, Mitra M. Fungal pneumonia in intensive care unit: when to suspect and decision to treatment: a critical review. *The Journal of Association of Chest Physicians.* 2015;3(2):41–7. DOI: 10.4103/2320-8775.158837
 17. De Pauw B, Walsh TJ, Donnelly JP, Stevens DA, Edwards JE, Calandra T, et al. Revised definitions of invasive fungal disease from the European Organization for Research and Treatment of Cancer/Invasive Fungal Infections Cooperative Group and the National Institute of Allergy and Infectious Diseases Mycoses Study Group (EORTC/MSG) Consensus Group. *Clin Infect Dis.* 2008 Jun 15;46(12):1813–21. DOI: 10.1086/588660
 18. Watters LC, Schwarz MI, Cherniack RM, Waldron JA, Dunn TL, Stanford RE, et al. Idiopathic pulmonary fibrosis. Pretreatment bronchoalveolar lavage cellular constituents and their relationships with lung histopathology and clinical response to therapy. *Am Rev Respir Dis.* 1987 Mar;135(3):696–704.
 19. George J, Umashankar T. Diagnostic Utility of Bronchoalveolar Lavage and Bronchial Brush Cytology in Lung Lesions. 2020;A394-9. DOI: 10.21276/APALM.2710

Citation: Pokharel A, Bhandari C, Sharma B, Bhandari R, Paudel Y. Diagnostic Value of Bronchoalveolar Lavage in Sputum-Smear Negative Pulmonary Tuberculosis. *JNHLS.* 2023; 2(2):77-80.