

# Accidental Ingestion of a Dental Bur during Endodontic Procedure: A Case Report

Sanchita Khadka,<sup>1</sup> Bandana Koirala,<sup>2</sup> Sneha Shrestha,<sup>3</sup> Gajendra Birajee<sup>4</sup>

<sup>1</sup>Post-graduate Resident, <sup>2</sup>Professor and Head, <sup>3,4</sup>Assistant Professors

<sup>1-4</sup>Department of Pedodontics and Preventive Dentistry, College of Dental Surgery,

B. P. Koirala Institute of Health Sciences, Dharan, Nepal.

## ABSTRACT

Accidental ingestion of dental materials and instruments during the routine dental procedures especially in young children can occur at any time. The aim of this case report was to highlight on the recognition and management of such condition immediately for the prevention of any adverse complications. A 3-year-old male child accidentally swallowed a round diamond bur that popped out of the air-rotor handpiece during access cavity preparation on 65. There were no signs of airway obstruction and immediate postero-anterior view of chest and abdomen showed the presence of bur in the gastrointestinal tract which got eliminated in stool on the fourth day, uneventfully.

**Keywords:** Accidental ingestion; airway obstruction; gastrointestinal tract; round diamond bur.

## INTRODUCTION

Accidental ingestion/aspiration of foreign bodies during the routine clinical practices are unpredictable and can occur despite all the precautionary measures taken.<sup>1</sup> These foreign bodies can be of various sizes, shapes, and sharpness and can get lodged anywhere in the gastrointestinal (GI) or the respiratory tract.<sup>1,2</sup> According to the studies, foreign bodies pass through GI tract without difficulty with 10-20% requiring nonsurgical intervention, whereas less than 1% mandate surgical retrieval.<sup>1,2</sup> This case reports the management of accidental ingestion of a round diamond bur in a 3-year-old child during the endodontic procedure with a successful outcome of its excretion in stool uneventfully.

## CASE REPORT

A 3-year-old male child reported to the Department

of Pedodontics and Preventive Dentistry with a chief complaint of pain on the upper left back teeth since three days along with extraoral swelling on the left side of face since one day. There was decreased intake of food and physical activity of the child who was under oral antibiotics and analgesics prescribed from a nearby local pharmacy.

On examination, mild extraoral swelling was present on the left side of face secondary to deep caries on 64, 65. Mobility was present on 64 and severe tenderness to percussion was on 65. Panoramic radiographic examination showed pulpal involvement on both 64 and 65 for which pulpectomy was planned and advised. It was the first dental visit of the child and he had a definitely negative behaviour (Frankl's behaviour rating scale 1).<sup>3</sup> With the parental consent, pulpectomy was planned to be done under local anaesthesia.

Various behaviour guidance techniques (tell-show-do, distraction) were used to guide the patient's behaviour for the intended endodontic procedure. After having the patient seated on dental chair with his parents by his side for active protective stabilization, local anaesthesia was administered. Thereafter, the access cavity was being prepared on 65 with a round diamond bur in an airtor hand-piece (push-button type) when suddenly the bur popped out and fell into the patient's oral cavity. The procedure was immediately aborted with the child's head

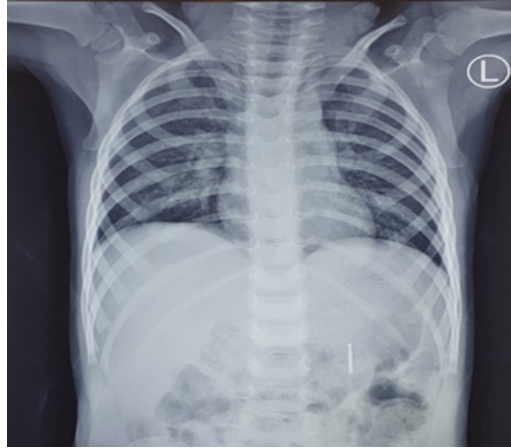
## Correspondence



Dr. Sanchita Khadka  
Post-graduate Resident,  
Department of Pedodontics and Preventive Dentistry,  
B.P. Koirala Institute of Health Sciences,  
Dharan, Nepal  
Email: sanchitakdka123@gmail.com

## Citation

Khadka S, Koirala B, Shrestha S, Birajee G. Accidental Ingestion of a Dental Bur during Endodontic Procedure: A Case Report. *J Nepal Assoc Pediatr Dent.* 2022;3(1):32-5.

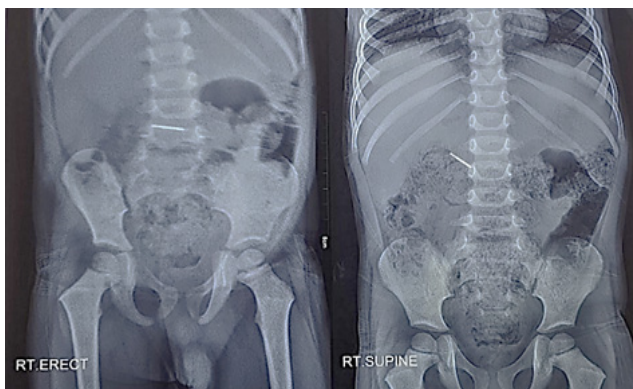


**Figure 1.** Immediate chest and abdominal radiograph showing the evidence of bur in stomach.

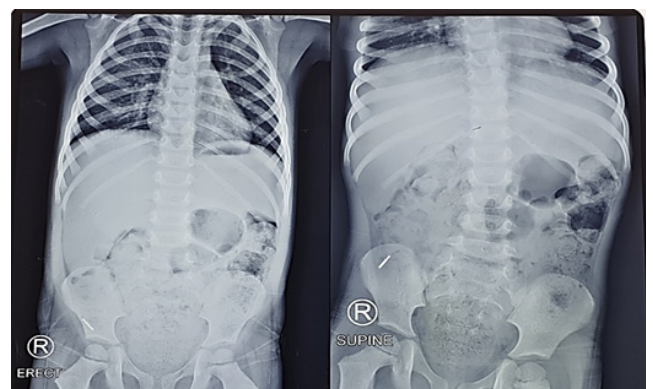
titled to one side to collect the dropped bur but it was no more visible in the oral cavity. He was then kept upright and patted on his back to cough out the bur but it could not be retrieved as the child had already ingested it.

The patient had no any symptoms of airway obstruction like cough, dyspnoea, drooling of saliva or respiratory distress. He was then immediately taken to the Department of Radiology of the hospital for postero-anterior (PA) view radiograph of the chest and abdomen. X-ray report of the patient confirmed the presence of a radio-opaque foreign body in the gastro-intestinal tract (Figure 1). As the ingested bur was small (19 mm in length), blunt and the patient had no any adverse symptoms, wait and watch approach was advised by both the paediatric surgeons and the gastroenterologists.

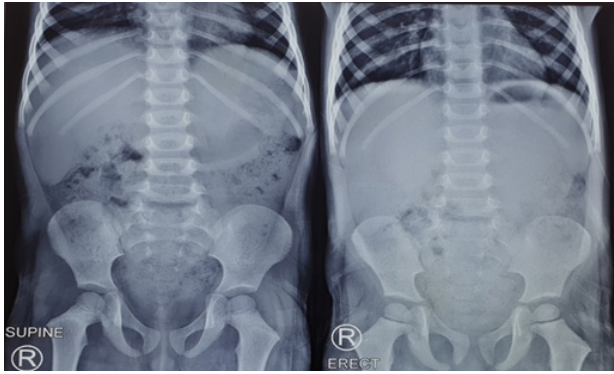
However, the patient’s parents was anxious about the situation thus the parents were properly explained about the condition and counselled, who showed positive co-operation after active counselling and the child was kept under continuous observation in the Paediatric Emergency. The child had a history of constipation. Thus, excessive intake of high fiber diet like banana and water was advised for the easy discharge of the foreign body and the parents were advised to examine stool after each defecation. Close monitoring of the patient was done throughout the hospital stay and serial abdominal radiographs were performed after each 24 hours which showed progressive changes in the position of the dental bur in the GI tract (Figure 2,3). The child remained asymptomatic throughout the stay and finally, he passed the ingested bur in the stool on the fourth day, uneventfully (Figure 4,5).




**Figure 2.** Abdominal radiograph on 2<sup>nd</sup> day showing the bur in small intestine.



**Figure 3.** Abdominal radiograph on 3<sup>rd</sup> day showing the bur in ascending colon.



**Figure 4.** Abdominal radiograph on 4<sup>th</sup> day, with the bur eliminated.



**Figure 5.** Ingested round diamond bur, after retrieval in the stool on the 4<sup>th</sup> day.

## DISCUSSION

In dentistry, patients are generally treated in a supine or semi-recumbent position to improve visibility and accessibility to the oral cavity. Accidental ingestion/aspiration of the foreign body can occur not only during the dental treatment but the risks may persist anytime as patients wear dental appliances or prosthesis in their mouth.<sup>1</sup> Foreign body ingestion occurs in young children between the ages of six months and three years. It may also occur in the elderly, sedated, mentally challenged, and traumatized patients due to a weakened gag reflex, swallowing in coordination, or a compromised protective airway mechanisms.<sup>1,4</sup>

The present case was the accidental ingestion of dental bur in a 3-year-old child while preparing the access cavity under local anesthesia (LA) despite the immediate attempts to retrieve it from the oral cavity. Literature have reported the ingestion of various foreign bodies like tooth as a whole, root tips, burs, endodontic posts, impression materials, temporary restorations, dental inlays or crowns, fixed or removable denture, air-water syringe tips, dental clamps, hand files or reamers, apex locator lip clips, orthodontic brackets, and also implant components during the dental treatments.<sup>1,2</sup> The significant contributing factors to the ingestion of foreign bodies in dentistry are difficult handling of small slippery (saliva contact) instruments in a confined working area, excessive or unexpected patient movements during the treatment, limited mouth opening, and unexpected breakage or detachment of poor quality instruments or their components.<sup>1</sup> The excessive movement of the child during the treatment, continuous crying due to definitely negative behaviour and the sudden bite on the air rotor hand piece (push-button type) could be

the predisposing factors that led to the accidental popping and ingestion of bur in this case.

The patient showed no any signs of airway obstruction and was taken immediately to the radiology department for chest and abdomen radiograph which showed the presence of ingested bur in the stomach itself. According to Webb et al.<sup>5</sup>, 92.5% of the swallowed foreign materials enter the GI tract, with about 7.5% ending up in the tracheobronchial tree. When the accidental slippage of instruments occur, the patient's head should be tilted sideways to collect the dropped object preventing it from entering the oropharynx.<sup>6</sup> If this fails, patient should be monitored continuously by communicating and checking for breathing patterns to ensure uncompromised airway and in case of emergency situation, we should be trained to perform the Heimlich manoeuvre to remove the object and call for immediate medical assistance.<sup>6</sup>

The child was kept under observation in the Paediatric Emergency and serial abdominal radiographs taken at regular intervals of 24 hours showed the progressive changes in the position of bur which eventually passed out in the stool on the fourth day, uneventfully. The patients should keep an eye on the faeces to ensure that the foreign body has been eliminated.<sup>1</sup> Majority of the foreign bodies (80-90%) have been shown to pass out easily through the GI tract after moving down the oesophagus over several days to weeks.<sup>1,8</sup>

The ingested bur was blunt (round) in this case and the risk of perforation was minimal, thus a wait and watch approach was advised until the passage of bur in the stool. If the swallowed object is sharp, pointed and elongated, it may lead to perforations which can become lethal and

may warrant surgical interventions.<sup>1,2,8</sup> Thus, periodic evaluation and serial radiographic monitoring of the progress of such an object is highly recommended and was done in this case too.

The present case did not show obstruction at any site of the GI tract which led to successful passage of the foreign body through the stool with no any active intervention. The potential sites of obstruction are pharynx, upper oesophageal sphincter, middle third of the oesophagus, lower oesophageal sphincter, pylorus, duodenojejunal flexure, ileocecal junction, appendix, rectosigmoid junction, anus, or patients with previous GI surgery or congenital gut malformations.<sup>1,8,9</sup> Dysphagia and odynophagia are the most common symptoms associated with any obstruction.<sup>1</sup> The symptoms may vary between abdominal pain, fever, nausea, vomiting, and abdominal distension depending on the site of obstruction.<sup>1</sup> However in this case, the child remained asymptomatic throughout the stay.

The child had a history of constipation. Thus, excessive intake of high fiber diet like banana and water was advised. Purgatives/laxatives were not advised since they increase the peristaltic contraction effect, which in turn increases the risk for intestinal perforations.<sup>1</sup> Finally, proper documentation is deemed mandatory for reducing culpability in the event of a lawsuit.<sup>7</sup>

Prevention is the best method to minimize any accidental ingestion of foreign bodies. Use of rubber dam, gauze

throat screen, tying of floss ligature on rubber dam clamps, hand files, crowns, elastic separators, space maintainer equipments, with proper inspection of instrument locking in handpieces and utilizing high evacuation suction are some of the methods to avoid accidental instrument or material ingestion.<sup>1,10</sup> Thus, clinician treating children must follow all the precautionary measures possible to prevent the accidental mishaps to occur during the dental procedures especially in pre-cooperative child, with behavioural issues, hypersalivation and while working on upper arch of mouth.

## CONCLUSION

Ingestion of foreign bodies are often unpredictable during the dental procedures. Being a dentist, we need to be well trained to manage such medical emergencies. Immediate recognition of the ingestion of bur, its favourable position in the GI tract along with good co-operation from patient and parents during the entire four days of the hospital stay were the keys to the successful management in this case.

## ACKNOWLEDGMENTS

We would like to acknowledge the Department of Paediatric Surgery, Department of Gastroenterology and Department of Radiodiagnosis and Medical Imaging for their needful medical consultation and support.

## Conflict of Interest: None

JNAPD

## REFERENCES

1. Yadav RK, Yadav HK, Chandra A, Yadav S, Verma P, Shakya VK. Accidental aspiration/ingestion of foreign bodies in dentistry: A clinical and legal perspective. *National Journal of Maxillofacial Surgery*. 2015 Jul;6(2):144. [[PubMed](#) | [Full Text](#) | [DOI](#)]
2. Dionysopoulos D. Accidental ingestion and aspiration of foreign objects during dental practice. *Stomatological Disease and Science*. 2017 Sep 29;1:87-9. [[Full Text](#) | [DOI](#)]
3. Shindova MP, Belcheva AB. Behaviour evaluation scales for pediatric dental patients-review and clinical experience. *Folia medica*. 2014 Oct 1;56(4):264. [[DOI](#)]
4. Panse A, Jathar P, Metha D. Accidental ingestion of instruments in pediatric dental patients: report of three cases. *Journal of dental and allied sciences*. 2012 Jul 1;1(2):79. [[Full Text](#)]
5. Webb WA, McDaniel L, Jones L. Foreign bodies of the upper gastrointestinal tract: current management. *Southern Medical Journal*. 1984 Sep 1;77(9):1083-6. [[PubMed](#)]
6. Kunaparaju K, Shetty K, Jathanna V, Nath K. Endoscopic retrieval of an accidentally ingested bur during a dental procedure: a case report. *Patient safety in surgery*. 2021 Dec;15(1):1-4. [[PubMed](#) | [Full Text](#) | [DOI](#)]
7. Hill EE, Rubel B. A practical review of prevention and management of ingested/aspirated dental items. *Gen Dent*. 2008 Nov 1;56(7):691-4. [[PubMed](#)]
8. Ikenberry SO, Jue TL, Anderson MA, Appalaneni V, Banerjee S, Ben-Menachem T, Decker GA, Fanelli RD, Fisher LR, Fukami N, Harrison ME. Management of ingested foreign bodies and food impactions. *Gastrointestinal endoscopy*. 2011 Jun 1;73(6):1085-91. [[PubMed](#) | [Full Text](#) | [DOI](#)]
9. Benjamin SB. Small bowel obstruction and the Garren-Edwards gastric bubble: an iatrogenic bezoar. *Gastrointestinal endoscopy*. 1988 Nov 1;34(6):463-7. [[PubMed](#) | [Full Text](#) | [DOI](#)]
10. Venkataraghavan K, Anantharaj A, Praveen P, Rani SP, Krishnan BM. Accidental ingestion of foreign object: Systematic review, recommendations and report of a case. *The Saudi dental journal*. 2011 Oct 1;23(4):177-81. [[PubMed](#) | [Full Text](#) | [DOI](#)]