


# Chest X-Ray Findings and Severity Score of Patients with Respiratory Symptoms in COVID-19 Intensive Care Unit of a Teaching Hospital


• Umesh Kumar Sharma<sup>1</sup> • Suraj Thapaliya<sup>1</sup> • Manmohan Bir Shrestha<sup>1</sup> • Raju Shrestha<sup>2</sup> • Laxman Thakur<sup>3</sup>  
• Ujwal Rai<sup>4</sup> • Jitendra Kumar Singh<sup>5</sup>

Submitted 21 June 2022

Accepted 18 October 2022

Published 2 November 2022

 **Umesh Kumar Sharma**  
druksharma@hotmail.com

 <https://orcid.org/0000-0003-2566-2345>

<sup>1</sup> Department of Radiodiagnosis, B & C Teaching Hospital, Birtamode, Nepal.

<sup>2</sup> Department of Critical Care, B & C Teaching Hospital, Birtamode, Nepal.


<sup>3</sup> Department of Medicine, B & C Teaching Hospital, Birtamode, Nepal.


<sup>4</sup> Department of Pathology, B & C Teaching Hospital, Birtamode, Nepal.

<sup>5</sup> Department of Community Medicine, Janaki Medical College, Janakpur, Nepal.

## Citation

“Sharma UK, Thapaliya S, Shrestha MB, Shrestha R, Thakur L, Rai U, et al. Chest X-ray findings and severity score of patients with respiratory symptoms in covid-19 intensive care unit of a teaching hospital. *JBPkiHS*. 2022;5(1):41-47”

 <https://doi.org/10.3126/jbpkihs.v5i1.45328>



This work is licensed under a Creative Commons Attribution-NonCommercial 4.0 International License.

## Abstract

**Background:** Chest X-rays are important for tracking the progression of lung abnormalities, particularly in critically ill COVID-19 patients in the intensive care units (ICU). We aimed to assess correlation of chest X-ray findings with the COVID-19 disease severity and outcome.

**Methods:** This prospective observational study was conducted at B & C Teaching Hospital, Birtamode from 15 March to 15 July 2021. All diagnosed COVID-19 patients admitted in the ICU for respiratory distress with oxygen saturation < 90% and evaluated by portable X-rays were enrolled. The radiographic findings were evaluated for the distribution and patterns of affection, and the total severity score was calculated using RALE scales of 0 - 8 and Brixia scales of 0 - 18. The scores were then compared between the expired and improved patients.

**Results:** The age of patients (mean ± SD) was 48.2 ± 13.84 years. During the first four days of hospitalization, there was no significant difference in Brixia score (p = 0.793) or RALE score (p = 0.842) between expired and improved patients. The differences in both (Brixia and RALE) scores grew with each passing day (p < 0.05). The Brixia and RALE severity scores had a strong positive correlation at various stages of disease in both expired and improved patients. (r > 0.75, p < 0.001).

**Conclusion:** In resource limited setting, the severity scores (RALE or Brixia) can be used as a quantitative method of the extent of COVID-19 pneumonia, correlating with an increased risk of ICU admission.

**Keywords:** COVID-19; Chest X-ray; Severity score (Brixia and RALE)

## Declarations

**Ethics approval and consent to participate:** Ethical approval was obtained from Ethical Committee of B & C Hospital, Birtamode, Nepal (Ref. no.: 1243/ 078/ 079). Consent of patients was waived for the study.

**Consent for publication:** Not applicable.

**Availability of data and materials:** The data supporting the findings of this article will be made available upon request.

**Competing interest:** None

**Funding:** None

**Authors' contributions:** UKS: concept, design, and definition of intellectual content. ST: literature search, data analysis. RS: clinical studies. LT: clinical studies, manuscript preparation. UR: manuscript preparation and edit. JKS: statistical analysis, manuscript edit. All the authors have read and approved the final manuscript.

Coronavirus disease (COVID-19) is an infectious disease caused by the SARS-CoV-2 virus. The clinical spectrum of COVID-19 ranges from asymptomatic to mild, moderate and severe disease that led to severe respiratory distress. At least one-third of those who are afflicted do not show any signs or symptoms [1]. The majority of patients (about 81%) who develop symptoms noticeable enough to be classified as mild to moderate symptoms (up to mild pneumonia), whereas 14% have severe symptoms (dyspnea, hypoxia, or more than 50% lung involvement on imaging), and 5% have critical symptoms (shock, respiratory failure or multiorgan dysfunction) [2].

Although chest X-ray (CXR) is less sensitive for detecting pulmonary involvement in early-stage disease, it is beneficial for monitoring the rapid progression of lung abnormalities in COVID-19, particularly in critically ill patients in intensive care unit (ICU). Chest radiography is recommended by the British Society of Thoracic Imaging (BSTI) for all seriously ill patients (oxygen saturation less than 94 percent, National early warning score (NEWS) >3) and if “clinically indicated” [3].

Computed tomography (CT) findings in COVID-19 are largely evaluated because they are more sensitive than CXR results, especially in the initial assessment of patients. Chest CT could provide a more accurate diagnosis of severe lung diseases in COVID-19 with a sensitivity of 83.3% and a specificity of 94% [4]. The reliance on CT places a significant load on radiology departments, hence this makes CXRs a substitute for the CT examination. Because of limited resources for CT scans, especially in underdeveloped countries like Nepal, CXR can be a great substitute for diagnosing and determining the severity and course of COVID-19 lung abnormalities. A severity score was calculated in different centers by adapting and simplifying the Brixia and RALE to quantify the extent of infection [5-9]. The primary objective was to assess the correlation of CXR findings with the COVID-19 disease severity and outcome.

## METHODS

After ethical approval from the institutional review committee of B & C teaching hospital, Birtamode, Nepal, this single-center prospective observational study was conducted on all patients admitted to the COVID -19 ICU from 15 March to 15

July 15 2021. RT-PCR-confirmed COVID-19 patients with respiratory symptoms, positive CXR abnormalities and oxygen saturation of less than 90% were included. Patients were excluded if they had a lung disease other than COVID-19 or if their clinical information were incomplete or unidentified. As the study involved hospital records only with no personal identifiers, informed consent was waived. Complete enumeration method was chosen for sampling.

All CXRs were generated using standard protocol and techniques for AP projection using portable X-ray units. The radiographic findings were analyzed by two radiologists, one with an experience of 21 years and another radiologist with 7 years. On CXR, the zones of predominance of the lesions were classified as upper, middle, lower, and diffuse. The radiographic results were classified as (i) peripheral predominance, central predominance, or neither; (ii) right, left, or bilateral lung affliction; and (iii) upper, middle, and lower zonal predominance or diffuse lung involvement. The affected lungs were assessed for the presence of ground glass opacities (GGO), reticular interstitial thickening, consolidation, and pulmonary nodules as well as the associated pleural effusion or pneumothorax & pneumomediastinum.

The changes in the radiographic findings during their stay were evaluated by classifying the duration of stay of patients in ICU as 1 to 4 days, 5 to 9 days, 10 to 15 days, and >15 days. The degree of disease severity was assessed using the severity score proposed by Warren et al. [9]. The level of lung involvement was determined by assigning a score of 0 to 4 to each lung (score 0 = no involvement; 1 = 25%; 2 = 25% to 50%; 3 = 50 to 75%; 4 = 75% lung affection). Summing both lung scores yielded a total severity score (total severity scores ranged from 0 to 8).

The lungs were separated into six regions using the Brixia scoring system [5]. The lungs were divided into six sections by two lines drawn at the level of the inferior wall of the aortic arch and the right inferior pulmonary vein. Radiologists assign a score of 0 to 3 to each region based on the severity of the lesion. 0 indicates no lung abnormalities, 1 indicates interstitial infiltrates, 2 indicates interstitial and alveolar infiltrates (interstitial dominant), and 3 indicates interstitial and alveolar infiltrates (interstitial dominating) (alveolar dominant). The score ranges from 0 to 18, with 0 being the lowest and 18 being the highest. Other findings, such as pleural effusion and pulmonary vessel enlargements,

were not included in the Brixia scoring system. The severity of chest X-rays (Brixia and RALE) at various stages of disease during therapy was assessed between expired and improving patients [5, 9].

The patients were divided into four groups according to age: <20years, 20 to 39years, 40 to 59 and  $\geq 60$  years. The patients' outcome was correlated to the highest CXR overall severity score, as measured by Brixia and RALE. Non-invasive ventilation as well as invasive ventilation and duration of stay were assessed with severity score among expired patients.

Data are presented as frequency (percentage) for categorical variables whereas mean with standard deviation for continuous variables. Independent t-tests are used to compare improved with expired patients. The Pearson correlation coefficient was used to observe the correlation between the Brixia and RALE score. Statistical significance was concluded at the two-sided significance level of 0.05. All the analysis were performed with SPSS version 21 (IBM, Armonk, NY, USA).

## RESULTS

A total of 70 patients were enrolled and there was no missing data. Their age ranged from 18 to 84 with a male to female ratio of 3:2 (**Table 1**). More than 90% patients required supplemental oxygen and 27.1% patients required ventilation.

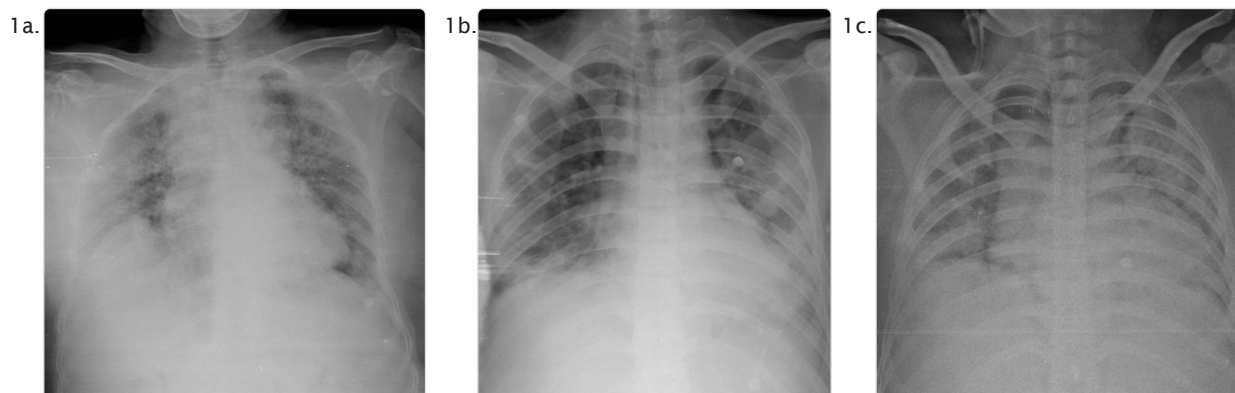
The majority of the patients (78.5%) had bilateral lungs affection. The upper, middle, and lower zone predominance was detected in 43 patients (71%). The most common CXRs features were a combination of ground glass opacity and consolidation in 38 patients (54.2%), and ground glass opacity, consolidation, and reticular interstitial thickening in 21 patients (30%) (**Table 1**) (**Fig. 1**).

At the first four days of hospitalization, there was no significant difference in Brixia score ( $p = 0.793$ ) (**Fig. 2a**) or RALE score (**Fig. 2b**) ( $p = 0.842$ ) between the expired and improved patients. On the other hand, the differences in both (Brixia and RALE) scores between expired and improved patients significantly increased ( $p < 0.05$ ) with each passing day. The majority of the patients who lived ( $n = 53$ ) showed signs of deterioration on days 5 - 9, but their scores gradually improved after that. The majority of patients had an increased severity score in the CXR for the first 5 - 9 days, but scores remained unchanged or declined in the days after they

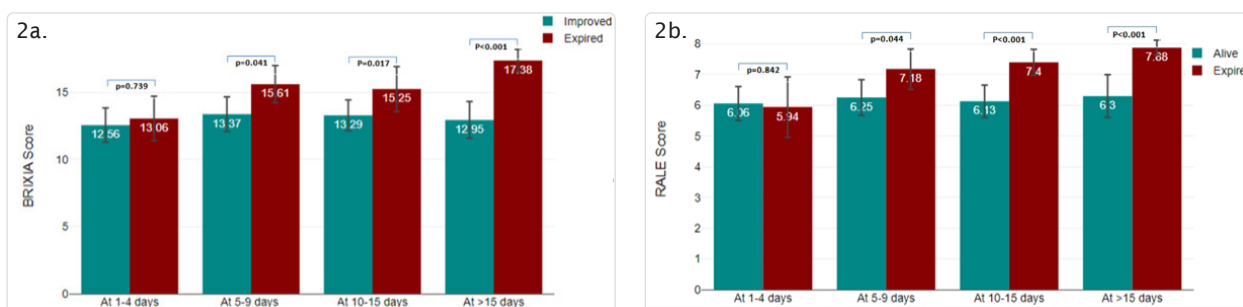
**Table 1: Demographic profile, clinical outcomes and radiological features in COVID-19 patients (n=70). Values are presented as number (%).**

Characteristics		Number (%)
Age in years (Mean $\pm$ SD = 48.27 $\pm$ 13.84)	< 20	1 (1.4)
	20 - 39	13 (18.5)
	40 - 59	39 (55.7)
	$\geq 60$	17 (24.2)
Oxygen require- ment (n = 51)	M/ F	42 (60)/ 28 (40)
	Not required	6 (8.5)
	< 5 L/min	8 (11.4)
	5 - 10 L/min	17 (24.2)
Ventilation requirement (n = 19)	10 - 15 L/min	20 (28.5)
	Non-Invasive Ventilation	8 (11.4)
	Invasive Ventilation	11 (15.7)
Outcome	Expired	17 (24.2)
	Improved & discharged	53 (75.7)
<b>Radiological features</b>		
Zonal predomi- nance in lungs	Upper zone	1
	Middle zone	1
	Lower zone	5
	Upper & middle zone	1
	Upper & lower zone	0
	Middle & lower zone	19
Lung predomi- nance	Upper, middle & lower zone	43
	Right lung predominance	5
	Left lung predominance	10
	Bilateral lungs predomi- nance	55
Location of lesion	Peripheral	4
	Central only	0
	Peripheral and central	51
	Diffuse	15
Patterns of lung abnormality on CXR	Interstitial	1
	Ground glass opacity	4
	Interstitial +Ground glass opacity	5
	Interstitial + ground glass opacity + consolidation	21
	Ground glass opacity + consolidation	38
	Consolidation only	1
	Associated pulmonary nodules	5
	Associated pleural effusion	2
Associated pneumomedi- astinum	6	

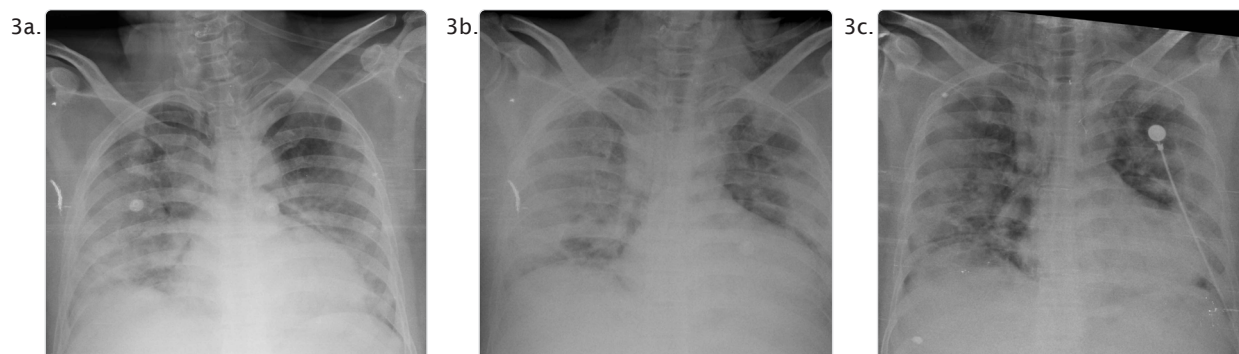
CXR: Chest X-ray



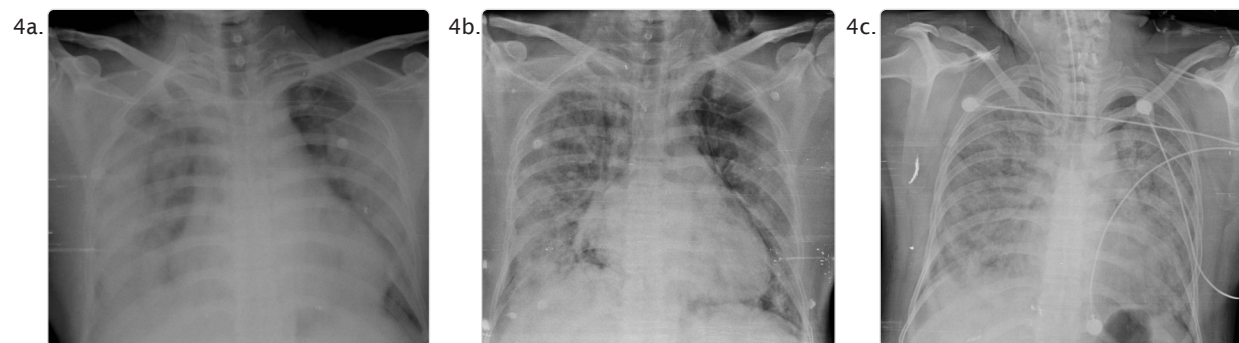
**Figure 1:** Chest X-ray in different patients showing: a. interstitial and ground glass opacity in B/ L lungs. b. Groundglass opacity in B/ L lungs c. B/ L lung consolidations.



**Figure 2:** a: Chest X-ray severity score at different stages- a: BRIXIA scores. b: RALE scores.



**Figure 3:** Serial X-ray in a 42 year male having oxygen saturation of 80% on the day of admission. a. Chest X-ray showing Severity score 8 (RALE), 17 (BRIXIA) at the time of admission to ICU. There is gradual reduction in the lung opacities, on day 12 (b.) and day 20 (c.). The patient was ultimately discharged from ICU.



**Figure 4:** Serial X-ray in a 40 years/ male who expired on 15 days of ICU admission. Chest X-ray shows B/ L air space diffuse consolidation opacities in both lungs with total severity score of RALE = 7 and Brixia = 15 at initial days (a) and progressed to RALE = 8 and BRIXIA = 18 (c).

**Table 2: Correlation between CXR severity score (RALE and BRIXIA) at different stages.**

Stage	Group	N	Pearson's Correlation Coefficient (r)	p-value
At 1 - 4 days	All patients	70	0.934	< 0.001
	Improved	53	0.925	< 0.001
	Expired	17	0.944	< 0.001
At 5 - 9 days	All patients	69	0.926	< 0.001
	Improved	52	0.931	< 0.001
	Expired	17	0.901	< 0.001
At 10 - 15 days	All patients	61	0.940	< 0.001
	Improved	46	0.949	< 0.001
	Expired	15	0.904	< 0.001
At > 15 days	All patients	28	0.895	< 0.001
	Improved	20	0.880	< 0.001
	Expired	8	0.756	0.030

survived. Patients who died had significantly higher severity scores in both lungs during or after 15 days in the ICU compared to those who survived (**Fig. 3, 4**). A significant strong positive correlation was observed between Brixia and RALE severity scores at different stages of diseases among expired as well as improved patients ( $r > 0.75$ ,  $p < 0.001$ ) (**Table 2**).

## DISCUSSION

CXR is less sensitive for detecting pulmonary involvement in early-stage disease, however, it is useful for monitoring the rapid progression of lung abnormalities in COVID-19, especially in critical patients admitted to ICU [8]. Thus, we aimed to use CXR findings and grading system to evaluate the COVID-19 disease course, and outcome in critically ill patients with respiratory distress.

According to the American College of Radiology (ACR) and the Fleischner Society, imaging is not recommended for asymptomatic or mildly symptomatic patients who tested positive by RT-PCR, and CT scans should be reserved for patients with a progressive disease course [10, 11]. Because the COVID-19 virus has a high infectious rate, infection control in radiology departments can be difficult in the CT scan suite. Therefore, the ACR has suggested that a portable chest X-ray be considered to reduce the risk [6, 10]. Previous studies have demonstrated that a chest CT scan is a more sensitive diagnostic technique than RT-PCR in asymptomatic individuals, with a sensitivity of 98 percent [12 - 14]. Patients with a positive RT-PCR may have a negative chest CT scan, and patients with

a negative RT-PCR may have a positive chest CT scan, according to several researchers [15 - 17].

Portable X-rays were used to evaluate the patients in COVID-19 ICU. They were either admitted from home isolation, referred from other nearby hospital with increasing severity requiring ICU care or developed breathing difficulty and decreased oxygen saturation from the isolation ward.

In our study, there were 42 males (60%) and 28 females (40%) with male patients showing a significantly higher mortality rate compared to the female patients. Similar finding is reported by Borghesi et al. who studied 783 Italian patients. The majority of the patients (67.9%) were men, and just 15.2% were under the age of 50. They stated that in adult patients with confirmed SARS-CoV-2 infection, underlying comorbidities (such as diabetes, hypertension, cardiovascular disease, and oncologic history) are risk factors for fatal outcomes. They also noted that older age groups, between 50 and 79 years, had more significant pulmonary affection [5].

In a previous study, the severity score of CXRs was found to be a predictive index of risk for hospital admission and intubation in patients with COVID-19 pneumonia [18]. In another study, the portable CXRs were found to be beneficial in the follow-up of critically ill COVID-19 patients [19]. The radiographic findings on CXR in COVID-19 pneumonia patients in our study were compatible with clinical findings, illness severity, and oxygen need. Furthermore, in our study, the presence of symptoms was strongly associated with abnormal chest X-ray findings, implying that CXR may be useful as a diagnostic and follow-up tool in patients with COVID-19 pneumonia. To provide useful

assistance for clinicians and improve disease risk stratification, a CXR grading system was developed, which provides a semi-quantitative tool for assessing lung abnormalities [6].

In this study, we assessed the CXR findings and severity scores of COVID-19 patients at various stages of the disease. CXR abnormalities were found in all of the patients with varying degrees of severity. The most common finding in our study was a combination of reticular interstitial thickening, ground glass opacity, and consolidation (30%). Similarly, in a study of 64 COVID-19 patients, consolidation was the most common finding (47%), followed by GGO (33%) [11]. Furthermore, peripheral predominance was identified in 41% of CXR abnormalities, with lower zone distribution (50%) and bilateral lung involvement in 55 patients (50%). Pleural effusion was infrequent, occurring in just 3% of patients [6,19]. Consolidation was the most common finding (46.9%), with bilateral lung affection (78.1%) and lower zone involvement in another investigation by Lomoro et al. on thirty-two patients with COVID-19 illness (52%). There was no pleural effusion [21].

According to Jacobi et al., CXR can easily detect reticular opacities that accompany regions of ground glass attenuation. They discovered that COVID-19 disease has a unique feature of air space consolidation opacities with peripheral and lower zone distribution [22]. Bilateral pneumonia was the most prevalent finding on chest radiographs, according to Chen et al. [23]. Ng et al., on the other hand, found that CXR is insensitive in the early stages of lung illness [22]. Pleural effusions, pneumothorax, and lung cavitation are uncommon in COVID-19-infected patients, according to most studies [20, 23].

In our study, the maximal severity score (7 - 8 RALE, 16 - 18 Brixia) for expired patients had a positive link with disease outcome. Those with a higher severity score, on the other hand, had a much greater survival rate. On 1 - 5 days after ICU admission, 36 patients had the highest total severity scores (RALE: 7 - 8, Brixia: 16 - 18), 28 of whom improved and recovered, and 8 of whom died. Seven patients who had lesser severity score (less than 7) on 1 - 5 days progressed to higher severity score by 11 - 20 days and expired with Pearson correlation coefficient 0.93 for all patients and p-value < 0.001. This was in agreement with the findings of Toussie et al., who found that the severity of lung involvement on the initial chest radiograph was linked

to a higher need for hospitalization and a higher risk of intubation, and proposed the use of initial CXR severity scores as a prognostic indicator of COVID-19 patients' outcome [18].

There were certain limitations to our study. First, the study duration was short; second, baseline CXRs were not available prior to the ICU admission; and third, there was no correlation between CXR severity score and patient comorbidities (such as hypertension, diabetes, cardiovascular disease, and oncologic history). Fourth, CXR serial follow-up tests were not done in a consistent pattern since the clinician was focused on the clinical condition. Fifth, the portable AP CXR was poor for severe cases in the intensive care unit, with only a few cases undergoing CT, so we couldn't assess CXR sensitivity. Finally, the sample size was low and the follow-up interval was short limiting the scope of analyzing potential prognostic imaging variables that could aid in the prediction of worse outcomes.

## CONCLUSION

**T**here is an increased risk of mortality with a higher severity score upon ICU admission. Despite the high severity score, the majority of patients had a favorable response to treatment and a positive result. This can aid radiologists and clinicians in identifying high-risk patients, enabling for early treatment of SARS-CoV-2 infection with already accessible medications.

## References

- Oran DP, Topol EJ. The proportion of SARS-CoV-2 infections that are asymptomatic: A systematic review. *Annals of Internal Medicine*. 2021;174(5):M20-6976. DOI: 10.7326/M20-3012
- "Interim clinical guidance for management of patients with confirmed coronavirus disease (COVID-19)". U.S. Centers for Disease Control and Prevention (CDC). 6 April 2020. Archived from the original on 2 March 2020. Retrieved 19 April 2020.
- Cleverley J, Piper J, Jones MM. The role of chest radiography in confirming covid-19 pneumonia. *BMJ*. 2020;370. DOI: 10.1136/bmj.m2426
- Yang R, Li X, Liu H, Zhen Y, Zhang X, Xiong Q, et al. Chest CT severity score: an imaging tool for assessing severe COVID-19. *Radiol Cardiothorac Imaging*. 2020;30;2(2):e200047. DOI: 10.1148/ryct.2020200047.
- Borghesi A, Zigliani A, Masciullo R, Golemi S, Maculotti P, Farina D et al. Radiographic severity index in COVID-19 pneumonia: relationship to age and sex in 783 Italian patients. *Radiol Medica*. 2020;125(5):461-4. DOI:10.1007/s11547-020-01202-1
- Wong HY, Lam HY, Fong AH, Leung ST, Chin TW, Lo CS, et al. Frequency and distribution of chest radiographic findings in patients positive for COVID-19. *Radiology*. 2020;296(2):E72-8. DOI:10.1148/radiol.2020201160
- Barnard C. Age, comorbidities linked to poor COVID-19 outcomes in patients with rheumatic diseases [Internet]. *Medicine Matters Rheumatology*; 2020 June 25. [cited: 2021 May 13]. Available from: <https://rheumatology.medicinematters.com/covid-19/infection/age-comorbidities-poor-outcomes-patients-rheumatic-diseases/18117812>.
- Borghesi A, Maroldi R. COVID-19 outbreak in Italy: experimental chest X-ray scoring system for quantifying and monitoring disease progression. *Radiol Medica*. 2020;125(5):509-13. DOI:10.1007/s11547-020-01200-3
- Warren MA, Zhao Z, Koyama T, Bastarache JA, Shaver CM, Semler MW, et al. Severity scoring of lung edema on the chest radiograph is associated with clinical outcomes in ARDS. *Thorax*. 2018;73(9):840-6. DOI: 10.1136/thoraxjnl-2017-211280
- ACR recommendations for the use of chest radiography and computed tomography (CT) for suspected COVID-19 infection [Internet]. American College of Radiology. [cited: 2020 April 27]. Available from: [www.acr.org/advocacy-and-Economics/ACR-Position-Statements/Recommendations-for-Chest-Radiography-and-CT-for-Suspected-COVID-19-infection](http://www.acr.org/advocacy-and-Economics/ACR-Position-Statements/Recommendations-for-Chest-Radiography-and-CT-for-Suspected-COVID-19-infection).
- Rubin GD, Ryerson CJ, Haramati LB, Sverjellati N, Kanne JP, Raoof S, et al. The role of chest imaging in patient management during the COVID-19 pandemic: A multinational consensus statement from the Fleischner society. *Radiology*. 2020;296(1):172-80. DOI:10.1148/radiol.2020201365
- Salehi S, Abedi A, Balakrishnan S, Gholamrezanezhad A. Coronavirus disease 2019 (COVID-19): a systematic review of imaging findings in 919 patients. *Ajr Am J Roentgenol*. 2020;215(1):87-93. DOI:10.2214/AJR.20.23034
- Ai T, Yang Z, Yang Z, Hou H, Zhan C, Chen C, et al. Correlation of chest CT and RT-PCR testing in coronavirus disease 2019 (COVID-19) in China: a report of 1014 cases. *Radiology*. 2020;296(2):E32-40. DOI: 10.1148/radiol.2020200642
- Fang Y, Zhang H, Xie J, Lin M, Ying L, Pang P, et al. Sensitivity of Chest CT for COVID-19: Comparison to RT-PCR. *Radiology*. 2020;296(2):E115-7. DOI: 10.1148/radiol.2020200432
- Chung M, Bernheim A, Mei X, Zhang N, Huang M, Zeng X, et al. CT Imaging features of 2019 novel coronavirus (2019-nCoV). *Radiology*. 2020;295(1):202-7. DOI: 10.1148/radiol.2020200230
- Arslan S, Delice O, Kahraman M, Yilmaz SI, Aslan MH. Correlation of chest CT and RT-PCR testing in coronavirus disease 2019 (COVID-19) in Turkey. *Annals of Clinical and Analytical Medicine*. 2021;12(5):483-7. ID: covidwho-1580159
- Bernheim A, Mei X, Huang M, Yang Y, Fayad ZA, Zhang N, et al. Chest CT findings in coronavirus Disease-19 (COVID-19): relationship to duration of infection. *Radiology*. 2020;295:200463. DOI: 10.1148/radiol.2020200463.
- Toussie D, Voutsinas N, Finkelstein M, Cedillo MA, Manna S, Maron SZ, et al. Clinical and chest radiography features determine patient outcomes in young and middle age adults with COVID-19. *Radiology*. 2020;297(1):E197-E206. DOI: 10.1148/radiol.2020201754.
- Wu G, Li X. Mobile X-rays are highly valuable for critically ill COVID patients. *Eur Radiol*. 2020;30(9):5217-9. DOI:10.1007/s00330-020-06918-2
- Ng MY, Lee EY, Yang J, Yang F, Li X, Wang H, et al. Imaging profile of the COVID-19 infection: radiologic findings and literature review. *Radiol Cardiothorac Imaging*. 2020;2(1):e200034. DOI:10.1148/ryct.2020200034
- Lomoro P, Verde F, Zerboni F, Simonetti I, Borghi C, Fachinetti C, et al. COVID-19 pneumonia manifestations at the admission on chest ultrasound, radiographs, and CT: single-center study and comprehensive radiologic literature review. *Eur J Radiol Open*. 2020;7:100231. DOI:10.1016/j.ejro.2020.100231
- Jacobi A, Chung M, Bernheim A, Eber C. Portable chest X-ray in coronavirus disease-19 (COVID-19): A pictorial review. *Clin Imaging*. 2020; 64:35-42. Doi: 10.1016/j.clinimag.2020.04.001.
- Chen N, Zhou M, Dong X, Qu J, Gong F, Yang H, et al. Epidemiological and clinical characteristics of 99 cases of 2019 novel coronavirus pneumonia in Wuhan, China: a descriptive study. *Lancet*. 2020;395:507-13. DOI: 10.1016/S0140-6736(20)30211-7