

Case Report

Extraordinarily Large Malignant Extra Gastro Intestinal Stromal Tumor Presenting as an Abdominal Mass

P Paudyal¹, TN Subba¹, A Pradhan¹, S Dhakal¹, S Karki¹, P Paudyal²

¹Department of Pathology, ²Department of General Surgery

BP Koirala Institute of Health Sciences, Dharan

Abstract

Background: Gastrointestinal stromal tumors (GIST) are rare of all gastrointestinal neoplasms with histology and immunohistochemistry similar to gastrointestinal stromal tumors. They occur outside the gastrointestinal tract rarely and are, hence, called the extra gastrointestinal stromal tumors (EGIST). Herein, we report a rare case of malignant extraintestinal gastrointestinal tumor.

Case report: A 39 yr old female presented to the surgical OPD with a lump in the abdomen since 4 months. We received a lobulated tumor which measured 40x25x20 cm³ and showed capsule. Cut surface was predominantly solid, grey white with areas of hemorrhage and necrosis along with cystic areas. Histopathology and immunohistochemistry revealed it to be a malignant EGIST of mesentery because of no continuity of the tumor with the small intestine microscopically.

Conclusion: EGIST is a rare nonepithelial tumor of mesentery. Omentum histopathological examination is a standard technique to diagnose the tumor and to differentiate it immunohistochemically from other tumors having similar morphology. Correct diagnosis plays valuable role in the treatment.

Keywords: Abdominal mass, extra intestinal, malignant, GIST, stromal tumor

Introduction

Gastrointestinal stromal tumors (GISTs) are rare (0.1- 0.3%) of all gastrointestinal nonepithelial neoplasms.¹ Diagnosis of GISTs relies on histological and immunohistochemical criteria. Neoplasms with histology and immunohistochemistry similar to Gastrointestinal stromal tumors (GISTs) occur outside the gastrointestinal tract (omentum, mesentery and retroperitoneum) rarely (5%) and are, so, called the Extra-gastrointestinal stromal tumors (EGISTs).² Differential diagnosis of GIST include: tumors with smooth muscle differentiation: leiomyomas and leiomyosarcomas, gastric schwannomas, intra-abdominal fibromatosis, inflammatory gastric

polyp and inflammatory myofibroblastic pseudo-tumor.³

Here, we report a case of EGIST of mesentery in a female patient.

Case Report

A 39 years old female presented to the surgical outpatient department with a lump in the abdomen since 4 months. The per-operative findings showed a lobulated tumor arising from the ante mesenteric border of the small intestine with separate feeding vessels. Operative diagnosis of ‘? GIST’ was made. We received a tumor measuring 40x25x20 cm³ and was capsulated and lobulated. Cut surface was predominantly solid, grey white with areas of hemorrhage and necrosis along with cystic areas (Fig. 1). Histological examination revealed tumor cells arranged in short, long fascicles and herring bone pattern with elongated individual tumor cells having oval to elongated nuclei with

Address for correspondence

Dr. Punam Paudyal

Department of Pathology

BP Koirala Institute of Health Sciences, Dharan

Email: punam.paudyal@bpkihs.edu

blunt edges and eosinophilic indistinct cytoplasm (Fig. 2). Mitotic figures including atypical ones (9/ HPF) were noted along with necrosis and hemorrhage. The tumor cells showed positivity for CD- 117 (Fig. 3). However, no continuity was seen with small intestine microscopically.

In this case, histologic evaluation indicated spindle cell type, high density of tumor cells, brisk mitoses (9/ HPF) and huge size (40x25x20cm³) strongly suggested malignant tumor. Based on the morphological findings supported by immunohistochemical profile, malignant Extra Gastrointestinal Stromal Tumor of mesentery was diagnosed.




Figure 1: Grossly tumor measured 40x25x20 cm³ with lobulations. Cut surface was predominantly solid, grey white with areas of hemorrhage and necrosis.

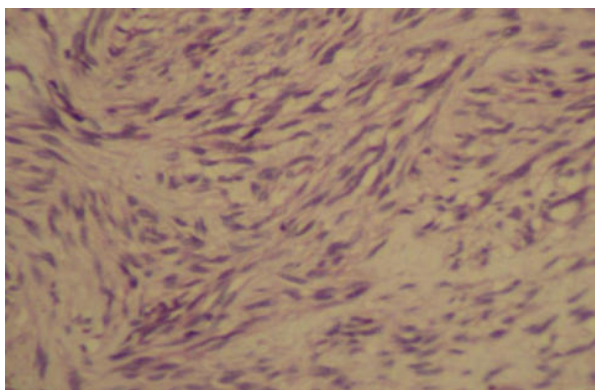


Figure 2: Elongated tumor cells arranged in fascicles having oval to elongated nuclei with blunt edges and eosinophilic indistinct cytoplasm. (H&E 10X)

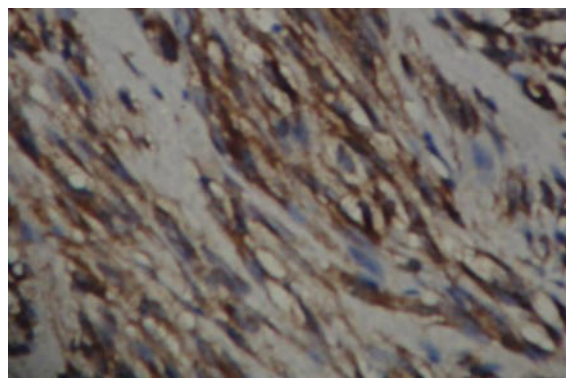


Figure 3: Tumor cells show strong positivity for CD 117 (IHC, 100X)

Discussion

Gastro-Intestinal Stromal Tumor (GISTs) are defined as spindle cell, epithelioid or occasionally pleomorphic mesenchymal tumors of the gastrointestinal tract which express the KIT protein detected at immunohistochemistry.⁴ GIST are believed to originate from interstitial cells of cajal or their stem cell-like precursors. They are Kit and Kit-ligand (stem cell factor) positive and dependent cells.⁵ Sites for extraintestinal GIST (EGIST) include: mesentery, omentum, peritoneum, gallbladder and liver.^{4, 5}

Histologically EGISTs have a similar appearance to GISTs, and the EGIST is a distinctive entity, different from leiomyosarcomas.⁶ High cell density, karyomorphism, brisk mitoses, encroachment of blood vessels, size suggest malignant features of the tumor.⁶ EGIST express CD117 (c-kit receptor in 100%), CD34 (50%), neuron-specific enolase (44%), smooth muscle actin (26%), desmin (4%) and S-100 protein (4%).⁷

Of the omental EGISTs reported by various studies, the mean diameter of the tumor was 15.35 cm.^{6, 7} In our case also, the tumor size was huge. Four various studies done in 99 omental and mesenteric GIST, only 8 patients were under

40 years of age. Out of 8 patients, 6 were females. None were younger than 30 years old; and only 5 were younger than 35 years old.^{3,4,6,8} EGISTs are very rare in pediatric age group.³

Similarly, in the study conducted over a period of 16 years in nine total cases, mean age of the patient was 59.6 years. Majority of the EGIST were located in the intra abdominal cavity, only one each in the retroperitoneum and in the jejunal mesentery with the mean diameter of 15.6 cm.⁹ Tumor recurrences following surgical resection had been found in three patients and metastasis in two patients. This particular study reports the overall survival for female as 56.44 months and for male 32.57 months with the 5 years overall survival rate of 38%.⁹

The overall survival rate for EGIST is comparatively lower than that of GIST with 1, 3 and 5 years survival rate of 91.7%, 61.1% and 48.9% respectively.¹⁰ However as for GIST, the survival is better with 1, 3 and 5 years survival rate of 98.0 %, 88.1% and 82.4% respectively.¹⁰ The significant differences in survival rate could be due to huge tumor size and gastrointestinal bleeding in case of EGIST.^{9,11}

Conclusion

Even though extra-gastrointestinal stromal tumors are a rare entity, they should be considered in the differential diagnosis of solid masses of abdomen which can be easily diagnosed by histopathology. Correct diagnosis is important for proper treatment since it specifically responds to the c-kit selective tyrosine kinase inhibitor, Imatinib mesylate.

References

1. DeMatteo RP, Lewis JJ, Leung D. Two hundred gastrointestinal stromal tumors:

- recurrence patterns and prognostic factors for survival. *Ann Surg* 2000; 231: 51-8.
2. Fulop E, et al. Gastrointestinal stromal tumors: review on morphology, diagnosis and management. *Romanian Journal of Morphology and Embryology*. 2009; 50(3): 319-26.
3. Reith JD, Goldblum JR, Lyles RH, Weiss SW. Out Extra-gastrointestinal (soft tissue) stromal tumors: an analysis of 48 cases with emphasis on histologic predictors of outcome. *Mod Pathol*. 2000; 13(5): 577-85.
4. Miettinen M, Monihan J M, Sarlomo-Rikala M, Kovatich AJ, Carr NJ, Emory TS, Sobin LH. Gastrointestinal stromal tumors/smooth muscle tumors (GISTs) primary in the omentum and mesentery: clinicopathologic and immunohistochemical study of 26 cases. *Am J Surg Pathol*. 1999; 23(9): 1109-18.
5. Mendoza-Marin M, Hoang M P, Albores-Saavedra J. Malignant stromal tumor of the gallbladder with interstitial cells of Cajal phenotype. *Arch Pathol Lab Med*. 2002; 126: 481-3.
6. Sakurai S, Hishima T, Takazawa Y, Sano T, Nakajima T, Saito K, Morinaga S, Fukayama M. Gastrointestinal stromal tumors and KIT-positive mesenchymal cells in the omentum. *Pathol Int*. 2001; 51: 524-31.
7. Abuduwayite et al. Malignant Retroperitoneal Extra-Gastrointestinal Stromal Tumor: A Case Report. *British Journal of Medicine & Medical Research*. 2012; 2(2): 142-149.
8. Yamamoto H, Oda Y, Kawaguchi K, Nakamura N, Takahira T, Tamiya S, Saito T, Oshiro Y, Ohta M, Yao T, Tsuneyoshi M. c-kit and PDGFRA mutations in

- extragastrointestinal stromal tumor (gastrointestinal stromal tumor of the soft tissue) Am J Surg Pathol. 2004; 28: 479-88.
9. Hatipoglu E. Extragastrointestinal stromal tumor (EGIST): a 16-year experience of 13 cases diagnosed at a single center. Med Sci Monit. 2018; 24: 3301-6.
10. Zheng S, Wang Z, Zhang T, Hu S Cheng M, Zhang M, et al. Prognostic analysis of primary extra-gastrointestinal stromal tumors. Int J Clin Exp Med. 2016; 9: 18068-73.
11. Feng F, Feng B, Liu S, Liu Z, Xu G, Guo M, et al. Clinicopathological features and prognosis of mesenteric gastrointestinal stromal tumor: evaluation of a pooled case series. Oncotarget. 2017; 8: 46514-22.