

## Case Report

# Lymphangioma circumscriptum Associated with Port-Wine Stain

N Shah, A Rijal, S Agrawal

Department of Dermatology & Venereology

BP Koirala Institute of Health Sciences, Dharan, Nepal

### Abstract

Lymphangioma circumscriptum (LC) is a rare benign disorder involving the deep dermal and subcutaneous lymphatic channels. We present a case of a 32-year old 26 weeks pregnant female with multiple fluid filled vesicles over the vulvae of one year duration with itching. The lesions had increased in size after the onset of pregnancy. The patient also had a large port-wine stain (PWS) over the right buttock extending up to the perineum. The biopsy report was consistent with LC.

**Keywords:** Lymphangioma circumscriptum, vulva

### Introduction

Vascular malformations are rare disorders of vascular development present at birth which occur in 0.3-0.5% of the population. Port-wine stain without any association is the most prevalent vascular malformation. Geographic stains are more often associated with lymphatic malformations.<sup>1</sup> Lymphangioma circumscriptum is a lymphatic malformation which presents with superficial vesicles or wart-like lesions which are connected to deeper subcutaneous lymphatic cisterns. It may present as a congenital disorder or may be acquired, following damage to normal lymphatic channels.

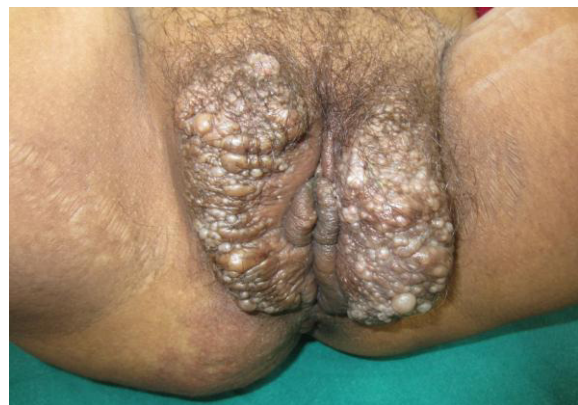Lymphangioma circumscriptum of the vulva is rare. Vlastos et al. have reported only 11 congenital cases, and 20 acquired cases in a review of English medical literature in 2003.<sup>2</sup>

### Case

A 32-year-old pregnant female presented to the Dermatology clinic with swelling over the vulvae with overlying fluid filled lesions with itching for one year. The patient was 26 weeks

pregnant at presentation with her third pregnancy, previous pregnancies had been by LSCS, uneventful otherwise (G3P2L2).

Patient had swelling over the vulva studded with blisters associated with itching since one year. The swelling had been gradually increasing for one year; however, there had been faster increase since the onset of pregnancy. This patient also had a large irregularly shaped erythematous macule with well-defined margins, extending from the right perineal region to the right buttock and lower back crossing the midline, since birth. She denied any history of trauma, surgery, infections, cancer or radiation therapy in the area. On examination, there was hypertrophy of the vulvae with warty sessile growths and vesicles over the involved area (Fig. 1).



**Figure 1:** Swelling over the genitalia studded with multiple vesicles and bullae

---

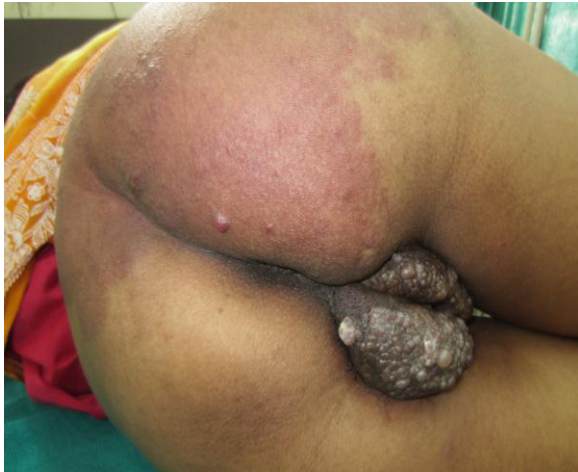### Address for correspondence

Dr. Nidhi Shah

Department of Dermatology and VD

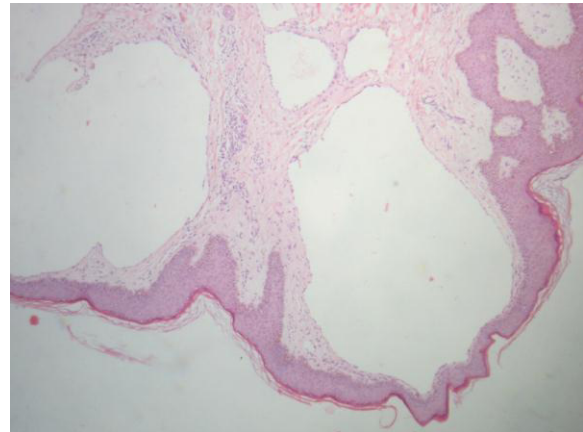
Email: nidhishah.md@gmail.com

In addition, there was a large irregularly shaped erythematous macule with well-defined margins, extending from the right perineal region to the right buttock and lower back crossing the midline (Fig. 2).



**Figure 2:** Large well to ill-defined erythematous macule on the right buttock extending up to the thigh.

There was mild hypertrophy of the right buttock and right thigh. The regional inguinal lymph nodes were not enlarged. The rest of the examination was unremarkable. A clinical diagnosis of lymphangioma circumscriptum with port-wine stain was made. A skin biopsy was advised. Histopathological features showed features of lymphangioma circumscriptum (multiple dilated spaces lined with endothelium) with foci of chronic inflammation. The epidermis showed irregular acanthosis and some pigment incontinence (Fig. 3).



**Figure 3:** Histopathology showing dilated spaces lined with endothelium, consistent with Lymphangioma circumscriptum (40X)

### Discussion

Lymphangioma circumscriptum of the vulva is rare. The presentation with hyperkeratotic papules and plaques may sometimes be confused with genital warts.<sup>3</sup> The congenital forms also may sometimes present later in life as the person matures. The patient in this case developed lesions at the age of 31 years, and had noticed a rapid increase in the size of the lesions as the pregnancy progressed. Faster progression during pregnancy has not been reported in the past. Possibility of dystocia should be kept in mind in such cases. She had a large port-wine stain as well on the thigh of the affected side. Co-existence of two kinds of vascular malformations is known to occur.

Magnetic resonance imaging (MRI) may be helpful in assessing the extent and depth of the lesion. We had deferred investigations owing to the pregnancy of the patient.

Treatment modalities of LC include surgical excision, intralesional sclerosant therapy, vaporization with CO<sub>2</sub> laser. However, with surgical excision, there is likelihood of recurrence, hence wide surgical excision is

usually advised. The patient in this report was advised to follow up after delivery for further management but she was lost to follow up.

**References:**

1. Redondo P, Aguado L, Martinez-Cuesta A. Diagnosis and management of extensive vascular malformations of the lower limb. Part I. Clinical diagnosis. *J Am Acad Dermatol.* 2011; 65: 893-906.
2. Vlastos AT, Malpica A, Follen M. Lymphangioma circumscriptum of the vulva: a review of the literature. *Obstet Gynecol.* 2003; 101: 946-54.
3. Sah SP, Yadav R, Rani S. Lymphangioma circumscriptum of the vulva mimicking genital wart: a case report and review of literature. *J Obstet Gynaecol Res.* 2001; 27: 293-6.
4. Redondo P, Aguado L, Martinez-Cuesta A. Diagnosis and management of extensive vascular malformations of the lower limb. Part II. Systemic repercussions, diagnosis, and treatment. *J Am Acad Dermatol.* 2011; 65: 909-23.