

Original Article

Endoscopic medial maxillectomy for sinonasal inverted papilloma

ST Chettri¹, S Karki², SP Shah¹, BP Sah¹, S Manandar¹, D Kandel¹, S Mishra¹,
RK Jaiswal¹, N Panthi¹

¹Department of Otorhinolaryngology and Head and Neck Surgery, ²Department of Pathology
BP Koirala Institute of Health Sciences, Nepal

Abstract

Background: Traditionally, medial maxillectomy was performed through lateral rhinotomy or mid facial degloving approach for inverted papilloma. Endoscopic medial maxillectomy, since reported first in 1992, has advanced tremendously and has been advocated by a number of authors for the fact that it prevents the morbidity of open approach with a similar recurrence rate. We present our experience of endoscopic medial maxillectomy for sinonasal inverted papilloma.

Aims and Objective: To highlight the treatment of inverted papilloma through transnasal endoscopic approach.

Methods: This study is a retrospective chart review of 18 patients out of 23 patients of which 5 were lost on follow-up with inverted papilloma who were treated during the last 2 years. Preoperative diagnosis was made on histopathological examination and Krouse staging in CT scans of paranasal sinus was used to estimate the extent of the disease. Then, surgical approach was decided. Post-operative follow up was done by performing direct nasal endoscopy. All patients were followed up for a minimum period of 1 year.

Results: Among the 18 patients who underwent endoscopic medial maxillectomy, sex (male : female) ratio were 1.25: 1, age ranged from 24 yrs to 69 yrs with average being 41.7 yrs. According to Krouse staging, 2 patients were in Stage I, 9 patients in Stage II and 7 patients in Stage III. The laterality of the lesion was more on the right. The commonest site of attachment was found to be the lateral wall of nose. The average duration of hospital stay was 4 days. The commonest complication was nasal crusting and the recurrence rate was 11.11%.

Conclusion: This work confirms the results described in recent literature and further supports transnasal endoscopic surgery to manage inverted papilloma.

Address for Correspondence

Dr. Shyam Thapa Chettri
Department of Otorhinolaryngology and Head and
Neck Surgery
BP Koirala Institute of Health Sciences, Dharan,
Email: dr_shyamtha@yahoo.com

Key Words: Inverted Papilloma,
Endoscopic medial maxillectomy.

Introduction

Sinonasal inverted papilloma is a benign tumour, accounting for 0.5% to 4.0% of all primary nasal tumours.¹ Surgical resection is the treatment of choice as this tumour has the propensity to erode bones, recur and associates with malignancy.^{1,2} Various surgical techniques have been employed for resection of this tumour, traditionally being open approach.³ Today, endoscopic techniques have the central role in the surgical management of inflammatory conditions of the sinonasal tract. However, the role of endoscopy in the surgical treatment of sinonasal neoplasms is evolving. The use of endoscopes has several distinct advantages by providing excellent visualization, no scars, less morbidity and preserving the function of nasal mucosa. We present our series of eighteen cases where we performed endoscopic medial maxillectomy for sinonasal inverted papilloma.

Material and Methods

A retrospective study was conducted in the Department of Otorhino-laryngology and Head & Neck Surgery from 25th September, 2013 to 24th September, 2015. The number of cases was collected after retrospective chart review, taking the inclusion and exclusion criteria into consideration. The inclusion criteria were: all diagnosed cases of inverted papilloma who underwent endoscopic medial

maxillectomy, not lost on follow-up. The exclusion criteria were: patients undergoing medial maxillectomy except for inverted papilloma, patients undergoing medial maxillectomy by any other approach except Endoscopic approach and patients contraindicated for surgery. Krouse staging for inverted papilloma was applied to stage the tumour. All surgeries were performed by consultants of the department with taking informed written consent. After surgery, patients were kept in ward and discharged after removal of nasal packs. Post-operatively, patients were followed up for direct nasal endoscopy on 7th post operative day, 21st post operative day, at 6 months and 1 year.

Results

A total of 18 patients were included in the study out of 23 as 5 patients could not meet the inclusion criteria over the period of 2 years; they were lost on follow-up. There were 8 males and 10 females with age ranging from 24 yrs. to 69 yrs. with average being 41.7 yrs. (Table 1). The most common presenting symptoms were nasal obstruction, rhinorrhea and anosmia (Table 2). According to Krouse, 2 patients were in stage I, 9 patients in stage II, and 7 patients in stage III (Table 3). The laterality of the lesion was more on the right (Figure 1). The commonest site of tumour involvement was found to be in

lateral wall of the nose (Table 4). All patients were managed endoscopically. In the post-operative period, nasal crusting was the most common complications seen on all follow up (Table 5). Average duration of hospital stay was 4 days (Table 7). On progressive follow up till 1 year, there was 11.11% recurrence.

Table 1: Age distribution

Age	Frequency (n= 18)	Percentage (%)
< 20 yrs	NIL	NIL
20- 29 yrs	5	27.70%
30- 39 yrs	3	16.60%
40- 49 yrs	7	38.80%
50- 59 yrs	1	5.50%
60- 69 yrs	2	11.11%

Table 2: Presenting Symptoms

Symptoms	Presenting (n= 18)	Percentage
Unilateral Nasal obstruction	14	77.77%
Rhinorrhea	12	66.66%
Epistaxis	4	22.22%
Sinusitis	3	16.66%
Facial pain	2	11.11%
Loss of sense of smell	4	22.22%
Frontal headache	6	33.33%

Table 3: Krouse staging of tumour:

Stage	Frequency (n= 18)	Percentage (%)
Stage I	2	11.11%
Stage II	9	50.00%
Stage III	7	38.89%

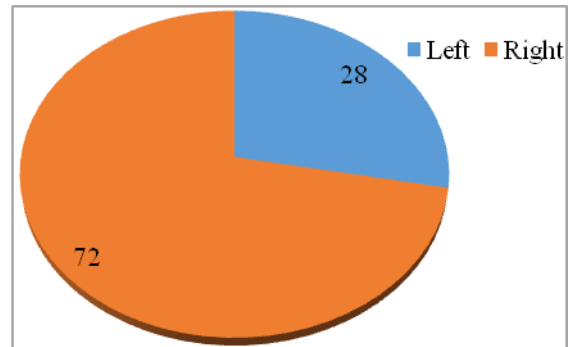


Figure 1: Laterality of lesion

Table 4: Site involved by tumour

Site involved	No. (%)
Lateral wall of the nose	18 (100)
Maxillary sinus	14 (77.77)
Ethmoid	13 (72.22)
Frontal recess	9 (27.77)
Sphenoid	6 (14.81)

Table 5: Post-operative complications:

Complication	Number of Cases (n= 18)	Percentage
Lid Odema	1	5.50%
Epiphora	2	11.11%
Nasal crusting	13	72.20%
Infection	4	22.22%
Synechae	3	16.60%

Discussion

Medial maxillectomy involves complete resection of the lateral nasal wall with the inferior boundary being the nasal floor; superiorly the cribriform plate and fovea ethmoidalis; anteriorly up to the anterior maxillary wall, including the nasolacrimal duct and posteriorly within 5 mm of the eustachian tube.⁴

The first reported endoscopic resection of inverted papilloma was in the year 1992 by Waitz and Wigand.⁵ Since then, it has advanced tremendously and we share our experiences with the endoscopic medial maxillectomy for inverted papilloma.

All the patients underwent endoscopic medial maxillectomy by consultants. In our study, female patients outnumbered male which was in contrast to the other studies.^{3,6} Perhaps, it may be because of small sample size of this study.

The average age of presentation was 41.7 years showing a preponderance of older age group, other literature studies showed a little higher age presentation between the range of 50 to 60 years.^{7,8}

The most common clinical symptom in the present study was unilateral nasal obstruction, nasal discharge and epistaxis which was in agreement with the study done by Lyngdoh NC et al.⁸

Krouse⁹ and Cannady¹⁰ are the commonly used staging systems for inverted papilloma and on the basis of Krouse's classification, we observed 9 cases in stage II followed by 7 in Stage III and 2 cases in stage I respectively, which was similar to the finding by Jurado-Ramos A et al.¹¹

Localization of the site of attachment can be predicted preoperatively by CT scan of

paranasal sinus which shows focal hyperostosis and therefore, helps in the surgical planning. Intra-operatively the attachment of all the inverted papilloma was found to be on the lateral wall of the nose as seen in other studies.^{12,13}

On post operative follow up; nasal crusting was commonly encountered, the reason being physiological crusting due to drying of nasal discharge secondary to roomy operated cavity.

As there was no external wound, average hospital stay was 4 days as compared to 7 days the patient would stay for open approach in our institution. Sautter et al in their study observed similar results.¹⁴

The recurrence rate was 12% for the endoscopic subgroup and 20% for the nonendoscopic subgroup in a meta-analysis study by Busquets et.al.² which was quite similar to the present study showing 11.11% recurrence.

Conclusion

Complete surgical excision is the ideal modality of management of inverted papilloma. Endoscopic medial maxillectomy is a good surgical option in the management of sinonasal lesions. This work confirms the results described in recent literature and further supports transnasal endoscopic surgery to manage inverted papilloma.

References

1. Vrabec DP. The inverted schneiderian papilloma: a clinical and pathologic study. *Laryngoscope* 1975; 85: 186-220.
2. Busquets JM, Hwang PH. Endoscopic Resection of Sinonasal Inverted Papilloma: A Meta-analysis. *Otolaryngol. Head Neck Surg* 2006; 134: 476-82.
3. Eloy P, Mardyla N, Bertrand B, Rombaux P. Endoscopic endonasal medial maxillectomy: case series. *Indian J Otolaryngol Head Neck Surg* 2010; 62: 252-7.
4. Tanna N, Edwards JD, Aghdam H, Sadeghi N. Maxillectomy as the initial oncologic approach to sinonasal neoplasms: the anatomic basis. *Arch Otolaryngol Head Neck Surg* 2007; 133: 1139-42.
5. Waitz G, Wigand ME. Results of endoscopic sinus surgery for the treatment of inverted papillomas. *Laryngoscope* 1992; 102: 917-22.
6. Ayubi SD, Alia N, Ahmed S, Hameed S. Surgical management of inverted papilloma and role of endoscopic sinus surgery. *JUMDC* 2013; 4: 63-70.
7. Wood JW, Casiano RR. Inverted papillomas and benign non neoplastic lesions of the nasal cavity. *Am J Rhinol Allergy* 2012; 26: 157-63.
8. Lyngdoh NC, Ibohal TH, Mark IC. A study on clinical profile and management of inverted papilloma. *Indian J Otolaryngol Head Neck Surg* 2006; 58: 41-5.
9. Krouse JH. Development of a staging system for inverted papilloma. *Laryngoscope* 2000; 110: 965-8.
10. Cannady SB, Batra PS, Sautter NB, Roh HJ, Citardi MJ. New staging system for sinonasal inverted papilloma in the endoscopic papilloma in the endoscopic era. *Laryngoscope* 2007; 117: 1283-7.
11. Jurado-Ramos A, Jodas JG, Romero FR, Linarest EA, Del Castillo FM, Gomariz EM, Ban~ OsE.C. Endoscopic medial maxillectomy as a procedure of choice to treat Inverted papillomas. *Acta Oto-Laryngologica* 2009; 129: 1018-25.
12. Wassef SN, Batra PS, Barnett S. Skull Base Inverted Papilloma: A Comprehensive Review *ISRN Surg* 2012: 1-34.
13. Bhandary S, Singh RK, Shrestha S, Sinha AK, Badhu BP, Karki P. Sinonasal inverted papilloma in eastern part of Nepal. *Kathmandu University Medical Journal* 2006; 4: 431-5.
14. Sautter NB, Cannady SB, Citardi MJ, Roh HJ, Batra PS. Comparison of open versus endoscopic resection of inverted papilloma. *Am J Rhinol* 2007; 320-3.