

Vaginal Fibroma Presenting as Paraurethral Mass Mimicking Cystocele: A case report

Sonu Bharati,¹ Ranjana Shrestha,¹ Ganesh Dangal,¹ Ashok Kunwar,² Aruna Karki,¹ Hema Kumari Pradhan,¹ Kabin Bhattachan,¹ Nishma Bajracharya,¹ Kenusha Devi Tiwari¹, Sunita Maharjan¹

Author Info:

¹Department of Obstetrics and Gynecology, Kathmandu Model Hospital, Kathmandu, Nepal

²Department of General Surgery and Urology, Kathmandu Model Hospital, Kathmandu, Nepal

Corresponding Author:

Dr. Sonu Bharati

FCPS Resident in Obstetrics and Gynecology; Kathmandu Model Hospital, Kathmandu, Nepal

Email/Contact:

Sonubharati49@gmail.com

+977-9842713296

ABSTRACT

Benign female paraurethral lesion encompasses a spectrum of entities that have significance in clinical urology. Fibromas are usually present in the uterus originating from the smooth muscles, however, vaginal fibroma is the extra uterine manifestation of leiomyoma. Here, we present a case of 45 years old perimenopausal female, Para 6, living issues 6 who presented at our out-patients department with the complaint of mass growing in the vagina for 5 years but has increased in size for last 2 years. It has been associated with urinary symptoms, bleeding from mass and dyspareunia. General physical examinations were normal but on local examination mass arising from anterior vaginal wall mimicking cystocele with normal appearing external urethral meatus. However, her basic investigations including cystoscopy were normal. The tumor was surgically removed via myomectomy and its histopathology showed benign fibroma.

Keywords: Cystocele; Isolated vaginal fibroma, Paraurethral, Myomectomy.

QR Code



 View PDF

Scan Me for Full Text

Article Info

Received: 26 July 2020; **Accepted:** 10 September 2020; **Published Online:** 11 September 2020


How to cite this article in Vancouver Style?

Bharati S, Ganesh Danagl, Shrestha R, Karki A, Pradhan HK, Bhattachan K, Kunwar A, Bajracharya N, Tiwari KD, Maharjan S. Vaginal Fibroma Presenting as a Paraurethral Mass Mimicking Cystocele: A case report. *Europasian J Med Sci.* 2020;2(2): 97-99. <https://doi.org/10.46405/ejms.v2i2.181>

Disclaimer:

Conflict of Interest: None Declared;

Source of Support: Nil

Copyright: © 2020 by author(s). This is an open access article distributed under the terms of the [Creative Commons Attribution International License 4.0](https://creativecommons.org/licenses/by/4.0/)  which permits unrestricted use, distribution, and reproduction in any medium, provided the original work is properly cited.

Publisher's Note:

The Europasian Journal of Medical Sciences (EJMS) (www.europasianjournals.org) is an official Journal of Nirvana Psychosocial Care Center & Resesearch Institute (www.nirvanapscc.com). The Journal as well as publisher remain neutral with regards to any jurisdictional claims in any published articles, its contents and the institutional affiliations of the authors.

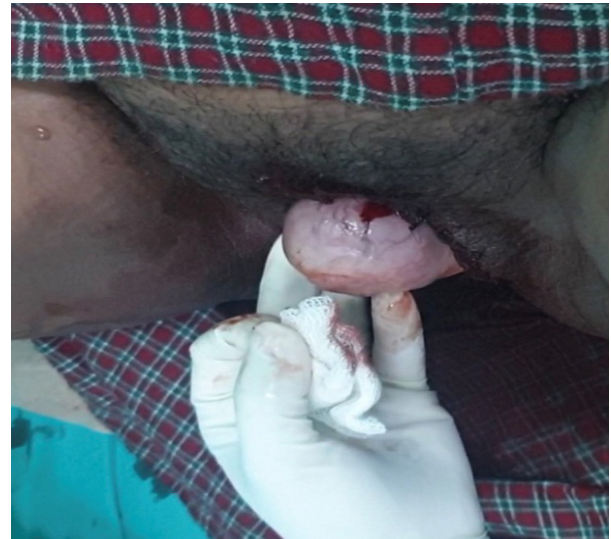INTRODUCTION

Vaginal paraurethral leiomyoma is a rare benign tumor of the vagina with a wide spectrum of symptoms and good prognosis. The recurrence and transformation into malignant condition are rare.¹Bladder and urethral leiomyoma are rare entities.²They may show various clinical symptoms depending on their site and size, which, at the level of urethra adjacent to vaginal wall, include recurrent urinary tract infections, voiding dysfunction, foreign body sensation, pain and dyspareunia.³Here, we present a case of an isolated, rare vaginal fibroma in a 45 years female who presented with a mass protruding per vagina for 5 years and underwent simple vaginal myomectomy without any complication.

CASE PRESENTATION

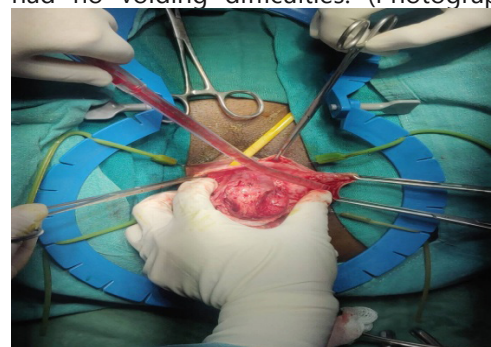
A 45 years multiparous perimenopausal woman who was a known case of hypertension under antihypertensive medication presented to our out-patients department with the complaint of mass protruding through the vagina since 5 years. Although initially, small in size, it has significantly increased in size since 1 year. The day before admission she landed up in our emergency department due to spontaneous profuse bleeding from the center of mass and it was managed conservatively. She was then admitted in gynecology ward and planned operation for the next day. She also complained of difficulty in walking, dyspareunia and burning sensation over the vagina. However, there was no history of fever, pain abdomen, increased frequency of micturition and acute retention of urine. On physical examination, she was average in built and her general condition was good. Systemic examination findings were unremarkable. On local examination, vulva and surrounding tissue were healthy. However, a mass was protruding from the anterior wall of vagina measuring 5X5cm, firm in consistency with smooth surface, non-tender with no signs of inflammation. Blood was oozing from the center of mass shown in figure 1. External urethral opening was normal. On per vaginal examination, uterus was enlarged, anteverted, with normal and non-tender bilateral adnexae. During her OPD visit six months back, operation had been planned but it was cancelled due to uncontrolled hypertension and only cystoscopy was performed which showed normal bladder anatomy with slightly deviated urethra. After that she had been discharged with the advice to come for operation after control of hypertension.

The patient was informed about her condition and the benefits and potential risks of surgery. After obtaining written informed consent for the procedure, she then underwent surgical excision of mass under spinal anesthesia. (Photograph 1)

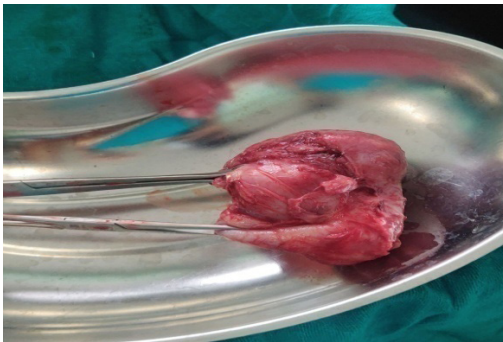


Photograph 1: Mass mimicking cystocele

Initially, hydro-dissection with adrenaline was done. Urologist consultation was done during the procedure. Midline incision was given over the mass and mucosal flap was separated by blunt dissection and the mass was removed intact. Intraoperative findings include solid cystic mass of size 6X6cm arising from anterior vaginal wall without involving the posterior surface of urethra. Cut section showed whorl appearance in solid part and hemorrhages in cystic part. Haemostasis was maintained throughout the procedure. The histopathological report confirmed the diagnosis of vaginal fibroma. Her post-operative period was uneventful and Foley's catheter was kept for three days. She was discharged on her third post-operative period after Foley's removal and she had no voiding difficulties. (Photograph 1 & 2)



Photograph 2: Blunt Dissection of vaginal wall



Photograph 3: Fibroma with solid and cystic components

During her one week follow-up, she was comfortable with no any fresh complains. She was satisfied with treatment for which she had visited multiple hospitals in the past since one year.

DISCUSSION

Leiomyomas are a benign tumor of smooth-muscle cells that can arise from the genitourinary or gastrointestinal systems. Leiomyoma arising from the urethra or paraurethral areas are uncommon, and there are few reported cases.⁴In women of birth age, they are the most frequently seen uterine masses. But, there have also been cases in which they have occurred in uncommon sites and displayed unusual growth patterns.²The sites where extra uterine leiomyoma most frequently develop are vulva, ovaries, urethra, and bladder in the genitourinary tract or where less frequently develop is in the gastrointestinal system, but can occur in almost any tissue that contains smooth muscle and so was in our case. They mainly affect women between the ages of 30-50 years.⁵ And among the benign urethral masses are polyps, papillomas, hemangiomas, fibroma, leiomyomas, fibromyomas and adenomas.²Whereas, the anterior wall of the vagina is the site where paraurethral leiomyomas develop, the anterior wall of the proximal urethra is where urethral leiomyomas most frequently do.⁶Patients with urethral leiomyomas are usually asymptomatic, but sometimes an enlarged mass on the anterior vaginal wall obstructs the urethral meatus and causes obstructive symptoms like dysuria, weak urine flow, mass, dyspareunia, post-voiding drip, frequent bowel movements, and irritative lower urinary system symptoms. It can also present with recurrent urinary tract infections.² However, in our case as the mass was paraurethral dysuria and dyspareunia was the prominent symptoms. Malignant degeneration and metastasis

have not yet been reported.⁷ A mass originating from the anterior wall of the vagina may cause dysuria by occluding the urethral meatus. In our case, the leiomyoma did not invade the urethra, but has caused intense dysuria. These complaints disappeared after surgical treatment. As the mass was closed to lower urinary tract system, dangers of damage to urethra and bladder should be always kept in mind.

CONCLUSION

There are many case reports of ovarian fibroma and uterine fibroma but fibroma of the paraurethral mass is rare as it is the less common site. After proper evaluation and ruling out the involvement of lower urinary tract, careful surgical removal via vaginal myomectomy can be performed safely.

REFERENCES

1. Braga A, Soave I, Caccia G, Regusci L, Ruggeri G, Pitaku I, Bassi V, Papadia A, Serati M. What is this vaginal bulge? An atypical case of vaginal paraurethral leiomyoma. A case report and literature systematic review. *Journal of Gynecology Obstetrics and Human Reproduction*. 2020;101822. <https://doi.org/10.1016/j.jogoh.2020.10182>
2. . Murat Alan MD, Mehmet Gökçü MD, Saime Ünlüoğlu MD, Muzaffer Sancı MD. Urethral Leiomyoma: A Case Report. *Bulletin of Urooncology*. 2018;17:153-5. <https://doi.org/10.4274/uob.1089>
3. . Fridman D, Abeshouse M, Sankin A. Paraurethral leiomyoma as an incidental finding in patient with fibroid uterus. *Case reports in obstetrics and gynecology*. 2018; 7042960. <https://doi.org/10.1155/2018/7042960>
4. . Reda Badr M, Higazy AM, Abuelbaga MM, Mostafa DE. Paraurethral Leiomyoma During Pregnancy: A Case Report and Review of the Literature. *Journal of Gynecologic Surgery*. 2020; 36(3). <https://doi.org/10.1089/gyn.2019.0082>
5. Leung YL, Lee F, Tam PC. Leiomyoma of female urethra causing acute urinary retention and acute renal failure. *The Journal of urology*. 1997;158(5):1911-2. [https://doi.org/10.1016/S0022-5347\(01\)64171-5](https://doi.org/10.1016/S0022-5347(01)64171-5)
6. Özel B, Ballard C. Urethral and paraurethral leiomyomas in the female patient. *International Urogynecology Journal*. 2006;17(1):93-5. <https://doi.org/10.1007/s00192-005-1316-3>
7. Vilar G, Martin JP, Aguado M. Leiomyoma of the female urethra: a case report and review of the literature. *Actas Urol ESP*. 2010;34:396. <https://www.thefreelibrary.com/>