

Association between Sella Turcica Bridging and Hypodontia - a Radiographic Study

*Sanjay Prasad Gupta¹, Shristi Rauniyar²

Author Info:

¹Orthodontics and Dentofacial Orthopedics unit, Department of Dentistry, Tribhuvan University Dental Teaching Hospital, Institute of Medicine, Maharjgung, Kathmandu, Nepal

²Dental Villa- Orthodontic center and Specialty dental clinic, Kathmandu, Nepal

*Corresponding Author:

Dr. Sanjay Prasad Gupta
Email:
sanjayagupta2000@gmail.com
drshristi123@gmail.com

ABSTRACT

Introduction: Introduction: The bridging of the sella turcica and dental anomalies have common embryonic origins and underlying genetic basis. Many studies have linked sella turcica bridging to developmental syndromes affecting the craniofacial region, and local dental anomalies such as tooth transposition and palatal canine impaction. The purpose of this study was to determine the association between the bridging of the sella turcica and hypodontia.

Methods: In this cross-sectional analytical study, the clinical records along with lateral cephalograms and orthopantomograms of 40 hypodontic patients as study sample (12 males and 28 females; mean age 13.9±2.5 years) and of 120 on hypodontic patients as control groups (58 males and 62 females; mean age 14.1±1.8 years) matched for age and gender to the study sample who came for orthodontic treatment from 2016-2018, were collected from archives of an orthodontic unit of Tribhuvan University Teaching Hospital and one private orthodontic clinic. Panoramic radiographs were evaluated for hypodontia. To quantify the extent of a sella turcica bridge on lateral cephalogram, the contour of the pituitary fossa from the tip of the dorsum sellae to the tuberculum sella was traced and extent of bridging was categorized by standardizing scoring scale using the comparative measurement of sella length and diameter.

Results: The presence of complete bridging (17.5%) and partial bridging (55%) in patients with hypodontia was more than complete bridging (5%) and partial bridging (37.5%) in patients without hypodontia (controls). The association between the degree of bridging and hypodontia was statistically significant according to chi-square statistics ($p=0.001$). There were no statistical differences between the degree of calcification and gender ($p=0.616$).

Conclusion: Sella turcica bridging is significantly associated with hypodontia. There is no dependence between the degree of calcification and gender. As the sella turcica bridge appears early in life, it should alert clinicians as a useful diagnostic predictor to the possible development of tooth anomalies later in life.

Keywords: Hypodontia, Orthodontic patients, Radiographic study, Sella turcica bridging

Quick Response (QR) Code



 View PDF

Scan Me for Full Text

Article Info

Received: 8 December 2019; **Accepted:** 23 January 2020; **Published Online:** 24 January 2020

How to cite this article in Vancouver Style?

Gupta SP, Rauniyar S. Association between Sella Turcica Bridging and Hypodontia - a Radiographic Study. *Europasian J Med Sci* 2020;2(1):11-16. <https://doi.org/10.46405/ejms.v2i1.20>

Disclaimer

Conflict of Interest: None Declared;

Source of Support: Nil

Copyright: © 2020 by author(s). This is an open access article distributed under the terms of the Creative Commons Attribution International License 4.0 which permits unrestricted use, distribution, and reproduction in any medium, provided the original work is properly cited.

Publisher's Note

The Europasian Journal of Medical Sciences (EJMS) remains neutral with regard to jurisdictional claims in published articles and institutional affiliations.

INTRODUCTION

The sella turcica is the intracranial bony depression located centrally within the sphenoid bone in which the pituitary gland is located.¹ As orthodontists deal frequently with sella turcica on the lateral radiographs, they should be familiar with the normal sellar anatomy and able to recognize any kind of morphologic deviation that might reflect pathological situations.² Sella turcica bridging (STB) is the common developmental anomaly of the sella turcica arises due to excessive ossification of dura mater between anterior and posterior clinoidal processes.³⁻⁵

The frequency of sella bridging ranges from 1.1% to 13% in healthy individuals but its percentage increases in patients having severe craniofacial deviations.^{2,6} Dental agenesis is considered as an important clinical and public health problem.⁷ Patients with missing permanent teeth may suffer from inarticulate pronunciation, a reduced chewing ability, and an unfavorable aesthetic appearance.⁸ This generally affects their self-esteem, communication behavior, and professional performance.⁹

Area of sella turcica is a critical point for the migration of neural crest cells to the frontonasal and maxillary area during embryonic development. So, the neural crest cells are involved in the development of sella turcica as well as the teeth.^{3,10} It was supposed that anatomic deviations of sella turcica could be associated with dental alterations. So, the association between STB and dental anomalies has been an area of interest for many researchers.¹¹⁻¹³

Certain genomic mutations in the homeobox gene expression, contained within neural crest cells, can lead to faulty signaling pathways that affect the development of teeth, midface, and sella-turcica.^{13,14} About half of the patients with cleft lip and palate¹⁵ and almost half of the children with malocclusion have sella turcica abnormalities.¹⁶ All these findings confirm a genetic basis for sella turcica bridging. Several studies have linked sella turcica bridging and other hereditary developmental syndromes that affect the craniofacial region, and also many local dental anomalies such as tooth transposition, palatal canine impaction and missing mandibular second premolars.^{17,18} However, little research is available on the association between hypodontia and sella turcica bridging.^{19,20}

The present study aimed to determine the association between bridging of the sella turcica and hypodontia, given the evidence of common embryonic origins and genetic basis of these structures.

MATERIALS AND METHODS

This is a cross-sectional analytical study, in which records of the orthodontic patients who came for orthodontic treatment during 2016 to 2018, were collected from archives of orthodontics unit, Tribhuvan university dental teaching hospital and one private orthodontic clinic of Kathmandu, Nepal.

Before conducting this study, ethical approval was taken from the Institutional Review Committee of Institute of Medicine, Tribhuvan University, Kathmandu, Nepal (Ref: 191/(6-11) E2, 2076/2077).

Study population

The clinical records along with the good quality of lateral cephalogram and orthopantomogram of 40 subjects (12 males and 28 females; mean age 13.9 years; SD 2.5 years) who came for orthodontic treatment and affected by dental hypodontia were collected from orthodontics unit, Tribhuvan university dental teaching hospital and one private orthodontic clinic of Kathmandu, Nepal.

A panoramic radiograph was evaluated for missing teeth except for third molars. A tooth was diagnosed as congenitally missing if the mineralization of its crown could not be identified on the orthopantomogram. However, exclusion criteria included subjects with systemic disease or craniofacial anomalies/Congenital syndrome, missing teeth due to decay processes, avulsions or extracted for orthodontics or other reasons and poor quality of radiographs.

Control group

The control group comprises of 120 subjects matched for age and gender without hypodontia (58 males and 62 females; mean age 14.1 years; SD 1.8 years) were randomly selected from those referred for orthodontic treatment at the same place and time frame. The exclusion criteria were the same as for the study population.

Cephalometric tracing of sella turcica

To quantify the extent of a sella turcica bridge from each lateral cephalograms of all cases and controls,

the contour of the pituitary fossa from the tip of the dorsum sellae to the tuberculum sella was traced on transparent acetate sheets in a darkened room on a laminator using a 0.5 mm lead pencil and was measured manually by one observer. On the sella turcica contour, 3 points were localized: TS (Tuberculum Sellae), DS (Dorsum Sellae) and PS (the farthest point on the inner wall of the sella). The sella turcica length (distance from TS to the tip of the DS) and anteroposterior greatest diameter (distance from TS to the PS) were measured (Fig. 1).

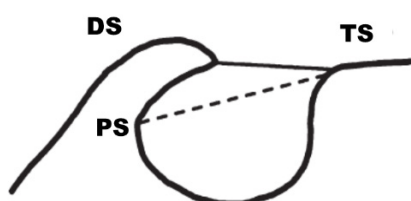


Figure 1: Normal sella turcica morphology and landmarks used for determining to bridge. TS, tuberculum sella; DS, dorsum sellae; PS, the farthest point on the inner wall of the sella. The sella turcica length represented by the black line, whereas the greatest anteroposterior diameter represented by a dashed line.

To evaluate and quantify the level of bridging, the standard scoring scale developed by Leonardi et al¹⁷ was used. Based on sella dimensions, the bridging was classified into three types (Fig. 2):

Type I: No bridging, when the length of sella was greater than three-fourths of the greatest antero-posterior diameter.

Type II: Partial bridging, when the length of sella was either equal to or less than three-fourths of the greatest antero-posterior diameter

Type III: Complete bridging, when there was radiographically visible diaphragm sellae.

Figure I

Figure II

Figure III

Fig. 2: I-No bridging, II-partial bridging, and III-complete bridging

Statistical Analysis

Data obtained were transferred to the MS-

excel sheet. The data were verified and analyzed statistically using SPSS Statistics Version 21.0 (Armonk, NY: IBM Corp.) with a confidence level set at 95% ($P < 0.05$) to test for significance. Data were descriptively analyzed. The association between sella turcica bridging and hypodontia as well as between sella turcica bridging and genders were estimated using the Chi-square test. For reliability of measurement, duplicate tracings of 35 radiographs selected randomly from cases and controls were made on two separate occasions by the same author with a 2 weeks interval between tracings and the random error was assessed (Houston, 1983). Sella measurement errors for both length and diameter between first and second measurements ranged from 0.12 to 0.19 mm, were considered non-significant.

RESULTS

Among 40 patients with hypodontia (study subjects), 12 (30%) were male and 28 (70%) were female. While in controls group having 120 patients without

hypodontia, 38 (31.66%) were male and 82 (68.33%) were female (Fig. 3). Chi-square statistics were computed to evaluate whether the conditional distribution of the degree of calcification for males was similar to that for females. The test was not significant (chi-square=0.970, $df= 2$, $P = 0.616$) suggesting no dependence between the degree of

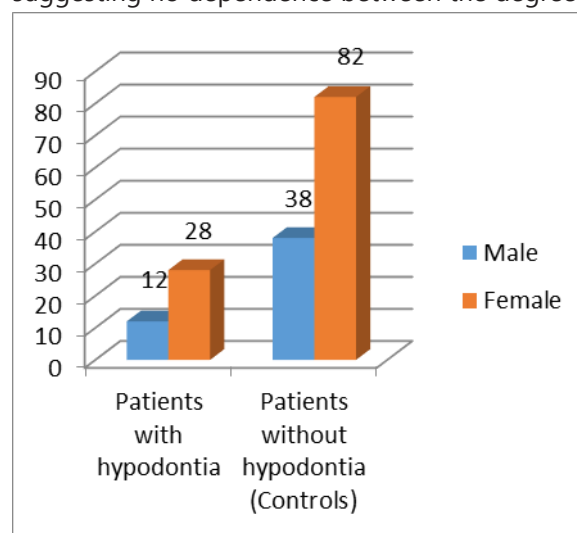


Fig. 3 Gender distribution in the patients

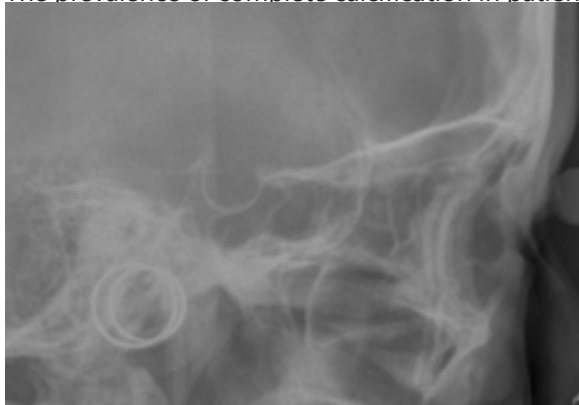The distribution of the degree of calcification of sella turcica in patients with hypodontia and without hypodontia is shown in Figure 4.

The prevalence of complete calcification in patients without hypodontia was 5%, while for those with hypodontia (Fig. 5), it was 17.5%. In patients without hypodontia, the prevalence of a partially calcified sella turcica was 37.5% and increased to 55% for patients with hypodontia (Fig 6). Similarly, no calcification or no bridging in patients without hypodontia was 57.5% while for those with hypodontia (Fig 7), it was 27.5% (Table 2).

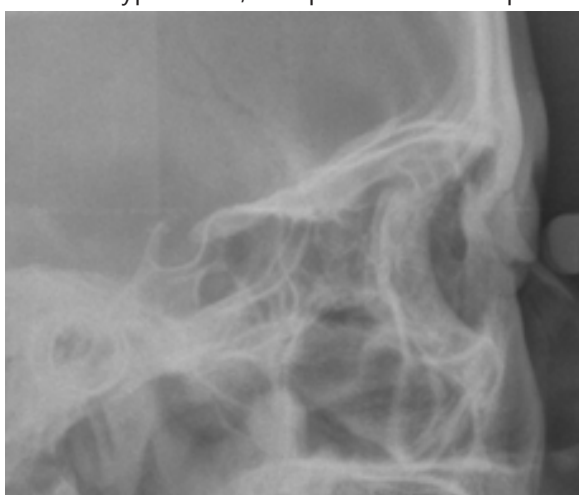The chi-squared test showed that the presence of partial and complete calcification of sella turcica in patients with hypodontia (cases) is significantly more frequent than in controls (chi-square=13.363, df= 2, p=0.001). Statistic confirmed that there is a significant association between sella turcica bridging and hypodontia (Table 2).

The distribution of the degree of calcification of sella turcica in patients with hypodontia and without hypodontia is shown in Figure 4.

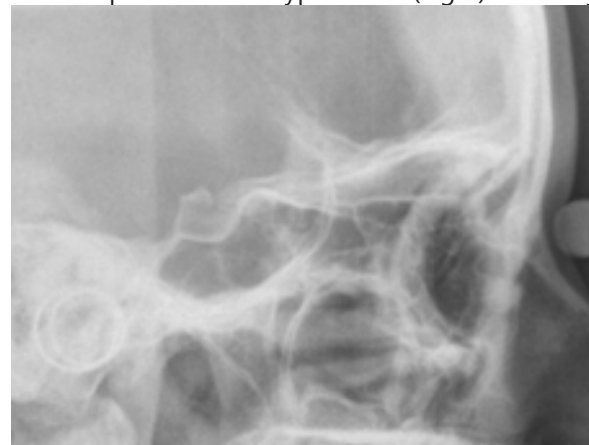The prevalence of complete calcification in patients



without hypodontia was 5%, while for those with hypodontia (Fig. 5), it was 17.5%. In patients without hypodontia, the prevalence of a partially



calcified sella turcica was 37.5% and increased to 55% for patients with hypodontia (Fig 6). Similarly,



no calcification or no bridging in patients without hypodontia was 57.5% while for those with hypodontia (Fig 7), it was 27.5% (Table 2).

The chi-squared test showed that the presence of partial and complete calcification of sella turcica in patients with hypodontia (cases) is significantly more frequent than in controls (chi-square=13.363, df= 2, p=0.001). Statistic confirmed that there is a significant association between sella turcica bridging and hypodontia (Table 2).

DISCUSSION

Bridging of the sella without clinical signs or symptoms is considered a normal,²¹ although some syndromes, craniofacial and dental abnormalities can be associated with this calcification.^{1,3,4,17,22} Some studies have advocated sella-turcica bridging as a diagnostic marker to alert clinicians of the potential presence of other disease entities/ anomalies.¹⁷

It has been shown that an interclinoid ligament (ICL) is laid down in cartilage at an early stage of development and ossifies later in early childhood. This ossification can be due to the complex embryology of the sphenoid bone.^{4,23,24} According to this theory, a sella turcica bridge should be considered a developmental anomaly. Along with this, the area anterior to the sella turcica develops predominantly from neural crest cells, hence any structural deviations in the anterior wall are believed to be related to specific deviations in the skeleton of facial region.²²

In this study, the prevalence of a sella turcica bridge was investigated in a group of patients with hypodontia (i.e. the absence of any tooth except

third molars) and compared with patients without hypodontia (controls). The data from this study suggest an incidence of 5% for complete bridging in the control sample. This result is slightly lower than the reported radiographic data of a sella turcica bridge in normal subjects.^{4,25} On the other hand, patients with hypodontia showed a frequency of 17.5 percent for a sella turcica bridge which is similar to that for subjects with severe craniofacial deviations.⁴ The presence of a partially calcified sella was also increased in patients with hypodontia (55 percent) versus the control group (37.5 percent). The finding of this study for complete bridging in controls (5%) was lower than the study by Shrestha et al. (11.67%) while for partial bridging, it was more (37.5%).²⁶

The finding of this studies is similar to other studies. Leonardi et al.¹⁷, after evaluating lateral cephalograms of Caucasians, reported increased incidence of sella-turcica bridging in individuals with palatally displaced canines (complete: 5.6%; partial: 77.8%) compared to controls (complete: 9.9%; partial: 33.7%). Similarly, Ali et al.'s²⁷ study of Pakistani patients found a higher prevalence of sella-turcica bridging in cases diagnosed with palatal canine impaction (complete: 25.8%, partial: 54.8%) compared to (complete: 0%; partial: 51.4%) sella-turcica bridging in the control group. Najim and Al- Nakib²⁸ studied the same association in an Iraqi population.

Molecular studies of odontogenesis in mouse tooth have shown that tooth development is under strict genetic control, which determines tooth number, position, shape, and size.^{29,30} Although tooth agenesis is occasionally caused by environmental factors, such as the trauma of the dental region or by multi-reagent chemotherapy or radiotherapy³¹, the majority of cases of hypodontia and oligodontia are due to genetic factors.

This study showed no dependence between the degree of calcification and gender which is following the study by Dixit et al.³² and Leonardi et al.¹⁷ The results of this study showed a significant association between sella turcica bridging and hypodontia which is following the study by Leonardi et al.¹⁷ that showed a significant association of sella turcica bridging in subjects with dental transposition and but contradictory to the Study by Pamela et al.³³ that showed no statistically significant association between tooth anomalies like maxillary palatal canine impaction and sella-turcica bridging.

CONCLUSION

The Sella turcica bridging is significantly associated with hypodontia. There is no dependence between the degree of calcification and gender. As the sella turcica bridge appears early in life, it should alert clinicians as a useful diagnostic predictor to the possible development of tooth anomalies later in life.

Acknowledgements

We would like to thank all the patients and their guardians for providing a consent to use their radiographs for this study.

REFERENCES

1. Sundareswaran S, Nipun CA. Bridging the Gap: sella turcica in unilateral cleft lip and palate patients. *Cleft Palate Craniofac J* 2015; 52: 597–604. <https://doi.org/10.1597/13-258> | PubMed
2. Heimer MV, Katz CR, Rosenblatt A. Anterior open bite: a case-control study. *Int J Paediatr Dent* 2010; 20: 59–64. <https://doi.org/10.1111/j.1365-263X.2009.01015.x> | PubMed
3. Meyer-Marcotty P, Reuther T, Stellzig-Eisenhauer A. Bridging of the sella turcica in skeletal Class III subjects. *Eur J Orthod* 2010; 32: 148–153. <https://doi.org/10.1093/ejo/cjp081> | PubMed
4. Becktor JP, Einersen S, Kjær I. A sella turcica bridge in subjects with severe craniofacial deviations. *Eur J Orthod* 2000; 22: 69–74. <https://doi.org/10.1093/ejo/22.1.69> | PubMed
5. Axelsson S, Storhaug K, Kjær I. Post-natal size and morphology of the sella turcica. Longitudinal cephalometric standards for Norwegians between 6 and 21 years of age. *Eur J Orthod*. 2004; 26: 597–604. <https://doi.org/10.1093/ejo/26.6.597> | PubMed
6. Alkofide EA. The shape and size of the sella turcica in skeletal Class I, Class II, and Class III Saudi subjects. *Eur J Orthod* 2007; 29: 457–463. <https://doi.org/10.1093/ejo/cjm049> | PubMed
7. Muller TP, Hill I N, Petersen A C 1970 A survey of congenitally missing permanent teeth. *Journal of the American Dental Association* 81: 101–109. <https://doi.org/10.14219/jada.archive.1970.0151> | PubMed
8. Nunn J H et al. 2003 The interdisciplinary management of hypodontia: background and role of pediatric dentistry. *British Dental Journal* 194: 245–251. <https://doi.org/10.1038/sj.bdj.4809925> | PubMed
9. Murdock S, Lee JY, Gickes A, Wright J T 2005 A cost analysis of dental treatment for ectodermal dysplasia. *Journal of the American Dental Association* 136: 1273–1276. <https://doi.org/10.14219/jada.archive.2005.0343> | PubMed
10. Sathyanarayana HP, Kailasam V, Chitharanjan AB.

- Sella turcica-its importance in orthodontics and craniofacial morphology. *Dent Res J (Isfahan)* 2013; 10: 571–575. [PubMed](#)
11. Miletich I, Sharpe PT. Neural crest contribution to mammalian tooth formation. *Birth Defects Res C Embryo Today* 2004; 72: 200–212. <https://doi.org/10.1002/bdrc.20012> | [PubMed](#)
 12. Sharpe PT. Neural crest and tooth morphogenesis. *Adv Dent Res* 2001; 15: 4–7. <https://doi.org/10.1177/08959374010150011001> | [PubMed](#)
 13. Ali B, Shaikh A, Fida M. Association between sella turcica bridging and palatal canine impaction. *Am J Orthod Dentofacial Orthop.* 2014; 146: 437–441. <https://doi.org/10.1016/j.ajodo.2014.06.010> | [PubMed](#)
 14. Larsen WJ, Schoenwolf GC, Bleyl SB, Brauer PR, and Francis-West PH, *Larsen's Human Embryology*, Elsevier/Churchill Livingstone, Philadelphia, Pennsylvania, 5th edition, 2009. [Full Text](#)
 15. Prarthna B, Saurabh S, Batra P, Dhillon M. Sella turcica morphology – a diagnostic marker for skeletal class II malocclusion. *J Dent Specialties.* 2015;3:22–28. [Full Text](#)
 16. Kucia A, Jankowski T, Siewniak M, et al. Sella turcica anomalies on lateral cephalometric radiographs of Polish children. *Dentomaxillofac Radiol.* 2014;43(8):20140165. <https://doi.org/10.1259/dmfr.20140165> | [PubMed](#)
 17. Leonardi R, Barbato E, Vichi M, Caltabiano M. A sella turcica bridge in subjects with dental anomalies. *J Orthod.* 2006;28(6):580–585. <https://doi.org/10.1093/ejo/cj032> | [PubMed](#)
 18. Leonardi R, Farella M, Cobourne MT. An association between sella turcica bridging and dental transposition. *Eur J Orthod.* 2011;33(4):461–465. <https://doi.org/10.1093/ejo/cjq106> | [PubMed](#)
 19. Najim AA, Nakib LA. A cephalometric study of sella turcica size and morphology among young Iraqi normal population in comparison to patients with maxillary malposed canine. *J Baghdad Coll Dent.* 2011;23:53–58. [Full Text](#)
 20. Ali B, Shaikh A, Fida M. Association between sella turcica bridging and palatal canine impaction. *Am J Orthod Dentofacial Orthop.* 2014;146(4):437–441. <https://doi.org/10.1016/j.ajodo.2014.06.010> | [PubMed](#)
 21. Kantor M L, Norton L A 1987 Normal radiographic anatomy and common anomalies seen in cephalometric films. *American Journal of Orthodontics and Dentofacial Orthopedics* 91:414 – 426. [https://doi.org/10.1016/0889-5406\(87\)90394-5](https://doi.org/10.1016/0889-5406(87)90394-5) | [PubMed](#)
 22. Kjær I, Beكتور KB, Lisson J, Gormsen C, and Russell BG. "Face, palate, and craniofacial morphology in patients with a solitary median maxillary central incisor," *Eur J Orthod.* 2001; 23(1):63–73. <https://doi.org/10.1093/ejo/23.1.63> | [PubMed](#)
 23. Hochstetter F. Über die Taenia interclinoidea, die Commissura alicochlearis und die Cartilago supracochlearis und die Cartilago supracochlearis des menschlichen Primordiakraniums. *Gegenbaurs Morphologisches Jahrbuch* 1940; 84: 220 – 243
 24. Lang J. Structure and postnatal organization of heretofore uninvestigated and infrequent ossific cations of the sella turcica region. *Acta Anatomica* 1977; 99:121 – 139. <https://doi.org/10.1159/000144840> | [PubMed](#)
 25. Cederberg RA, Benson BW, Nunn M, English JD. Calcification of the interclinoid and petroclinoid ligaments of sella turcica: a radiographic study of the prevalence. *Orthodontics & Craniofacial Research* 2003;4:227 – 232. <https://doi.org/10.1034/j.1600-0544.2003.00243.x> | [Full Text](#)
 26. Shrestha GK, Pokharel PR, Gyawali R, Bhattarai B, Giri J. The morphology and bridging of the sella turcica in adult orthodontic patients. *BMC Oral Health.* 2018;45:4-8. <https://doi.org/10.1186/s12903-018-0499-1> | [PubMed](#)
 27. Ali B, Shaikh A, and Fida M. "Association between sella turcica bridging and palatal canine impaction," *Am J Orthod Dentofacial Orthop.* 2014;146(4):437–441. <https://doi.org/10.1016/j.ajodo.2014.06.010> | [Full Text](#)
 28. Najim AA and Al-Nakib L. "A cephalometric study of sella turcica size and morphology among young Iraqi normal population in comparison to patients with maxillary malposed canine," in *Journal of Baghdad College of Dentistry.* 2011;23:53–58.
 29. Thesleff I. The genetic basis of normal and abnormal craniofacial development. *Acta Odontologica Scandinavica* 1998;56:321 – 325. <https://doi.org/10.1080/000163598428248> | [PubMed](#)
 30. Peters H, Balling R. Teeth: where and how to make them. *Trends in Genetics* 1999;15:59 – 65. [https://doi.org/10.1016/S0168-9525\(98\)01662-X](https://doi.org/10.1016/S0168-9525(98)01662-X) | [PubMed](#)
 31. Näsman M, Forsberg CM, Dahllöf G. Long-term dental development in children after treatment for malignant disease. *European Journal of Orthodontics* 1997;19:151–159. <https://doi.org/10.1093/ejo/19.2.151> | [Full Text](#)
 32. Dixit S, Kafle D, Bornstein M, Sanjel S. Sella Turcica Bridging as a Predictor of Dentofacial Anomalies: A Cephalometric Analysis. *Orthod J Nep.* 2017; 7(2): 32-36. <https://doi.org/10.3126/ojn.v7i2.20162> | [Full Text](#)
 33. Pamela M. Ortiz, Sawsan Tabbaa, Carlos Flores-Mir, and Thikriat Al-Jewair. A CBCT Investigation of the Association between Sella-Turcica Bridging and Maxillary Palatal Canine Impaction. *BioMed Research International.* 2018: 1-9. <https://doi.org/10.1155/2018/4329050> | [Full Text](#) Google Scholar