

Osteoporotic vertebral fracture: Our Experience and update

Krishna Sharma¹, Maya Bhattachan¹, Raj Kumar Bhatta¹, Praveen Kumar Singh¹

¹Department of Neurosurgery, Nepal Medical College Teaching Hospital, Jorpati, Kathmandu

Correspondence:

Dr. Krishna Sharma

Department of Neurosurgery

Nepal Medical College Teaching Hospital, Jorpati, Kathmandu

Email:krishnasharma@yahoo.com

Introduction: Osteoporotic vertebral fracture is a fragility fracture due to osteoporosis and is a growing public health problem. It mainly affects postmenopausal women and men > 50 years. It significantly affects morbidity, financial condition, quality of life and mortality of patients. It presents mainly with back pain, which is mostly manageable with conservative measures. Those with unrelieved pain, severe spinal deformity or neurological impairment would require intervention. The quality of bone and surgical fitness along with associated co-morbidities of these elderly people, require special consideration, indications and appropriate modification of technique and instruments for surgical intervention. **Materials and methodology:** This prospective study summarizes the management of osteoporotic vertebral fractures from September 2015 to September 2021 in Nepal Medical College, Kathmandu, Nepal. The study included patients with back pain of more than 50 years old age. The backpain was evaluated clinically using visual analogue scale and Oswestry Disability Index, neurological deficits using Frankel grading system and deformity using X-ray. Other investigations included MRI, Dexa scan, Serum calcium and Vitamin D3. Risk factors for developing osteoporosis and OVF were also assessed. **Results:** Out of the 630 patients of more than 50 years age, presenting in neurosurgical OPD with backache from September 2015 to September 2020, 158 cases were later diagnosed to have osteoporotic spine fractures. There were 122 (77.2%) postmenopausal ladies and 36 (22.8%) gentlemen. All had backpain, with 36% having VAS score of < 3 and 64% had ODI of mild to moderate disability. The neurological deficits were present in 16.4% and mostly were Frankel grade C and D. Significant kyphoscoliosis (Cobb angle more than 20 degrees) in X-ray was present in 18 (11.3%) patients. 88 (55.7%) patients had Dexa scan and T score was less than -2.5 in 88 (56%). Serum calcium was low in (41) 26% and Vitamin D3 was low in (107) 67.7% of the patients. For backpain, all were started on non-operative management. Vertebral augmentation procedure was not available in our institute. Thus, surgery was offered in 44 (28%) of the patients but only 18 (11.4%) agreed for surgery and underwent decompression with long segment fixation. Only 48 patients remained in follow up for more than 2 years and all had satisfactory control of pain with no deterioration in deformity or neurological deficit. There were no significant short or long-term complications or mortality. **Conclusion:** Osteoporotic vertebral fracture is a very common reason for back pain in people of more than 50 years old affecting their livelihood. The majority responded to conservative treatment. Those indicated for surgery need special consideration in preparation, technique and devices. Preventive measures can help reduce the problem load.

Key Words: Osteoporotic Vertebral Fracture, Backpain, Conservative Management, Surgery

Low backache affects 36% to 70 of adults, especially those > 50 years of age. ¹ Osteoporosis is becoming a very common cause of backache in this age group. Since the management of osteoporotic vertebral fractures (OVF) differ from other causes of low backache, identification of the pathology in time and applying the appropriate treatment strategy becomes vital to achieve good recovery. In this study, we have tried to understand the problem of OVF in our society and the response to the management guided by recent scientific literature.

Materials and Methods

This prospective study presents the load of OVF in adults of more than 50 years and their presentations and response to management in patients presenting to Nepal Medical College, Kathmandu, Nepal, from September 2015 to September 2021. Among the 630 patients of more than 50 years age presenting with low backache during the period, 158 patients were later diagnosed to have OVFs. There were 122 (77.2%) postmenopausal ladies and 36 (22.8%) gentlemen. The

3 Submitted:15/03/2024

Accepted: 20/03/2024

inclusion criteria were vertebral fractures presenting with backache, deformity, or neurological deficit. The pathological fractures secondary to tumors, infections or metabolic bone diseases, previous surgical interventions, and severe degenerative spine with stenosis were excluded. The backpain was evaluated using visual analogue scale (VAS)² and Oswestry Disability Index (ODI) .^{3,4}

VAS score	Patient number	Percentage
Equal and less than 3	38	24
Between 3 to 7	93	59
Between 7 to 10	27	17

ODI score and disability	Patient number	Percentage
No disability (0-4 score)	16	10.1
Mild (5-14)	74	46.9
Moderate (15-24)	54	34.2
Severe (25-34)	14	8.8
Completely disabled (35-50)	0	0

The neurological deficits were measured using Frankel grading system,⁵ the details are as follows:

Frankel Grade	Description	Patient number	Percentage
A	Complete	0	0
B	Sensory only	0	0
C	Motor useless	6	3.9
D	Motor useful	36	22.7
E	Normal	116	73.4

X-ray of the whole spine was performed (Figure 1). The osteoporotic changes were seen only below T6 levels, with different types of deformed vertebrae, as described by Sugita et al.⁶ Single level was involved in 46 (29.1%) and multiple level in the rest. Significant collapse of anterior margin with Cobb angle of more than 20% or 4mm reduction in height, were seen in 18(11.4%). MRI showed compression of the spinal cord in 46 (29.11%), and more than 50% canal encroachment (Figure 2). DEXA scan was suggested to all but could be performed in 55.7% of the patients only.

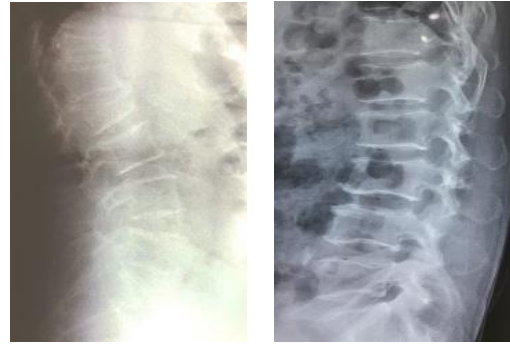


Figure 1: X-ray thoracolumbar lateral views of multilevel thoracolumbar OVF

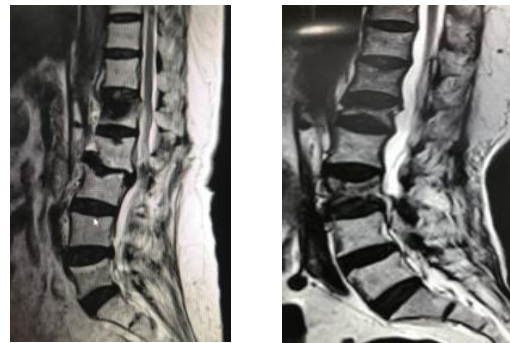


Figure 2: MRI T2WI L-S spine sagittal views of OVF showing more than 50% canal encroachment.

Bone mineral density (BMD)	T-score	No. of patients (total of 88)	Percentage
Normal	-1 or above	None	
Osteopenia	-1 to -2.5	36	40.9
Osteoporosis	At or below -2.5	52	59.1%

Serum calcium and Vitamin D3 were estimated in all patients. Serum Calcium level was found low in 26 (16.4%) patients and Vitamin D3 level was below 30 nanogram/milliliter was found in 126 (79.7%). Risk factors for developing osteoporosis and OVF were also assessed.

Risk factors	No. of patients	Percentage
Sex	122	77.2
Postmenopausal ladies	36	22.8%
Gentlemen		
Age less than 65	89	56.3
More than 65	69	43.6
Smoker > 20 cigarettes/day	123	77.8
Alcohol (>60gm/day)	98	62
Family history of osteoporotic fracture	36	22.7
Menopause before 45 years of age	21 out of 122 ladies	17.2
Prolonged glucocorticoid therapy for more than three months	15	9.4%
Medical problems known to cause osteoporosis	23	14.6%

The patients were treated on an OPD basis. Out of the 158 patients, 140 (72%) were managed conservatively and 18(11.3%) surgically. Pain was treated with NSAIDS (Non-steroidal Anti-inflammatory Drugs), bed rest during acute and severe pain, thoraco-lumbar brace for 3 weeks. Opioids (Tramadol) were used in cases unresponsive to NSAIDS. Physiotherapy was started when the acute pain subsided. Depending on the BMD report, tab Alendronate was started (70mg once a week) for osteopenia and osteoporosis and followed with repeat BMD every 3 months. Teriparatide was used in those with severe pain and osteoporosis for 1 month and monitored using BMD. Tab Calcium (500mg twice a day) and Vitamin D3 (60000 IU once a week) was given in those who had low levels in blood and monitored with repeated blood tests. 44 patients with severe and unresponsive pain, significant deformity and neurological deficits were advised for surgical intervention. Since the facility of Vertebral Augmentation is not available, these patients were offered surgery. However, only 18 (11.4%) of these agreed for surgery. They underwent decompression and long segment fixation and fusion (Figure 3). Postoperatively, they were continued on anti-osteoporotic drug (Alendronate), Calcium and Vitamin D3. The brace was continued for 6 weeks, and physiotherapy was started as soon as the postoperative pain got subsided.

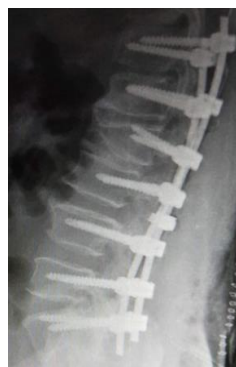

Figure 3: x-ray L-S spine lateral view with OVF showing long segment pedicle fixation

Postoperatively, the low backpain gradually subsided significantly to a VAS score < 3, ODI disability improved to “no disability” and “mild disability” and there was neither deterioration nor improvement neurologically, assessed by Frankel grade. None of those managed conservatively deteriorated to require surgery. There was no deterioration in kyphoscoliosis in X-ray. BMD improved to more than -1 T score in all by 9 months. There was no hard-ware failure, in follow up for 2 years in the surgical group and they had improvement in activities of daily living (ADL) and Quality of life (QOL).

Discussion

Osteoporosis is an increasingly prevalent chronic metabolic bone disease,⁷ defined as a reduction in bone mass and qualitative skeletal changes. It includes changes in macro- and micro-architecture, material properties, geometry, and micro-damage, that cause an increase in bone fragility and higher fracture risk.^{8,9,10} WHO defined osteoporosis as BMD 2.5 SD or more below the average value for young healthy women (a T-score of less than -2.5 SD). “Low bone mass” or osteopenia is defined as a T-score that lies between -1 and -2.5 SD in a DEXA scan.¹¹ When fracture occurs in an osteoporotic vertebra, it is called OVF. When there is one or more proven fragility fractures in the body, osteoporosis is said to be severe. OVF occurs in approximately 25% of postmenopausal women and elderly men. Elderly men have much lower OVF risk than elderly women even at advanced age.¹² Osteoporosis is associated with lowered Quality of life¹³ and high morbidity, mortality, along with high social costs making osteoporosis an important public health problem.^{8,14,15,16,17}

Epidemiology: Vertebral compression fractures (VCF) are the most common fragility fracture precipitated by minor trauma. Over 80% of all fractures in people of > 50 years old are associated with osteoporosis. The incidence is increasing in tandem with the increased life expectancy of the senior population. The risk of OVF doubles between the ages of 60 and 90 years. After one VCF, there is a 2-3 times greater

chance of developing another osteoporotic fracture elsewhere in the body.¹⁸ More than one fragility fracture is found in 20% to 30% of OVF patients. Twenty percent of women who have OVF would develop another fragility fracture within the next year. The lifetime risk of developing any osteoporotic fracture is 40-50% in ladies and 13-22% in gents.¹⁸ In the US, there is an annual incidence of 700,000 VCF at a cost of over \$15 billion.¹⁹

Pathophysiology: In osteoporosis, bone turnover is typically high, with a net loss of bone density as a result of the rate of bone breakdown exceeding the rate of bone production. Trabecular bone mass is lost, although cortical bone is mostly preserved. There is increased endosteal resorption, suppression of periosteal bone growth, and bone marrow expansion. Consequently, the bones become more porous, brittle, and prone to fracture.²⁰ The typical peak age for lumbar spine BMD in women is between 33 and 40 years, whereas in men it is between 19 and 33 years. Age-related declines in BMD occur after peak mass, and it has a strong correlation with bone strength and is a reliable indicator of fragility fracture.⁷ Osteoporosis could be primary or secondary. Age and hormonal changes causing estrogen deficit, like in menopause is the main cause of primary or involutional osteoporosis.²¹ Secondary osteoporosis could be due to the side effects of medicines, alcoholism, different kinds of diseases and medical conditions like hypercalciuria, and hyperthyroidism.^{22,23} Regional osteoporosis could be caused by immobilization or disuse, reflex sympathetic dystrophy syndrome, or transient osteoporosis of large joints.²⁴ The vertebral column, the proximal ends of the femur and humerus, and the distal end of the radius are the most sites of osteoporotic fractures.²⁵ The fracture is considered acute if the fracture is of < 2 weeks, sub-acute if it is between 2 weeks to 3 months and chronic if the fracture is of > 3 months old.²⁶ Genome-wide association studies have located several genetic loci associated with low BMD and a higher risk of vertebral fracture.^{27,28}

Clinical fractures: Osteoporosis usually advances without causing any symptoms until a bone fracture occurs, and thus it is sometimes referred to as a "silent disease". The common presentations are^{29,30,31,32,33} Backpain is the most common presentation, which is assessed by VAS score and ODI. 25% of VCF are painful enough to compromise functional loss and disturbed ADLs. The pain is usually localized to area of fracture but may wrap around rib cage. There is focal tenderness which increases on deep palpation of spinous process. The pain is of two types: In Type I, the pain is acute and severe but improves gradually. X-ray shows vertebral wedging and remains unchanged. The pain lasts for about 4 to 8 weeks. Bone mineral density is lower in type I than Type II. A short-term calcitonin therapy helps early relief and mobilization. In Type II, the pain is less and shorter duration, but after 6 to 16 weeks, a new attack of pain occurs, which is

repeated the next 6 to 18 months. X-ray does not show the fracture clearly during the first attack but wedging gradually develops.³⁴

- Neurological deficits: They can have radiculopathy due to foraminal stenosis. Signs of spinal cord compression are very rare.
- Spinal deformities: There might be local kyphosis due to multiple compression or wedge fractures. It is considered significant if Cob angle is > 20 degree and is present only in 6% of these patients. The patients may not be able to stand upright and has protruded abdomen along with GI symptoms like distension, constipation, satiety and eructation.¹³ There is progressive loss of height and is considered relevant if the loss of height is > 6 cm.
- Psychological distress is found in almost 40% cases
- There is a compromised pulmonary function due to anterior wedging of the spine with reduced and deformed thoracic cavity. Each spinal level vertebral VCF leads up to 9% reduction in functional tidal volume. There is 15% increased risk of mortality from this pulmonary dysfunction.³³ All the above features lead to compromised ADL and decline in QOL.^{13,26}

Investigations: Imaging plays a key role in the diagnosis and prognostication of OVF.^{34,35,36} X-ray should include the entire spine as there might be concomitant spine fractures in 20% to 30% of cases. X-rays will show the presence of vertebral fractures, involved levels and its types, resulting deformities, intra-vertebral cleft and loss of vertebral height which is considered significant if it is reduced by 20% or at least 4 mm.³⁷ The features of osteoporosis are increased radiolucency (osteopenia) and cortical thinning, which is described as a "picture framing" or "empty box". The fracture lines are difficult to recognize owing to severe osteoporotic changes with a high false negative rate in almost 24%.³⁸ The dynamic X-ray would show instability or non-union. About half of OVFs were under-reported, especially the mild cases^{39,40} due to normal variation in height, developmental abnormalities, degenerative changes, Scheuermann's disease and large Schmorl's nodes.³⁸ The visual semi-quantitative method⁴¹ provides reasonable reproducibility, sensitivity, and specificity when used by expert radiologist.⁴⁰ CT scan can show the bony encroachment in spinal canal better.^{42,43} Multiple detector CT can be more informative but is expensive with greater radiation exposure.⁴⁴ MRI is recommended in those with neurological deficits, significant deformities, extreme discomfort and pain, and to rule out other pathologies. High resolution MRI and specialized MRI sequences including dynamic contrast-enhanced imaging and diffusion-weighted MR imaging can show the micro-architecture of the bone better, helping in early diagnosis of osteoporosis. Other newer useful investigative tools include PET, SPECT, and Micro-CT scan.^{45,46} Addition of artificial intelligence to the above investigations improves the sensitivity by 20.8% and can be used as a complementary tool in routine diagnostic reports to reduce missed OVFs.⁴⁷ **Densitometry:** BMD test is a measure

of calcium and other mineral in bone,⁴⁸ determined by dual-X-ray absorptiometry (DXA). It is the most important predictor of osteoporotic fractures. It is useful for diagnosis, prognostication, and follow-up. Indications of densitometry include,^{49,50,51} women of any age with a major risk factor or postmenopausal women with at least three or more of the minor risk factors. Osteoporotic-like vertebral fracture with less than 20% height loss is associated with increased risk of further vertebral fracture.¹⁰

Major risk factors	Minor risk factors
Age more than 75 years	Age greater than 65 years
Previous fragility fracture caused by minimal trauma	Family history of severe osteoporosis
Maternal family history of osteoporotic fracture ²⁸	Premenopausal amenorrhea for a period greater than 6 months
Menopause before 45 years of age	Inadequate calcium intake (<1200mg/day)
Body mass index (BMI) less than 19 kg/m ²	Smoking > 20 cigarettes/day
Prolonged glucocorticoid therapy for >3 months	Alcoholism (>60gm/day)
Malabsorption syndrome	Male osteoporosis
Primary hyperparathyroidism	Rheumatoid arthritis
Osteopenia apparent in X-ray	Chronic anticonvulsant therapy
Propensity to fall	Excessive caffeine uptake
Hypogonadism	Weight 57 Kg or more
	Weight loss 10% of weight at age of 25 years
	Type I diabetes

A few novel imaging modalities are being researched with the purpose of improving screening and detecting osteoporosis earlier. A few examples are novel spectral CT, dual-energy CT, quantitative computed tomography scans and novel MRI sequences.⁵² With the modified Dixon MRI sequence, a volumetric evaluation of bone mineral density⁵³ and Bone Marrow Fat Fraction can be measured, predicting abnormal bone density.⁵⁴ DWI has the potential of effective integration with AI approaches. In Bone Scintigraphy, radiotracer uptake is increased in a linear pattern, and it allows bone metabolism visualisation.⁵⁵

Biochemical assessment: Vitamin D3 and serum calcium levels are typically low in osteoporosis. Bone Turnover Markers especially the markers of bone production like Serum total alkaline phosphatase, serum bone-specific alkaline phosphatase, serum osteocalcin, and serum type 1 procollagen (C-terminal/N-terminal): C1NP or PINP are decreased. The markers for bone resorption are raised, typically urinary hydroxyproline, urinary total pyridinoline, urinary free deoxypyridinoline, urinary collagen type 1 cross-linked N-telopeptide, urinary or serum collagen type 1 cross-linked C-

telopeptide, urinary bone sialoprotein, and tartrate-resistant acid phosphatase 5b .^{56,57}

Differential Diagnosis to be considered is degenerative diseases, traumatic fractures, and primary tumours like multiple myeloma, metabolic bone diseases and secondary metastasis. Other pathologies are infections and inflammatory conditions like tuberculosis, bacterial infections, fungal infections, etc.^{58,59} These pathologies can also co-exist with osteoporotic fractures.⁶⁰

Management: The goals of management of OVF are to reduce pain, to prevent and correct complications like fracture and deformities, to prevent and reverse neurological deficits, to perform timely fracture-risk assessment and institute preventive measures; thus improving quality of life and reducing mortality.¹² Different guidelines have been developed to manage OVF more efficiently.^{13,16,17,61,62,63} OVF is a complex problem needing multimodal approach; broadly conservative or surgical treatment.^{16,64}

Conservative: The primary treatment of OVF is controlling backache and improving functional outcome. It is initially done by conservative methods.^{26,65,66} The acute pain is usually relieved after 6 to 12 weeks.⁶⁷ The management could be divided into pharmacological and non-pharmaceutical.

Pharmacological methods: Analgesics like Acetaminophen and NSAIDs were commonly used.⁶⁸ However, NSAIDs cannot be used for long due to its side effects including slowed bone healing and non-union.⁶⁹ In none-responders, opioids like oxycodone are second line therapy but their prolong use can cause addiction, decreased gastrointestinal motility, respiratory dysfunction, cognitive impairments with risk of falls, and depression.⁷⁰ Anti-osteoporotic agents relieve pain in addition to their osteogenesis properties.⁶⁸ These include Bisphosphonates like Alendronate, Risedronate, Ibandronate and Zoledronic acid. Their use and duration are guided by BMD.¹⁴ Anabolic substances and antiresorptive drugs including parathyroid hormone and are used for chronic pain. In clinical use, Teriparatide, a synthetic form of the natural human parathyroid hormone, is available. This helps to relief chronic pain, induce osteogenesis, improve BMD and bone strength, thus lowering the risk of subsequent fracture.^{71,72} It has been shown to increase the insertional torque of pedicle screws during fusion surgery.⁷³

Data from the Women's Health Initiative trial showed that Hormone Replacement Therapy with conjugated estrogens plus medroxyprogesterone acetate prevents osteoporosis fracture in postmenopausal ladies.⁷⁴ There is about 34% reduction in the incidence of hip fracture and 24% reduction in overall fractures, regardless of baseline BMD. Nowadays Raloxifene, a selective oestrogen receptor modulator, is available which does not have other unwanted side effects of

oestrogen hormone. Denosumab, a Human monoclonal antibody, is an antiresorptive drug for limiting osteoclast mediated bone resorption.⁷⁵ Calcitonin is effective for relieving chronic back pain.⁷⁶ Supplementation with Calcium (1000mg/day) and vitamin D (800 IU/day) is recommended when there is deficiency of these elements.^{77,78,79} Antidepressants like Tricyclics, and monoamine oxidase inhibitors help to overcome the associated depression and anxiety.⁸⁰

Non-pharmaceutical methods

- Short-term bed rest during acute pain.⁸¹
- Physiotherapy strengthens muscle,⁸² reduces edema and pain, prevents and reduces falls in elderly, improves postural stability, gait and deformity, reduces contractures and stiffness. This facilitates mobility as well as boosts confidence and finally improves QOL.^{83,84,85} Physiotherapy helps to maintain bone density, increases peak bone mass and prevent further osteoporotic fractures of the spine.^{83,84,86,87}
- Braces promote fracture healing by stabilizing spine, allow faster mobilization, reduce pain and fatigue, and prevent postural forward flexion and deformity, collapse and neurological deficits, thus significantly improving activities of daily living, functional outcome and QOL.^{6,88,89} The recommended arthrosis is a three-point contact braces, hyperextension orthoses, a Jewett brace, or thoracolumbar sacral orthoses.^{88,89,90} Braces are less invasive, relatively safe, and inexpensive.⁹¹ However, prolonged use for more than three months may increase stiffness in elderly, produce sores, decrease pulmonary function, reduce muscle mass and remain uncomfortable, leading to high rates of noncompliance.^{65,92}
- A tailored rehabilitation program based on balance and muscle strength tests is an effective treatment option for basic motor function improvement and disability reduction.^{93,94,95}

Surgical intervention: Approximately 15%–35% of OVF, develop persistent pain, poor chest function, progressive deformity, and neurological deficit with conservative treatment alone, requiring further intervention.^{96,97} The role of surgical treatment remains controversial and should be reserved for those who fail initial nonsurgical management options.⁶⁴ Broadly, the surgical options include,

- Minimal invasive techniques like Vertebral Augmentation (VA) are vertebroplasty (VP), Kyphoplasty (KP) and Radiofrequency Kyphoplasty (RFK).⁹⁸
- Short-segment fixation with cement augmentation, a hybrid technique.^{99,100,101}
- Long segment fixation using pedicle screws.^{102,103,104}

Minimal invasive technique for VA includes percutaneous image guided injection of bone cement or artificial bone into the vertebra to reduce pain and increase its strength.¹⁰⁵ It can reduce pain by 98% during the acute phase due to elimination

of micromotion and thermal reaction of polymethyl methacrylate cement.⁸⁷ It is not performed to correct deformity, but it does help in stability, prevent further deterioration of deformity¹⁰⁶ and improve sagittal balance.¹⁰⁷ VA is associated with longer patient survival than non-operative treatment^{108,109} and has shown greater and faster improvement in Health-related quality of Life. However, on longer follow-up, back pain and HRQOL failed to demonstrate a difference.¹¹⁰ It is a very commonly performed procedure nowadays. However, but the procedure had got very unpopular temporarily following publication of 2 double-blind, randomized controlled trials (RCTs) (Investigational Vertebroplasty Safety and Efficacy Trial, INVEST and A Randomized Trial of Vertebroplasty for Painful Osteoporotic Vertebral Fractures) in 2009, which showed small improvement in pain with many potential complications.^{102,98,111} However, it is now the most performed surgery for OVF. It is cost-effective compared with nonsurgical management.^{112,113} The procedures include VP, KP and RFK.^{98,114,115,116,117} A meta-analysis suggested facet joint block may be considered complementary to VA in the management of residual back pain.¹¹⁸ Further details of each of these procedures could not be discussed in this article.

The complications of the procedures include

- Cement extravasation occurring in 87.5% for VP and 49.2% in KP leading to embolization and anaphylactic shock, but these are mostly insignificant and asymptomatic.^{119,120,121}
- Index level re-fracture of vertebra can occur if there is preoperative intravertebral cleft in x-ray, severe kyphosis, thoracolumbar osteoporotic vertebral fracture, solid lump cement distribution pattern with increased stiffness, higher vertebral height restoration, abnormal mechanical load, unusual loading distribution and decreased spinal motion and load failure.^{118,122,123}
- Adjacent-segment fracture can occur in 2% to 23% in KP and up to 52% in VP, occurring within 2 months after Vertebral Augmentation. This can be reduced by restoring sagittal balance and physiological loading.^{108,124,125}
- Delayed neurologic deficit and pain is seen 2% in KP and 3.9% in VP,¹²⁶ which could be due to instability. Stabilization therapy has an important role to play in these cases.¹²⁷
- Vertebral body osteonecrosis (aka Kummell's disease) and delayed post-traumatic osteonecrosis are rare complications.¹²⁸

A consensus statement from American and Canadian Societies state that vertebral augmentation procedure is a safe, efficacious, and durable procedure in appropriate patients with symptomatic osteoporotic fractures, when performed in a manner in accordance with published standards. It is to be offered only when non-operative medical therapy has failed

and it provides significant improvement in pain and function, particularly ambulation.¹²⁹

Surgery: Open surgical procedures are performed in those who fail conservative treatment and are not suitable for VA procedure. So, the indications for surgery are^{96,97,130,131} unstable fracture, persistent intractable back pain of VAS score >3, not responding to conservative management and affecting ADL and QOL, kyphosis of Cob angle more than 20 degrees, severely collapsed vertebra that causes a neurologic deficit¹³², a significant retropulsed bony fragment and chronic pseudarthrosis^{133,134}. The details of open surgery should be decided on a case-to-case basis. Broadly, surgical procedure includes decompression, fixation, and fusion with deformity correction or restoration of vertebral height. However, superiority of one technique to another is not well known and the decision must be made according to surgeon's choice. However, pedicle screw and other fixation alone should be avoided in patients with a bone mineral density < 0.3 g/cm².^{135,136} In this situation, one needs to modify surgical techniques, instruments and screws.¹³⁷ The modification includes multilevel fixation, cement augmentation, avoiding ending the instrumentation at the apex of kyphosis.¹³⁸ The technique and the instrument also need to be modified, like:

- Screws with larger diameters,^{139,140} longer screws penetrating anterior cortex, expandable screws^{141,142} that improve the bone-screw interaction¹⁴³ and pull-out strength.
- A greater number of screws and longer fixation with more fixation points are to be used. Combined anterior and posterior approach gives better stability¹⁴⁴. A minimum of three fixation points should be placed above and below the deformity's apex.¹⁴⁵
- Use of concomitant anchors and if necessary sublaminar wire and hooks makes the fixation rigid and stable.^{134,146,147}
- Supplementary interbody fusion and osteotomy provide anterior column support and thus enhances fusion, improves strength and achieves a good sagittal balance.¹⁴⁸
- Screw insertion is to be done with a triangulation trajectory and engage sub-chondral bone.¹⁴⁹ Penetration into the contralateral vertebral body cortex when performing anterior instrumentation may increase the rigidity.
- When the screw is under-tapped by 1 mm, screw purchase can be improved in the pedicles.¹⁵⁰
- Cement augmentation along with use of cannulated screws or VP helps to strengthen the grip and increase the screw pull out strength.^{151,152} However, increasing cement volume does not have any effect on pull out strength.
- Forceful correction of deformity may loosen the screws and fail to achieve rigid fixation. In these cases, incomplete correction of the deformity may have to be accepted.
- Hybrid procedure can be performed which includes short segment fixation combined with vertebral augmentation procedure.¹⁵³

The complications of surgery could be implant-failure, pseudoarthrosis, screw loosening, proximal and distal junctional kyphosis, and loss of correction. It is an additional challenge to operate on these patients due to old age, delayed wound healing, associated co-morbidities, generalized diseases and associated other fractures. Because no single approach can guarantee the best surgical outcomes, customized surgical techniques are required. Surgeons must stay updated on current developments in the management of OVF and be open to new treatment options.²⁶

Preventive measures OVF could be prevented or reduced if the risk factors in an individual are identified, and appropriate preventive measures are timely instituted. The recommendations are diet rich in calcium, phosphorus, protein and vitamin D3. Physical activity strengthening the muscles, bones and ligaments, correcting postures and preventing bony erosion also help. All postmenopausal women older than 50 years of age are recommended to have supplementation of Calcium (1000 mg) and Vit D3 (800IU/L).^{77,78} Regular screening using BMD in women of any age, especially those with a major risk factor is advised¹⁵⁴. Measuring the skeletal muscle area preoperatively using an axial computed tomography of the lumbar spine might help to prevent implant-related complications via early detection and treatment of sarcopenia.¹⁵⁵

Conclusion

Osteoporotic vertebral fractures are sadly on the rise and may soon pose a threat to public health. Identification of risk factors and timely institution of the preventive measures may reduce the incidence of OVF. Pain relief is the main focus in treatment along with treatment of progressive deformity and neurological deficits. Non-operative management remains the main stay of treatment for most of the osteoporotic spine fractures. Minimal invasive augmentation procedure is being increasingly used in appropriate patients who failed the conservative approach. Surgery is effective in very selective patients with modification of the techniques and devices. The challenges are old age, associated co-morbidities and quality of bones. The institution of preventive measures, early detection of OVF and wise selection of the appropriate form of management can assure reduction of osteoporosis related morbidity and mortality.

References

1. Edmond SL, Felson DT. Prevalence of back symptoms in elders. *J Rheumatol*. 2000 Jan;27(1):220-5. PMID: 10648042.
2. Guyatt GH, Townsend M, Berman LB, Keller JL. A comparison of Likert and visual analogue scales for measuring change in function. *J Chronic Dis*.

- 1987;40(12):1129-33. doi: 10.1016/0021-9681(87)90080-4. PMID: 3680471.
3. Fairbank JC, Couper J, Davies JB, O'Brien JP. The Oswestry low back pain disability questionnaire. *Physiotherapy*. 1980 Aug;66(8):271-3. PMID: 6450426.
 4. Fairbank JC, Pynsent PB. The Oswestry Disability Index. *Spine (Phila Pa 1976)*. 2000 Nov 15;25(22):2940-52; discussion 2952. doi: 10.1097/00007632-200011150-00017. PMID: 11074683.
 5. Frankel HL, Hancock DO, Hyslop G, Melzak J, Michaelis LS, Ungar GH, Vernon JD, Walsh JJ. The value of postural reduction in the initial management of closed injuries of the spine with paraplegia and tetraplegia. I. *Paraplegia*. 1969 Nov;7(3):179-92. doi: 10.1038/sc.1969.30. PMID: 5360915.
 6. Sugita, M., Watanabe, N., Mikami, Y., Hase, H., & Kubo, T. Classification of Vertebral Compression Fractures in the Osteoporotic Spine. *Journal of Spinal Disorders & Techniques*. 2005;18(4):376-381. doi:10.1097/01.bsd.0000168716.23440.61
 7. Kessenich CR. The pathophysiology of osteoporotic vertebral fractures. *Rehabil Nurs*. 1997 Jul-Aug;22(4):192-5. doi: 10.1002/j.2048-7940.1997.tb02098.x. PMID: 9275810.
 8. Jackson, S. A., Tenenhouse, A., & Robertson, L. Vertebral Fracture Definition from Population-Based Data: Preliminary Results from the Canadian Multicenter Osteoporosis Study (CaMos). *Osteoporosis International*. 2000;11(8):680-687. doi:10.1007/s001980070066
 9. Diacinti, D., & Guglielmi, G. How to define an osteoporotic vertebral fracture? *Quantitative Imaging in Medicine and Surgery*. 2019;9(9):1485-1494. doi:10.21037/qims.2019.09.10
 10. Wáng YXJ, Leung JCS, Lam PMS, Kwok TCY. Weak correlation between osteoporotic-like vertebral fracture severity and densitometric T-scores in older Chinese men. *Ann Transl Med*. 2023 Aug 30;11(10):374. doi: 10.21037/atm-23-639.
 11. Kanis, J. A., & Kanis, J. A. Assessment of fracture risk and its application to screening for postmenopausal osteoporosis: Synopsis of a WHO report. *Osteoporosis International*. 1994;4(6):368-381. doi:10.1007/bf01622200
 12. Wáng YXJ, Che-Nordin N, Leung JCS, Man Yu BW, Griffith JF, Kwok TCY. Elderly men have much lower vertebral fracture risk than elderly women even at advanced age: the MrOS and MsOS (Hong Kong) year 14 follow-up radiology results. *Arch Osteoporos*. 2020 Nov 7;15(1):176. doi: 10.1007/s11657-020-00845-x. PMID: 33159570
 13. Crans, G. G., Silverman, S. L., Genant, H. K., Glass, E. V., & Krege, J. H. Association of severe vertebral fractures with reduced quality of life: Reduction in the incidence of severe vertebral fractures by teriparatide. *Arthritis & Rheumatism*. 2004;50(12):4028-4034. doi:10.1002/art.20671
 14. Consensus development conference: Diagnosis, prophylaxis, and treatment of osteoporosis. *The American Journal of Medicine*. 1993;94(6):646-650. doi:10.1016/0002-9343(93)90218-e
 15. Center JR, Nguyen TV, Schneider D, Sambrook PN, Eisman JA. Mortality after all major types of osteoporotic fracture in men and women: an observational study. *Lancet*. 1999 Mar 13;353(9156):878-82. doi: 10.1016/S0140-6736(98)09075-8. PMID: 10093980.
 16. NIH Consensus Development Panel on Osteoporosis Prevention, Diagnosis, and Therapy. *Osteoporosis Prevention, Diagnosis, and Therapy*. *JAMA: The Journal of the American Medical Association*. 2001;285(6):785-795. doi:10.1001/jama.285.6.785
 17. Sozen, T, Ozisik, L., & Calik Basaran, N. An overview and management of osteoporosis. *European Journal of Rheumatology*. 2017;4(1):46-56. doi:10.5152/eurjrheum.2016.048
 18. Singer, A., Exuzides, A., Spangler, L., O'Malley, C., Colby, C., Johnston, K., Kagan, R. Burden of Illness for Osteoporotic Fractures Compared With Other Serious Diseases Among Postmenopausal Women in the United States. *Mayo Clinic Proceedings*. 2015; 90(1):53-62. doi:10.1016/j.mayocp.2014.09.011
 19. Clynes MA, Harvey NC, Curtis EM, Fuggle NR, Dennison EM, Cooper C. The epidemiology of osteoporosis. *Br Med Bull*. 2020 May 15;133(1):105-117. doi: 10.1093/bmb/ldaa005. PMID: 32282039.
 20. Skjødt MK, Abrahamsen B. New Insights in the Pathophysiology, Epidemiology, and Response to Treatment of Osteoporotic Vertebral Fractures. *J Clin Endocrinol Metab*. 2023 Oct 18;108(11):e1175-e1185. doi: 10.1210/clinem/dgad256. PMID: 37186550. Ji MX, Yu Q. Primary osteoporosis in postmenopausal women. *Chronic Dis Transl Med*. 2015 Mar 21;1(1):9-13. doi: 10.1016/j.cdtm.2015.02.006. PMID: 29062981; PMCID: PMC5643776.
 21. Ji MX, Yu Q. Primary osteoporosis in postmenopausal women. *Chronic Dis Transl Med*. 2015 Mar 21;1(1):9-13. doi: 10.1016/j.cdtm.2015.02.006. PMID: 29062981; PMCID: PMC5643776.
 22. Fitzpatrick, L. A. Secondary Causes of Osteoporosis. *Mayo Clinic Proceedings*. 2002;77(5):453-468. doi:10.4065/77.5.453
 23. Ganesan K, Jandu JS, Anastasopoulou C, Ahsun S, Roane D. Secondary Osteoporosis. 2023 Mar 2. In: *StatPearls [Internet]*. Treasure Island (FL): StatPearls Publishing; 2024 Jan. PMID: 29262237.
 24. Cahir JG, Toms AP. Regional migratory osteoporosis. *Eur J Radiol*. 2008 Jul;67(1):2-10. doi: 10.1016/j.ejrad.2008.01.051.
 25. Warriner AH, Patkar NM, Curtis JR, Delzell E, Gary L, Kilgore M, Saag K. Which fractures are most attributable to osteoporosis? *J Clin Epidemiol*. 2011 Jan;64(1):46-53. doi: 10.1016/j.jclinepi.2010.07.007. PMID: 21130353; PMCID: PMC5030717.
 26. Jang, HD , Hae-Dong , Kim, Eung-Ha , Lee, Jae Chul , Sung-Woo Choi, Hak Soo Kim, Joong-Suk Cha, and Byung-Joon Shin · Management of Osteoporotic Vertebral Fracture: Review Update 2022. *Asian Spine J*. 2022 Dec; 16(6): 934-946. doi: 10.31616/asj.2022.0441
 27. Brown JP, Josse RG; Scientific Advisory Council of the Osteoporosis Society of Canada. 2002 clinical practice guidelines for the diagnosis and management of osteoporosis in Canada. *CMAJ*. 2002 Nov 12;167(10 Suppl):S1-34. Erratum in: *CMAJ*. 2003 Feb 18;168(4):400. Erratum in: *CMAJ*. 2003 Mar

- 18;168(6):676. Erratum in: CMAJ. 2003 Mar 4;168(5):544. PMID: 12427685; PMCID: PMC134653.
28. Himič V, Syrmos N, Ligarotti GKI, Kato S, Fehlings MG, Ganau M. The role of genetic and epigenetic factors in determining the risk of spinal fragility fractures: new insights in the management of spinal osteoporosis. *Quant Imaging Med Surg.* 2023 Nov 1;13(11):7632-7645. doi: 10.21037/qims-23-513.
 29. Kado DM, Browner WS, Palermo L, Nevitt MC, Genant HK, Cummings SR. Vertebral fractures and mortality in older women: a prospective study. Study of Osteoporotic Fractures Research Group. *Arch Intern Med* 1999;159:1215-20.
 30. Cieza, A., Schwarzkopf, S., Sigl, T., Stucki, G., Melvin, J., Stoll, T., Walsh, N. ICF Core Sets for osteoporosis. *Journal of Rehabilitation Medicine.* 2004;36(0):81–86. doi:10.1080/16501960410016028
 31. Shen M, Kim Y. Osteoporotic vertebral compression fractures: a review of current surgical management techniques. *Am J Orthop (Belle Mead NJ).* 2007 May;36(5):241-8. PMID: 17571828.
 32. Jung HJ, Park YS, Seo HY, Lee JC, An KC, Kim JH, Shin BJ, Kang TW, Park SY. Quality of Life in Patients with Osteoporotic Vertebral Compression Fractures. *J Bone Metab.* 2017 Aug;24(3):187-196. doi: 10.11005/jbm.2017.24.3.187. Epub 2017 Aug 31. PMID: 28955695; PMCID: PMC5613024.
 33. Park JH, Lee SM, Shim SW, Baek SN, Choi YS. The Influence of Restrictive Pulmonary Dysfunction on Osteoporotic Thoracic Vertebral Fractures. *Asian Spine J.* 2021 Oct;15(5):659-663. doi: 10.31616/asj.2020.0082. Epub 2020 Oct 19. PMID: 33059437; PMCID: PMC8561149.
 34. Lyrītis, G. P., Mayasis, B., Tsakalagos, N., Lambropoulos, A., Gazi, S., Karachalios, T., ... Yiatzides, A. (1989). The natural history of the osteoporotic vertebral fracture. *Clinical Rheumatology*, 8(S2), 66–69. doi:10.1007/bf02207237
 35. López Zúñiga, D., Láinez-Ramos-Bossini, A. J., & Ruiz Santiago, F. Radiographic diagnosis of osteoporotic vertebral fractures. An updated review. *Medicina Clínica (English Edition).* 2021;158(3):125-132. doi:10.1016/j.medcli.2021.06.019
 36. Yì Xiáng J. Wáng. An update of our understanding of radiographic diagnostics for prevalent osteoporotic vertebral fracture in elderly women. *Quant Imaging Med Surg* 2022;12(7):3495-3514. .doi.org/10.21037/qims-22-360
 37. Wáng YXJ. Osteoporotic Vertebral Deformity: Radiological Appearances and Their Association With a History of Trauma and the Risk of Further Fragility Fracture. *Can Assoc Radiol J.* 2021 Aug;72(3):585. doi: 10.1177/0846537120958471.
 38. Delmas, P. D., van de Langerijt, L., Watts, N. B., Eastell, R., Genant, H., Grauer, A., & Cahall, D. L. Underdiagnosis of Vertebral Fractures Is a Worldwide Problem: The IMPACT Study. *Journal of Bone and Mineral Research.* 2004;20(4):557–563. doi:10.1359/jbmr.041214
 39. Diacinti, D., Vitali, C., Gussoni, G., Pisani, D., Sinigaglia, L., Bianchi, G., Albanese, C. V. Misdiagnosis of vertebral fractures on local radiographic readings of the multicentre POINT (Prevalence of Osteoporosis in INTERNAL medicine) study. *Bone.* 2017;101:230–235. doi:10.1016/j.bone.2017.05.008
 40. Yu W, W-M Guan, D Hayashi, Q Lin, M-M Du, W-B Xia, Y-X J Wang, A Guermazi. Vertebral fracture severity assessment on anteroposterior radiographs with a new semi-quantitative technique. *Osteoporos Int.* 2024 Jan 31. doi: 10.1007/s00198-024-07024-5.
 41. Genant HK, Wu CY, van Kuijk C, Nevitt MC. Vertebral fracture assessment using a semiquantitative technique. *J Bone Miner Res.* 1993 Sep;8(9):1137-48. doi: 10.1002/jbmr.5650080915. PMID: 8237484.
 42. Graffy PM, Lee SJ, Ziemlewicz TJ, Pickhardt PJ. Prevalence of Vertebral Compression Fractures on Routine CT Scans According to L1 Trabecular Attenuation: Determining Relevant Thresholds for Opportunistic Osteoporosis Screening. *AJR Am J Roentgenol.* 2017 Sep;209(3):491-496. doi: 10.2214/AJR.17.17853. Epub 2017 Jun 22. PMID: 28639828.
 43. Löffler MT, Kallweit M, Niederreiter E, Baum T, Makowski MR, Zimmer C, Kirschke JS. Epidemiology and reporting of osteoporotic vertebral fractures in patients with long-term hospital records based on routine clinical CT imaging. *Osteoporos Int.* 2022 Mar;33(3):685-694. doi: 10.1007/s00198-021-06169-x. Epub 2021 Oct 14. PMID: 34648040; PMCID: PMC8844161.
 44. Valentinitsch A, Trebeschi S, Kaesmacher J, Lorenz C, Löffler MT, Zimmer C, Baum T, Kirschke JS. Opportunistic osteoporosis screening in multi-detector CT images via local classification of textures. *Osteoporos Int.* 2019 Jun;30(6):1275-1285. doi: 10.1007/s00198-019-04910-1. Epub 2019 Mar 4. PMID: 30830261; PMCID: PMC6546649.
 45. Lenchik L, Rogers LF, Delmas PD, Genant HK. Diagnosis of osteoporotic vertebral fractures: importance of recognition and description by radiologists. *AJR Am J Roentgenol.* 2004 Oct;183(4):949-58. doi: 10.2214/ajr.183.4.1830949. PMID: 15385286.
 46. Mauch JT, Carr CM, Cloft H, Diehn FE. Review of the Imaging Features of Benign Osteoporotic and Malignant Vertebral Compression Fractures. *AJNR Am J Neuroradiol.* 2018 Sep;39(9):1584-1592. doi: 10.3174/ajnr.A5528. Epub 2018 Jan 18. PMID: 29348133; PMCID: PMC7655272.
 47. Silberstein J, Wee C, Gupta A, Seymour H, Ghotra SS, Sá Dos Reis C, Zhang G, Sun Z.J Artificial Intelligence-Assisted Detection of Osteoporotic Vertebral Fractures on Lateral Chest Radiographs in Post-Menopausal Women. *Clin Med.* 2023 Dec 16;12(24):7730. doi: 10.3390/jcm12247730. PMID: 38137799
 48. Miller, P. D. The history of bone densitometry. *Bone.* 2017;104:4–6. doi:10.1016/j.bone.2017.06.002
 49. Kanis, J. A., McCloskey, E. V., Johansson, H., Oden, A., Melton, L. J., & Khaltayev, N. (2008). A reference standard for the description of osteoporosis. *Bone*, 42(3), 467–475. doi:10.1016/j.bone.2007.11.001
 50. Brincat, M., Calleja-Agius, J., Erel, C. T., Gambacciani, M., Lambrinoudaki, I., Moen, M. H., Rozenberg, S. EMAS position statement: Bone densitometry

- screening for osteoporosis. *Maturitas*. 2011;68(1):98–101. doi:10.1016/j.maturitas.2010.09.009
51. Nuti, R., Brandi, M. L., Checchia, G., Di Munno, O., Dominguez, L., Falaschi, P., ... Isaia, G. C. Guidelines for the management of osteoporosis and fragility fractures. *Internal and Emergency Medicine*. 2018; doi:10.1007/s11739-018-1874-2
 52. Cheng X, Yuan H, Cheng J, Weng X, Xu H, Gao J, Huang M, Wang YXJ, Wu Y, Xu W, Liu L, Liu H, Huang C, Jin Z, Tian W; Chinese expert consensus on the diagnosis of osteoporosis by imaging and bone mineral density. Chinese expert consensus on the diagnosis of osteoporosis by imaging and bone mineral density. *Quant Imaging Med Surg* 2020;10:2066-77. 10.21037/qims-2020-16
 53. Engelke K, Lang T, Khosla S, Qin L, Zysset P, Leslie WD, Shepherd JA, Schousboe JT. Clinical Use of Quantitative Computed Tomography (QCT) of the Hip in the Management of Osteoporosis in Adults: the 2015 ISCD Official Positions-Part I. *J Clin Densitom* 2015;18:338-58. 10.1016/j.jocd.2015.06.012
 54. Zhao Y, Zhao T, Chen S, Zhang X, Serrano Sosa M, Liu J, Mo X, Chen X, Huang M, Li S, Zhang X, Huang C. Fully automated radiomic screening pipeline for osteoporosis and abnormal bone density with a deep learning-based segmentation using a short lumbar mDixon sequence. *Quant Imaging Med Surg* 2022;12:1198-213. 10.21037/qims-21-587
 55. Dugonjić S, Ajdinović B, Ćirković M, Ristić G. Bone scintigraphy can diagnose osteoporotic vertebral compression fractures better than conventional radiography. *Hell J Nucl Med* 2017;20 Suppl:155.
 56. Greenblatt, M. B., Tsai, J. N., & Wein, M. N. Bone Turnover Markers in the Diagnosis and Monitoring of Metabolic Bone Disease. *Clinical Chemistry*. 2016;63(2):464–474. doi:10.1373/clinchem.2016.259085
 57. Looker, A. C., Bauer, D. C., Chesnut III, C. H., Gundberg, C. M., Hochberg, M. C., Klee, G., Bell, N. H. Clinical Use of Biochemical Markers of Bone Remodeling: Current Status and Future Directions. *Osteoporosis International*. 2000;11(6):467–480. doi:10.1007/s001980070088
 58. Romeo V, Ugga L, Stanzione A, Cocozza S, Cuocolo R, Brunetti A. Differential diagnosis of benign and malignant vertebral compression fractures using conventional and advanced MRI techniques. *BJR Open*. 2019 May 12;1(1):20180033. doi: 10.1259/bjro.20180033. PMID: 33178924; PMCID: PMC7592442.
 59. Yamamoto Y, Iwata E, Shigematsu H, Morita T, Tanaka M, Okuda A, Masuda K, Ikejiri M, Nakajima H, Koizumi M, Tanaka Y. Differential diagnosis between metastatic and osteoporotic vertebral fractures using sagittal T1-weighted magnetic resonance imaging. *J Orthop Sci*. 2020 Sep;25(5):763-769. doi: 10.1016/j.jos.2019.10.004. Epub 2019 Nov 23. PMID: 31771804.
 60. Lentle BC, Prior JC. Osteoporotic vertebral fracture (OVF): diagnosis requires an informed observer. *Osteoporos Int*. 2022 Jun;33(6):1409-1410. doi: 10.1007/s00198-021-06287-6. Epub 2022 Mar 30. PMID: 35352143.
 61. Esses SI, McGuire R, Jenkins J, et al. The treatment of symptomatic osteoporotic spinal compression fractures. *J Am Acad Orthop Surg* 2011;19:176-82. 10.5435/00124635-201103000-00007
 62. Parreira PCS, Maher CG, Megale RZ, March L, Ferreira ML. An overview of clinical guidelines for the management of vertebral compression fracture: a systematic review. *Spine J*. 2017 Dec;17(12):1932-1938. doi: 10.1016/j.spinee.2017.07.174. Epub 2017 Jul 21. PMID: 28739478.
 63. Sanchez-Rodriguez, D., Bergmann, P., Body, J. J., Cavalier, E., Gielen, E., Goemaere, S., Bruyère, O. The Belgian Bone Club 2020 guidelines for the management of osteoporosis in postmenopausal women. 2020 *Maturitas*. doi:10.1016/j.maturitas.2020.05.006
 64. Kim, D.H., A.R. Vaccaro. Osteoporotic compression fractures of the spine; current options and considerations for treatment. *Spine J*. 2006 Sep-Oct;6(5):479-87. doi: 10.1016/j.spinee.2006.04.013.
 65. Dai LY, Jiang LS, Jiang SD. Conservative treatment of thoracolumbar burst fractures: a long-term follow-up results with special reference to the load sharing classification. *Spine (Phila Pa 1976)* 2008;33:2536-44. 10.1097/BRS.0b013e3181851bc2
 66. Longo, U. G., Loppini, M., Denaro, L., Maffulli, N., & Denaro, V. Osteoporotic vertebral fractures: current concepts of conservative care. *British Medical Bulletin*. 2011;102(1):171–189. doi:10.1093/bmb/ldr048
 67. Silverman, S. The clinical consequences of vertebral compression fracture. *Bone*. 1992 13, Suppl 2: S27–S31. doi:10.1016/8756-3282(92)90193-z
 68. Ensrud, K. E., & Schousboe, J. T. Vertebral Fractures. *New England Journal of Medicine*. 2011;364(17):1634–1642. doi:10.1056/nejmcp1009697
 69. Dodwell ER, Latorre JG, Parisini E, Zwettler E, Chandra D, Mulpuri K, Snyder B. NSAID exposure and risk of nonunion: a meta-analysis of case-control and cohort studies. *Calcif Tissue Int*. 2010 Sep;87(3):193-202. doi: 10.1007/s00223-010-9379-7. Epub 2010 Jun 15. PMID: 20552333.
 70. Cherasse A, Muller G, Ornetti P, Piroth C, Tavernier C, Mailefert JF. Tolerability of opioids in patients with acute pain due to nonmalignant musculoskeletal disease. A hospital-based observational study. *Joint Bone Spine*. 2004 Nov;71(6):572-6. doi: 10.1016/j.jbspin.2003.10.014. PMID: 15589442.
 71. Nevitt MC, Chen P, Dore RK, Reginster JY, Kiel DP, Zanchetta JR, Glass EV, Krege JH. Reduced risk of back pain following teriparatide treatment: a meta-analysis. *Osteoporos Int*. 2006 Feb;17(2):273-80. doi: 10.1007/s00198-005-2013-2. Epub 2005 Sep 2. PMID: 16142502.
 72. Pappagallo M, Breuer B, Lin HM, et al. A pilot trial of intravenous pamidronate for chronic low back pain. *Pain*. 2014 Jan;155(1):108-117. doi: 10.1016/j.pain.2013.09.016.
 73. Inoue G, Ueno M, Nakazawa T, Imura T, Saito W, Uchida K, Ohtori S, Toyone T, Takahira N, Takaso M. Teriparatide increases the insertional torque of pedicle screws during fusion surgery in patients with postmenopausal osteoporosis. *J Neurosurg Spine*. 2014

- Sep;21(3):425-31. doi: 10.3171/2014.5.SPINE13656. Epub 2014 Jun 6. PMID: 24905394.
74. Silva BC, Hipólito Rodrigues MA. Estrogen hormone therapy and postmenopausal osteoporosis: does it really take two to tango? *Women Health*. 2023 Nov 26;63(10):770-773. doi: 10.1080/03630242.2023.2278211. Epub 2023 Nov 17. PMID: 37975286.
 75. Kroupova K, Palicka V, Rosa J. Monoclonal antibodies for treatment of osteoporosis. *Drugs Today (Barc)*. 2023 Mar;59(3):195-204. doi: 10.1358/dot.2023.59.3.3453905. PMID: 36847627.
 76. Knopp-Sihota, J. A., Newburn-Cook, C. V., Homik, J., Cummings, G. G., & Voaklander, D. Calcitonin for treating acute and chronic pain of recent and remote osteoporotic vertebral compression fractures: a systematic review and meta-analysis. *Osteoporosis International*. 2011;23(1):17–38. doi:10.1007/s00198-011-1676-0
 77. Sunycz JA. The use of calcium and vitamin D in the management of osteoporosis. *The Clin Risk Manag*. 2008 Aug;4(4):827-36. doi: 10.2147/tcrm.s3552. PMID: 19209265; PMCID: PMC2621390.
 78. Hanley DA, Cranney A, Jones G, Whiting SJ, Leslie WD; Guidelines Committee of the Scientific Advisory Council of Osteoporosis Canada. Vitamin D in adult health and disease: a review and guideline statement from Osteoporosis Canada (summary). *CMAJ*. 2010 Sep 7;182(12):1315-9. doi: 10.1503/cmaj.091062. Epub 2010 Jul 12. PMID: 20624865; PMCID: PMC2934797.
 79. Voulgaridou G, Papadopoulou SK, Detopoulou P, Tsoumana D, Giaginis C, Kondyli FS, Lymperaki E, Pritsa A. Vitamin D and Calcium in Osteoporosis, and the Role of Bone Turnover Markers: A Narrative Review of Recent Data from RCTs. *Diseases*. 2023 Feb 8;11(1):29. doi: 10.3390/diseases11010029. PMID: 36810543; PMCID: PMC9944083.
 80. de Filippis R, Mercurio M, Spina G, De Fazio P, Segura-Garcia C, Familiari F, Gasparini G, Galasso O. Antidepressants and Vertebral and Hip Risk Fracture: An Updated Systematic Review and Meta-Analysis. *Healthcare (Basel)*. 2022 Apr 26;10(5):803. doi: 10.3390/healthcare10050803. PMID: 35627940; PMCID: PMC9140335.
 81. Cho ST, Kim SJ, Nam BJ, Kim KW, Lee GH, Kim JH. Absolute Bed Rest Duration of 3 Days for Osteoporotic Vertebral Fractures: A Retrospective Study. *Asian Spine J*. 2022 Dec;16(6):898-905. doi: 10.31616/asj.2021.0396. Epub 2022 May 10. PMID: 35527538; PMCID: PMC9827199
 82. Han S, Jang HD, Choi S, et al. Changes in physical activity and risk of fracture: a Korean nationwide population-based cohort study. *Sci Rep*. 2020 Oct 1;10(1):16266. doi: 10.1038/s41598-020-73495-1.
 83. Francis, R. M., Aspray, T. J., Hide, G., Sutcliffe, A. M., & Wilkinson, P. (2007). Back pain in osteoporotic vertebral fractures. *Osteoporosis International*, 19(7), 895–903. doi:10.1007/s00198-007-0530-x
 84. Giangregorio, L. M., MacIntyre, N. J., Thabane, L., Skidmore, C. J., & Papaioannou, A. Exercise for improving outcomes after osteoporotic vertebral fracture. *Cochrane Database of Systematic Reviews*. 2013 doi:10.1002/14651858.cd008618.pub2
 85. Falossi F, Azzollini V, Notarstefano C, Raffaeta G. Adherence to a home physical exercise program in patients with osteoporotic vertebral fractures: a retrospective observational study. *J Back Musculoskelet Rehabil*. 2022;35(4):777-782. doi: 10.3233/BMR-191826.
 86. Rajasekaran S, Kanna RM, Schnake KJ, et al. Osteoporotic thoracolumbar fractures-how are they different?: classification and treatment algorithm. *J Orthop Trauma*. 2017 Sep;31 Suppl 4:S49-S56. doi: 10.1097/BOT.0000000000000949.
 87. Ebeling PR, Akesson K, Bauer DC, et al. The efficacy and safety of vertebral augmentation: a second AS-BMR Task Force report. *J Bone Miner Res*. 2019 Jan;34(1):3-21. doi: 10.1002/jbmr.3653.
 88. Pfeifer, M., Begerow, B., & Minne, H. W. Effects of a New Spinal Orthosis on Posture, Trunk Strength, and Quality of Life in Women with Postmenopausal Osteoporosis. *American Journal of Physical Medicine & Rehabilitation*. 2004;83(3):177–186. doi:10.1097/01.phm.0000113403.16617.93
 89. Chang V, Holly LT. Bracing for thoracolumbar fractures. *Neurosurg Focus* 2014;37:E3. doi: 10.3171/2014.4.FOCUS1477.
 90. Genev IK, Tobin MK, Zaidi SP, Khan SR, Amirouche FM, Mehta AI. Spinal compression fracture management: a review of current treatment strategies and possible future avenues. *Global Spine J*. 2017 Feb;7(1):71-82. doi: 10.1055/s-0036-1583288.
 91. Kweh BT, Lee HQ, Tan T, et al. The role of spinal orthoses in osteoporotic vertebral fractures of the elderly population (age 60 years or older): systematic review. *Global Spine J* 2021;11:975-87. doi:10.1177/2192568220948036
 92. Furrer PR, Hodel S, Wanivenhaus F, Grubhofer F, Farshad M. Compliance with wearing a thoracolumbar orthosis in nonoperative treatment of osteoporotic vertebral fractures: a prospective sensor-controlled study. *Spine J*. 2023 Mar;23(3):433-439. doi: 10.1016/j.spinee.2022.11.009.
 93. Cieza, A., Schwarzkopf, S., Sigl, T., Stucki, G., Melvin, J., Stoll, T., Walsh, N. ICF Core Sets for osteoporosis. *Journal of Rehabilitation Medicine*. 2004;36(0):81–86. doi:10.1080/16501960410016028
 94. Marchenkova LA, Makarova EV, Eryomushkin MA, Fesun AD, Styazkina EM, Chesnikova EI. Efficiency of back muscles training and balance therapy in rehabilitation of patients with osteoporotic vertebral fractures. *Eur J Transl Myol*. 2021 Oct 19;31(4):9945. doi: 10.4081/ejtm.2021.9945.
 95. Makarova EV, Marchenkova LA, Eryomushkin MA, Styazkina EM, Chesnikova EI. Balance and muscle strength tests in patients with osteoporotic vertebral fractures to develop tailored rehabilitation programs. *Eur J Transl Myol*. 2020 Sep 9;30(3):9236. doi: 10.4081/ejtm.2020.9236.
 96. Tsujio, T., Nakamura, H., Terai, H., Hoshino, M., Namikawa, T., Matsumura, A., ... Takaoka, K. (2011). Characteristic Radiographic or Magnetic Resonance Images of Fresh Osteoporotic Vertebral Fractures Predicting Potential Risk for Nonunion. *Spine*, 36(15), 1229–1235. doi:10.1097/brs.0b013e3181f29e8d

97. Venmans, A., Lohle, P. N. M., & van Rooij, W. J. Pain course in conservatively treated patients with back pain and a VCF on the spine radiograph (VERTOS III). *Skeletal Radiology*. 2013;43(1):13–18. doi:10.1007/s00256-013-1729-x
98. Lad, S. P., Patil, C. G., Lad, E. M., Hayden, M. G., & Boakye, M. National trends in vertebral augmentation procedures for the treatment of vertebral compression fractures. *Surgical Neurology*. 2009;71(5):580–584. doi:10.1016/j.surneu.2008.02.043
99. Marco RA, Meyer BC, Kushwaha VP. Thoracolumbar burst fractures treated with posterior decompression and pedicle screw instrumentation supplemented with balloon-assisted vertebroplasty and calcium phosphate reconstruction. *Surgical technique. J Bone Joint Surg Am*. 2010 Mar;92 Suppl 1 Pt 1:67-76. doi: 10.2106/JBJS.I.01236. PMID: 20194345.
100. Hartensuer R, Gehweiler D, Schulze M, Matuszewski L, Raschke MJ, Vordemvenne T. Biomechanical evaluation of combined short segment fixation and augmentation of incomplete osteoporotic burst fractures. *BMC Musculoskelet Disord*. 2013 Dec 21;14:360. doi: 10.1186/1471-2474-14-360.
101. Chou KN, Wang PW, Chung MH, Ju DT. Hybrid kyphoplasty with short-versus intermediate- and long-segment pedicle screw fixations for the management of thoracolumbar burst fractures. *BMC Musculoskelet Disord*. 2024 Mar 7;25(1):203. doi: 10.1186/s12891-024-07320-5. PMID: 38454411; PMCID: PMC10919052.
102. Kallmes DF, Comstock BA, Heagerty PJ, et al. A randomized trial of vertebroplasty for osteoporotic spinal fractures. *N Engl J Med* 2009;361:569-79.
103. Wardlaw D, Cummings SR, Van Meirhaeghe J, et al. Efficacy and safety of balloon kyphoplasty compared with non-surgical care for vertebral compression fracture (FREE): a randomised controlled trial. *Lancet* 2009;373:1016-24.
104. Klazen CA, Lohle PN, de Vries J, et al. Vertebroplasty versus conservative treatment in acute osteoporotic vertebral compression fractures (Vertos II): an open-label randomised trial. *Lancet* 2010;376:1085-92.
105. Phillips FM, Pfeifer BA, Lieberman IH, Kerr EJ 3rd, Choi IS, Pazziano AG. Minimally invasive treatments of osteoporotic vertebral compression fractures: vertebroplasty and kyphoplasty. *Instr Course Lect*. 2003;52:559-67. PMID: 12690882
106. Denaro V, Longo UG, Maffulli N, Denaro L. Vertebroplasty and kyphoplasty. *Clin Cases Miner Bone Metab*. 2009 May;6(2):125-30. PMID: 22461161; PMCID: PMC2781232.
107. Yokoyama, K., Kawanishi, M., Yamada, M., Tanaka, H., Ito, Y., Kawabata, S., & Kuroiwa, T. Postoperative change in sagittal balance after Kyphoplasty for the treatment of osteoporotic vertebral compression fracture. *European Spine Journal*. 2014;24(4):744–749. doi:10.1007/s00586-014-3678-z
108. Fribourg, D., Tang, C., Sra, P., Delamarter, R., & Bae, H. Incidence of Subsequent Vertebral Fracture after Kyphoplasty. *Spine*. 2004;29(20):2270–2276. doi:10.1097/01.brs.0000142469.41565.2a
109. Chen, A. T., Cohen, D. B., & Skolasky, R. L. Impact of Nonoperative Treatment, Vertebroplasty, and Kyphoplasty on Survival and Morbidity After Vertebral Compression Fracture in the Medicare Population. *The Journal of Bone and Joint Surgery-American*. 2013;95(19):1729–1736. doi:10.2106/jbjs.k.01649
110. Farrokhi MR, Alibai E, Maghami Z. Randomized controlled trial of percutaneous vertebroplasty versus optimal medical management for the relief of pain and disability in acute osteoporotic vertebral compression fractures. *J Neurosurg Spine*. 2011 May;14(5):561-9. doi: 10.3171/2010.12.SPINE10286.
111. Buchbinder R, Osborne RH, Ebeling PR, Wark JD, Mitchell P, Wriedt C, Graves S, Staples MP, Murphy B. A randomized trial of vertebroplasty for painful osteoporotic vertebral fractures. *N Engl J Med*. 2009 Aug 6;361(6):557-68. doi: 10.1056/NEJMoa0900429. PMID: 19657121.
112. Abdelrahman T, Smith M, Opara TN, Ahmed A, Kotrba M. Functional Outcome of Kyphoplasty in Osteoporotic Vertebral Fractures in Patients with Severe Disability Above 60 Years of Age: Mid to Long Term Follow up. *Ortop Traumatol Rehabil*. 2021 Feb 28;23(1):1-7. doi: 10.5604/01.3001.0014.7561. PMID: 33709949.
113. Pron G, Hwang M, Smith R, Cheung A, Murphy K. Cost-effectiveness studies of vertebral augmentation for osteoporotic vertebral fractures: a systematic review. *Spine J*. 2022 Aug;22(8):1356-1371. doi: 10.1016/j.spinee.2022.02.013. Epub 2022 Mar 5. PMID: 35257838.
114. Lemke, D. M. Vertebroplasty and Kyphoplasty for Treatment of Painful Osteoporotic Compression Fractures. *Journal of the American Academy of Nurse Practitioners* 2005;17(7):268–276. doi:10.1111/j.1745-7599.2005.0045.x
115. Zarate, B., Gutierrez, J., Wakhloo, A. K., Gounis, M. J., & Reyes-Sánchez, A. Clinical Evaluation of a New Kyphoplasty Technique With Directed Cement Flow. *Journal of Spinal Disorders & Techniques*. 2012;25(3):E61–E66. doi:10.1097/bsd.0b013e31824a7e2c
116. Tolba, R., Bolash, R. B., Shroll, J., Costandi, S., Dalton, J. E., Sanghvi, C., & Mekhail, N. Kyphoplasty Increases Vertebral Height, Decreases Both Pain Score and Opiate Requirements While Improving Functional Status. *Pain Practice*. 2013;14(3):E91 E97. doi:10.1111/papr.12131
117. Wang, G. Y., Zhang, C. C., Ren, K., Zhang, P. P., Liu, C. H., Zheng, Z. A., ... Fang, R. Treatment of vertebral body compression fractures using percutaneous kyphoplasty guided by a combination of computed tomography and C-arm fluoroscopy with finger-touch guidance to determine the needle entry point. *Genetics and Molecular Research*. 2015;14(1):1546–1556. doi:10.4238/2015.march.6.2
118. Chen Z, Song C, Chen J, Sun J, Liu W. Can facet joint block be a complementary or alternative therapeutic option for patients with osteoporotic vertebral fractures: a meta-analysis. *J Orthop Surg Res*. 2022 Jan 21;17(1):40. doi: 10.1186/s13018-022-02933-9. PMID: 35063004; PMCID: PMC8781236.
119. Taylor RS, Taylor RJ, Fritzell P. Balloon kyphoplasty and vertebroplasty for vertebral compression fractures: a comparative systematic review of efficacy and safety. *Spine (Phila Pa 1976)*. 2006 Nov 1;31(23):2747-55. doi: 10.1097/01.brs.0000244639.71656.7d.

120. Al-Nakshabandi, N. Percutaneous vertebroplasty complications. *Annals of Saudi Medicine*. 2011;31(3):294. doi:10.4103/0256-4947.81542
121. Lee KA, Hong SJ, Lee S, Cha IH, Kim BH, Kang EY. Analysis of adjacent fracture after percutaneous vertebroplasty: does intradiscal cement leakage really increase the risk of adjacent vertebral fracture? *Skeletal Radiol*. 2011 Dec;40(12):1537-42. doi: 10.1007/s00256-011-1139-x
122. Li YA, Lin CL, Chang MC, Liu CL, Chen TH, Lai SC. Subsequent vertebral fracture after vertebroplasty: incidence and analysis of risk factors. *Spine (Phila Pa 1976)*. 2012 Feb 1;37(3):179-83. doi: 10.1097/BRS.0b013e3181f72b05.
123. Yu W, Xu W, Jiang X, Liang D, Jian W. Risk Factors for Recollapse of the Augmented Vertebrae After Percutaneous Vertebral Augmentation: A Systematic Review and Meta-Analysis. *World Neurosurg*. 2018 Mar;111:119-129. doi: 10.1016/j.wneu.2017.12.019. Epub 2017 Dec 15. PMID: 29253703.
124. Lavelle WF, Cheney R. Recurrent fracture after vertebral kyphoplasty. *Spine J*. 2006 Sep-Oct;6(5):488-93. doi: 10.1016/j.spinee.2005.10.013. PMID: 16934716.
125. Trout AT, Kallmes DF, Kaufmann TJ. New fractures after vertebroplasty: adjacent fractures occur significantly sooner. *AJNR Am J Neuroradiol*. 2006 Jan;27(1):217-23. PMID: 16418388; PMCID: PMC7976057.
126. Bouza C, López T, Magro A, Navalpotro L, Amate JM. Efficacy and safety of balloon kyphoplasty in the treatment of vertebral compression fractures: a systematic review. *Eur Spine J*. 2006 Jul;15(7):1050-67. doi: 10.1007/s00586-005-0048-x. Epub 2006 Jan 21. PMID: 16429288; PMCID: PMC3233932.
127. Nakamae T, Fujimoto Y, Yamada K, Hiramatsu T, Hashimoto T, Olmarker K, Adachi N. Relationship between clinical symptoms of osteoporotic vertebral fracture with intravertebral cleft and radiographic findings. *J Orthop Sci*. 2017 Mar;22(2):201-206. doi: 10.1016/j.jos.2016.12.002. Epub 2017 Jan 9. PMID: 28081928.
128. Radswiki T, Duarte C, Worsley C, et al. Kümmell disease. Reference article, Radiopaedia.org (Accessed on 05 Apr 2024) <https://doi.org/10.53347/rID-12147>
129. Barr JD, Jensen ME, Hirsch JA, McGraw JK, Barr RM, Brook AL, Meyers PM, Munk PL, Murphy KJ, O'Toole JE, Rasmussen PA, Ryken TC, Sanelli PC, Schwartzberg MS, Seidenwurm D, Tutton SM, Zoarski GH, Kuo MD, Rose SC, Cardella JF; Society of Interventional Radiology; American Association of Neurological Surgeons; Congress of Neurological Surgeons; American College of Radiology; American Society of Neuroradiology; American Society of Spine Radiology; Canadian Interventional Radiology Association; Society of Neurointerventional Surgery. Position statement on percutaneous vertebral augmentation: a consensus statement developed by the Society of Interventional Radiology (SIR), American Association of Neurological Surgeons (AANS) and the Congress of Neurological Surgeons (CNS), American College of Radiology (ACR), American Society of Neuroradiology (ASNR), American Society of Spine Radiology (ASSR), Canadian Interventional Radiology Association (CIRA), and the Society of NeuroInterventional Surgery (SNIS). *J Vasc Interv Radiol*. 2014 Feb;25(2):171-81. doi: 10.1016/j.jvir.2013.10.001. Epub 2013 Dec 8. PMID: 24325929.
130. Colangelo D, Nasto LA, Genitiempo M, Formica VM, Autore G, Pambianco V, Tamburrelli FC, Cerulli G, Pola E. Kyphoplasty vs conservative treatment: a case-control study in 110 post-menopausal women population. Is kyphoplasty better than conservative treatment? *Eur Rev Med Pharmacol Sci*. 2015 Nov;19(21):3998-4003. PMID: 26592820.
131. Shimizu T, Fujibayashi S, Masuda S, et al. Clinical features and surgical outcomes of lower lumbar osteoporotic vertebral collapse with symptomatic stenosis: a surgical strategy from a multicenter case series. *Asian Spine J* 2022 May 10 [Epub]. <https://doi.org/10.31616/asj.2021.0421>
132. Hosogane N, Nojiri K, Suzuki S, Funao H, Okada E, Isogai N, Ueda S, Hikata T, Shiono Y, Watanabe K, Watanabe K, Kaito T, Yamashita T, Fujiwara H, Nagamoto Y, Terai H, Tamai K, Matsuoka Y, Suzuki H, Nishimura H, Tagami A, Yamada S, Adachi S, Ohtori S, Orita S, Furuya T, Yoshii T, Ushio S, Inoue G, Miyagi M, Saito W, Imagama S, Ando K, Sakai D, Nukaga T, Kiyasu K, Kimura A, Inoue H, Nakano A, Harimaya K, Kawaguchi K, Yokoyama N, Oishi H, Doi T, Ikegami S, Shimizu M, Futatsugi T, Kakutani K, Yurube T, Oshima M, Uei H, Aoki Y, Takahata M, Iwata A, Seki S, Murakami H, Yoshioka K, Endo H, Hongo M, Nakanishi K, Abe T, Tsukanishi T, Ishii K. Surgical Treatment of Osteoporotic Vertebral Fracture with Neurological Deficit-A Nationwide Multicenter Study in Japan. *Spine Surg Relat Res*. 2019 Mar 22;3(4):361-367. doi: 10.22603/ssrr.2019-0004. PMID: 31768457; PMCID: PMC6834469.
133. Nakashima H, Yukawa Y, Ito K, Machino M, Ishiguro N, Kato F. Combined posterior-anterior surgery for osteoporotic delayed vertebral fracture with neurologic deficit. *Nagoya J Med Sci*. 2014 Aug;76(3-4):307-14. PMID: 25741039; PMCID: PMC4345685.
134. Jang HD, Kim EH, Lee JC, Choi SW, Kim K, Shin BJ. Current Concepts in the Management of Osteoporotic Vertebral Fractures: A Narrative Review. *Asian Spine J*. 2020 Dec;14(6):898-909. doi: 10.31616/asj.2020.0594. Epub 2020 Dec 22. PMID: 33373513; PMCID: PMC7788360.
135. Coe JD, Warden KE, Herzig MA, McAfee PC. Influence of bone mineral density on the fixation of thoracolumbar implants. A comparative study of transpedicular screws, laminar hooks, and spinous process wires. *Spine (Phila Pa 1976)*. 1990 Sep;15(9):902-7. doi: 10.1097/00007632-199009000-00012. PMID: 2259978.
136. Soshi S, Shiba R, Kondo H, Murota K. An experimental study on transpedicular screw fixation in relation to osteoporosis of the lumbar spine. *Spine (Phila Pa 1976)*. 1991 Nov;16(11):1335-41. doi: 10.1097/00007632-199111000-00015. PMID: 1750009.
137. Watanabe K, Katsumi K, Ohashi M, Shibuya Y, Hirano T, Endo N, Kaito T, Yamashita T, Fujiwara H, Nagamoto Y, Matsuoka Y, Suzuki H, Nishimura H, Terai H, Tamai K, Tagami A, Yamada S, Adachi S, Yoshii T, Ushio S, Harimaya K, Kawaguchi K, Yokoyama N, Oishi H, Doi

- T, Kimura A, Inoue H, Inoue G, Miyagi M, Saito W, Nakano A, Sakai D, Nukaga T, Ikegami S, Shimizu M, Futatsugi T, Ohtori S, Furuya T, Orita S, Imagama S, Ando K, Kobayashi K, Kiyasu K, Murakami H, Yoshioka K, Seki S, Hongo M, Kakutani K, Yurube T, Aoki Y, Oshima M, Takahata M, Iwata A, Endo H, Abe T, Tsukanishi T, Nakanishi K, Watanabe K, Hikata T, Suzuki S, Isogai N, Okada E, Funao H, Ueda S, Shiono Y, Nojiri K, Hosogane N, Ishii K. Surgical outcomes of spinal fusion for osteoporotic vertebral fracture in the thoracolumbar spine: Comprehensive evaluations of 5 typical surgical fusion techniques. *J Orthop Sci.* 2019 Nov;24(6):1020-1026. doi: 10.1016/j.jos.2019.07.018.
138. Tandon V, Franke J, Kalidindi KKV. Advancements in osteoporotic spine fixation. *J Clin Orthop Trauma.* 2020 Sep-Oct;11(5):778-785. doi: 10.1016/j.jcot.2020.06.028. Epub 2020 Jul 6. PMID: 32904223; PMCID: PMC7452352.
139. Kiner DW, Wybo CD, Sterba W, Yeni YN, Bartol SW, Vaidya R. Biomechanical analysis of different techniques in revision spinal instrumentation: larger diameter screws versus cement augmentation. *Spine (Phila Pa 1976).* 2008 Nov 15;33(24):2618-22. doi: 10.1097/BRS.0b013e3181882cac. PMID: 19011543.
140. Hirano T, Hasegawa K, Takahashi HE, Uchiyama S, Hara T, Washio T, Sugiura T, Yokaichiya M, Ikeda M. Structural characteristics of the pedicle and its role in screw stability. *Spine (Phila Pa 1976).* 1997 Nov 1;22(21):2504-9; discussion 2510. doi: 10.1097/00007632-199711010-00007. PMID: 9383856.
141. Lubansu A, Rynkowski M, Abeloos L, Appelboom G, Dewitte O. Minimally invasive spinal arthrodesis in osteoporotic population using a cannulated and fenestrated augmented screw: technical description and clinical experience. *Minim Invasive Surg.* 2012;2012:507826. doi: 10.1155/2012/507826. Epub 2012 Aug 30. PMID: 22970360; PMCID: PMC3437300.
142. McCoy S, Tundo F, Chidambaram S, Baaj AA. Clinical considerations for spinal surgery in the osteoporotic patient: A comprehensive review. *Clin Neurol Neurosurg.* 2019 May;180:40-47. doi: 10.1016/j.clineuro.2019.03.010. Epub 2019 Mar 11. PMID: 30921564.
143. Cook SD, Salkeld SL, Stanley T, Faciane A, Miller SD. Biomechanical study of pedicle screw fixation in severely osteoporotic bone. *Spine J.* 2004 Jul-Aug;4(4):402-8. doi: 10.1016/j.spinee.2003.11.010. PMID: 15246300.
144. Alhashash M, Shousha M. Minimally Invasive Short-Segment Anteroposterior Surgery for Thoracolumbar Osteoporotic Fractures with Canal Compromise: A Prospective Study with a Minimum 2-Year Follow-up. *Asian Spine J.* 2022 Feb;16(1):28-37. doi: 10.31616/asj.2020.0573. Epub 2021 May 7. PMID: 33957023; PMCID: PMC8874002.
145. DeWald CJ, Stanley T. Instrumentation-related complications of multilevel fusions for adult spinal deformity patients over age 65: surgical considerations and treatment options in patients with poor bone quality. *Spine (Phila Pa 1976).* 2006 Sep 1;31(19 Suppl):S144-51. doi: 10.1097/01.brs.0000236893.65878.39. PMID: 16946632.
146. Hilibrand AS, Moore DC, Graziano GP. The role of pediculolaminar fixation in compromised pedicle bone. *Spine (Phila Pa 1976).* 1996 Feb 15;21(4):445-51. doi: 10.1097/00007632-199602150-00008. PMID: 8658248.
147. Park YS, Kim HS, Baek SW, Kong DY, Ryu JA. The effect of zoledronic acid on the volume of the fusion-mass in lumbar spinal fusion. *Clin Orthop Surg.* 2013 Dec;5(4):292-7. doi: 10.4055/cios.2013.5.4.292. Epub 2013 Nov 18. PMID: 24340149; PMCID: PMC3858088.
148. Okuda S, Oda T, Miyauchi A, Haku T, Yamamoto T, Iwasaki M. Surgical outcomes of posterior lumbar interbody fusion in elderly patients. *J Bone Joint Surg Am.* 2006 Dec;88(12):2714-20. doi: 10.2106/JBJS.F.00186. PMID: 17142422.
149. Hadjipavlou AG, Nicodemus CL, al-Hamdan FA, Simmons JW, Pope MH. Correlation of bone equivalent mineral density to pull-out resistance of triangulated pedicle screw construct. *J Spinal Disord.* 1997 Feb;10(1):12-9. PMID: 9041491.
150. Kuklo TR, Lehman RA Jr. Effect of various tapping diameters on insertion of thoracic pedicle screws: a biomechanical analysis. *Spine (Phila Pa 1976).* 2003 Sep 15;28(18):2066-71. doi: 10.1097/01.BRS.0000084665.31967.02. PMID: 14501915.
151. Polly DW Jr, Orchowski JR, Ellenbogen RG. Revision pedicle screws. Bigger, longer shims--what is best? *Spine (Phila Pa 1976).* 1998 Jun 15;23(12):1374-9. doi: 10.1097/00007632-199806150-00015. PMID: 9654629.
152. Shea TM, Laun J, Gonzalez-Blohm SA, Dougeris JJ, Lee WE 3rd, Aghayev K, Vrionis FD. Designs and techniques that improve the pullout strength of pedicle screws in osteoporotic vertebrae: current status. *Biomed Res Int.* 2014;2014:748393. doi: 10.1155/2014/748393. Epub 2014 Mar 3. PMID: 24724097; PMCID: PMC3958762.
153. Pingel A, Kandziora F, Hoffmann CH. Osteoporotic L1 burst fracture treated by short-segment percutaneous stabilization with cement-augmented screws and kyphoplasty (hybrid technique). *Eur Spine J.* 2014;23:2022-3.
154. Curry, S. J., Krist, A. H., Owens, D. K., Barry, M. J., Caughey, A. B., Davidson, K. W., Doubeni, C. A., Epling, J. W., Kemper, A. R., Kubik, M., Landefeld, C. S., Mangione, C. M., Phipps, M. G., Pignone, M., Silverstein, M., Simon, M. A., Tseng, C.-W., & Wong, J. B. (2018). Screening for Osteoporosis to Prevent Fractures. *JAMA*, 319(24), 2521. <https://doi.org/10.1001/jama.2018.7498>
155. Krenzlin H, Schmidt L, Jankovic D, Schulze C, Brockmann MA, Ringel F, Keric N. Impact of Sarcopenia and Bone Mineral Density on Implant Failure after Dorsal Instrumentation in Patients with Osteoporotic Vertebral Fractures. *Medicina (Kaunas).* 2022 May 31;58(6):748. doi: 10.3390/medicina58060748. PMID: 35744011; PMCID: PMC9228941.