



ISSN:

2542-2758 (Print) 2542-2804 (Online)

ARTICLE INFO:

Received Date: 10/12/2023

Acceptance Date: 08/02/2024

Published Date: 16/04/2024

KEYWORDS:

Real time Ultrasound, Subclavian vein cannulation, Trendelenburg position

CORRESPONDING AUTHOR:

Deepak Poudel

Lecturer

Department of Anesthesia and Critical Care
Birat Medical College Teaching Hospital
Biratnagar, Morang

Email: drdeepak.poudel@gmail.com

ORCID ID: 0000-0001-9592-2750

Access the article online

DOI: <https://doi.org/10.62065/bjhs530>

CITATION:

Poudel D, Pyakurel K, Pokhrel A, Jha AP, Khanal K, Adhikari M. Ultrasonographic Evaluation of the Effect of Patient Position on Size of Subclavian Vein: An Observational, Prospective Study. *Birat J. Health Sci.* 2024;9(1):34-38.

COPYRIGHT:

© Authors retain copyright and grant the journal right of first publication with the work simultaneously licensed under Creative Commons Attribution License CC - BY 4.0 which allows others to share the work with an acknowledgment of the work's authorship and initial publication in this journal.



Ultrasonographic Evaluation of the Effect of Patient Position on Size of Subclavian Vein: An Observational, Prospective Study

Deepak Poudel¹, Kumud Pyakurel², Anuja Pokhrel³, Anant Piyush Jha⁴, Kanak Khanal⁵, Milan Adhikari⁶

¹ Lecturer, Department of Anesthesia and Critical Care, Birat Medical College Teaching Hospital, Biratnagar, Morang

² Assistant Professor, Department of Anesthesia and Critical Care, Birat Medical College Teaching Hospital, Biratnagar, Morang

³ Lecturer, Department of Anesthesia and Critical Care, Birat Medical College Teaching Hospital, Biratnagar, Morang

⁴ Lecturer, Department of Anesthesia and Critical Care, Birat Medical College Teaching Hospital, Biratnagar, Morang

⁵ Consultant, Department of Anesthesia and Critical Care, Birat Medical College Teaching Hospital, Biratnagar, Morang

⁶ Medical Officer, Department of Anesthesia and Critical Care, Birat Medical College Teaching Hospital, Biratnagar, Morang

ABSTRACT

Introduction: The use of real time ultrasound guided cannulation of the subclavian vein is increasing in critically ill and surgical patient population. The larger diameter of the veinduringcannulationhelps to reduce the frequency of associated complications.

Objectives: To compare change in the diameter of the subclavian vein in 15° head down and 15° head up position with that of the supine position.

Methodology: A prospective observational study was conducted among the patients visiting Department of Anesthesia and Critical Care in Birat Medical College Teaching Hospital for elective surgery from April 2023 to January 2024.

Results: The diameter of subclavian vein increased by 18.38±9.1% in head down (Trendelenburg) position and decreased by 15.8±9.8 % in head up position compared to supine position when evaluated by real time ultrasound.

Conclusion: The head down (Trendelenburg) increases the diameter of the subclavian vein, so this position is advisable during cannulation or any other procedures.

INTRODUCTION

The subclavian vein cannulation is carried out in the intensive care unit, emergency room and operation theatres. The main objectives of choosing subclavian vein can be same as choosing jugular or femoral veins for intravenous access, insertion of hemodialysis catheters, monitoring of central pressures or providing various vasopressors, inotropes and intravenous nutrition, placing cardiac pacemaker leads.¹ The subclavian vein offers some specific advantages like maximum patient comfort and tolerance, reduced rate of infection and thrombosis.^{2,3} Furthermore the subclavian vein provides unique advantage of being patent even in hypovolemic patients as the clavipectoral fascia holds the vessel open.⁴ The "blind" or landmark guided approach of subclavian vein cannulation was found to be associated with various complications like pneumothorax, arterial puncture, hematoma formation, air embolism and failure to puncture. The rate of these complications has been found to be around 12.3%.⁵ The body of evidence linking the use of ultrasound and reduction in complications is increasing. The Agency for Healthcare Research and Quality (AHRQ) in USA and the National Institute of Clinical Excellence (NICE) in UK have recommended the use of USG guidance for CVC placement as one of the practices to improve patient care.^{6,7}

The successful cannulation of the subclavian vein depends on various factors. The use of real time ultrasound increases the success rate and decreases the rate of complications. The major factor in successful puncture of the subclavian vein is the diameter of the vein at the time of puncture. Various maneuvers have been described to increase the diameter of the vein.⁸ Keeping the patient in Trendelenburg (head down) position is thought to increase the caliber of the vein and increase the chances of successful puncture, decrease the chances of injury to the surrounding structure and reduce the chances of venous air embolism.^{1,10} The knowledge regarding the angle of the patient for optimal head down position and degree of change in size of the vein in different angles are limited.

Similarly in many scenarios the patient can't be put in head down position and the physicians are required to cannulate the subclavian vein in head up position. These instances may include patients with respiratory distress, injury to spinal column, head injury patients etc. In such scenarios the change in diameter of the subclavian vein as compared to supine position is not properly known.¹¹ In these patients the subclavian vein has to be cannulated in head up position. The data regarding the diameter of the subclavian vein in such instances is very limited.

The objective of this study was to measure the diameter of the subclavian vein in supine patients and compare it to the 15° head down (Trendelenburg position) and 15° head up position using real time ultrasonography in patients visiting Birat Medical College Teaching Hospital for elective surgical procedures.

METHODOLOGY

This prospective, cross-sectional and observational study was carried out in 100 patients (ASA I and II) who were about to undergo various elective surgeries. Ethical approval was taken from the Institutional Review Committee. Written informed consent was taken from the patients scheduled for elective surgeries. The patients with thoracic injuries, previous history of clavicle fracture or surgery, any lung diseases were excluded from the study. A convenience sampling method was used and data was collected from April 2023 to June 2023. A sample size of 100 patients was calculated based on previous study.¹

The demographic data was recorded as per the proforma. The patients were asked to lie down supine with arms by the side of the body and head kept in the neutral position. After attaching

standard ASA monitors they were asked to expose the upper chest. A female nurse was asked to standby during examination of the female patients. A high frequency linear probe (6-13 MHz) (Sonosite® M-Turbo, Fujifilm® Sonosite, Bothell, WA, USA) was used to scan the infraclavicular area. The short axis view of the right subclavian vein was obtained and maximum anterior posterior diameter was measured and recorded. Since the right subclavian is the preferred vein in maximum patients due to relatively easy accessibility and comfort of the physician performing the cannulation. In addition to that the right subclavian vein has shorter course to the right atrium compared to left, we choose to scan and record changes in the right subclavian vein only. The bed was then tilted upwards by 15 degrees. The tilt was confirmed by an angle dial attached at the lateral end of the bed. After waiting for 3 Minutes, a repeat scan of the infraclavicular area was done and the maximum anterior posterior diameter was recorded. The bed is then again tilted by 15 degrees head down position and similar observations were recorded.

Data were entered in Microsoft Excel® 2013 and analysed using SPSS® 22 (SPSS Inc., Chicago, IL, USA). The results were averaged (mean ± standard deviation [SD]) for each parameter for continuous data. The Chi-square test was used to determine the statistical difference between variables. Frequencies and percentages were used to represent data.

RESULTS

100 patients were examined which included 45 males and 55 females. The age of the patients varied from 19 years to 86 years with a mean age of 63.5 years. The height of the patients varied from 145 cm to 182 cm with mean age of 161.87 cm. The weight varied from 42 kg to 94 kg with mean 61.7 kg.

Table 1: Demographic variables

Variable	Range	Mean ±SD
1. Age	19-86 years	63.5 ±18.34 years
2. Height	145-182 cm	161.87 ±7.39 cm
3. Weight	42-94 kg	61.7 ±10.19 kg
4. BMI	15.52-36.52	23.68 ±4.32

Table 2: Study variables

Position	Mean diameter ±SD(cm)	Mean change from supine ±SD	P	Percentage change from supine±SD
Supine	0.75 ±0.14	0.00	-	0.00
Head down	0.88±0.13	0.13±0.05	0.006	18.38±9.1
Head up	0.63±0.14	0.11±0.08	0.017	15.8±9.8

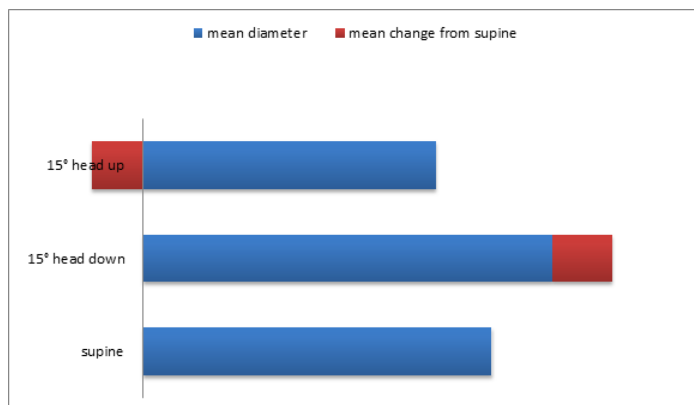


Fig 1: Mean diameter of Subclavian vein during supine, 15° head down and 15° head up positions with mean change in diameter compared to diameter in supine position.

The mean \pm SD diameter of the vein in supine position was 0.75 ± 0.14 cm. When the patients were put in head up position the diameter decreased to 0.63 ± 0.14 cm. The diameter increased to 0.88 ± 0.13 cm when the position was converted to head down. The mean decrease in diameter during head up position from supine position was 15.8 ± 9.8 %. The mean increase in diameter during head down position from supine position was 18.38 ± 9.1 % which was statistically significant.

DISCUSSION

Anatomically the subclavian vein is direct continuation of the axillary vein. The distinct demarcation between axillary and subclavian vein is lacking.¹² The lateral part of the subclavian is actually part of the axillary vein but this does not make much of a difference in the cannulation of the vein in terms of caliber of the vein, difficulty in performing the cannulation or the rate of complications. The major advantages of cannulating a subclavian vein are in shock patients; reduced catheter related infections and increased patient's comfort. The subclavian vein is surrounded by fascia which prevents its collapse in hypovolemic shock patients and can be used during emergency.^{13, 14} The rate of catheter related infections were lower in subclavian vein cannulation when compared with femoral or internal jugular vein.¹⁵

In this study, the mean diameter \pm SD of the subclavian vein was 0.88 ± 0.13 cm in head down (Trendelenburg) position. This finding is similar to the study conducted by Fortune et al in 10 healthy individuals.¹ Similar to the study by Fortune et al, in our study, the diameter was measured keeping the head in neutral position and without arching the shoulders. Various controversies exist regarding the optimal position of head and shoulders for visualization and cannulation of the subclavian vein. Earlier it was thought that Trendelenburg position with head turned to the opposite side and a roll placed beneath the shoulder arch would facilitate the visualization and puncture of the subclavian vein.¹⁶ But large part of this idea was challenged by various studies done in cadavers, volunteers and magnetic resonance imaging.^{8, 17, 18} The Trendelenburg position is thought

to increase the venous return to the thorax and distend the subclavian vein by increasing the hydrostatic pressure.¹⁸

The head turning to the opposite side is thought to increase the traction on superior vena cava thereby allowing the catheter inserted to direct towards internal jugular vein rather than superior vena cava.¹⁶ This can be prevented by keeping the head position in neutral i.e. staring forward.⁸ But in a study by Fortune et al, they found that the head kept in neutral position has maximum diameter when compared to that of head turned to opposite or same side.¹ This finding helps to support our hypothesis of keeping head in neutral position. On the contrary in a study conducted by Kim et al, 30 degrees of head rotation to the ipsilateral side increased the mean diameter when compared with contra lateral side.¹⁶ This difference could be because our patients were fasted for eight hours for surgical procedure.

Similarly placing a shoulder roll between the shoulder blades or below the shoulder was thought to bring the subclavian vein more superficial and facilitate at much less depth.¹¹ This has been disputed and head and shoulders in neutral position is postulated as optimal for visualization and cannulation.¹⁷

The diameter of the subclavian vein decreased when the patient was kept in head up position. This can be attributed to decrease in hydrostatic pressure in the larger veins. In a similar study conducted by Lister et al., they found the decrease in mean diameter of the subclavian vein in head up position when compared to supine position was 0.65 ± 0.33 cm.¹¹ This finding is similar to our study. The authors of this study did not come across any studies where subclavian vein has been cannulated in head up position. This can be attributed to the decrease in diameter of the vein, increasing discomfort to the patient and difficult ergonomics for the physician performing the procedure. Furthermore the added fear of indrawing of air from the puncture site into the vein and causing venous air embolism reduces the enthusiasm.

In a study conducted by Lavalley et al, the mean diameter of the subclavian vein in Trendelenburg position was 1.02 ± 0.3 cm in the right side which is larger compared to our study. The increase in size can be attributed to them measuring in anesthetised individuals with endotracheal intubation and positive pressure ventilation.¹⁹ We measured the diameter in spontaneously breathing individuals with eight hours of fasting before the elective surgical procedure.

The use of real time ultrasound has various advantages during the subclavian vein visualization and cannulation. In our study we did not cannulate the vein but having large diameter vein during the cannulation decreases the risk of injury to surrounding structures like subclavian artery, pleura, brachial plexus and lungs.^{20, 21} The maneuver of putting the patient in Trendelenburg or head down position is the most feasible for increasing the size of subclavian vein. But this maneuver is sometimes poorly tolerated in patients with severe respiratory distress and patients with increased intracranial pressure.¹¹ These groups of patients are deprived of benefits of subclavian

venous cannulation. In addition, the use of subclavian vein for use of dialysis catheterization was associated with increased risk of venous stenosis in chronic kidney disease patients in long term.²

CONCLUSIONS

The head down (Trendelenburg) position with head and arm in neutral position increases the diameter of the subclavian vein, so this position is advisable during visualization of the vein for any procedures.

Recommendations: We recommend further studies in the patients regarding the ease of cannulation, rate of complications along with time required for successful cannulation of the subclavian vein after the patient has been kept in Trendelenburg position. We would also like to recommend studies looking for feasibility and rate of complications during cannulation of the subclavian vein in reverse Trendelenburg or head up position.

Limitations of the study There are several limitations in our study. We only used ultrasound to measure the diameter of the vein but the success of the subclavian vein cannulation is guided by various factors like cooperation from the patient, experience of the clinician and procedure being performed. Larger size of the vein is obviously easier to visualize but may not indicate successful and complication free cannulation. We measured the changes in the right subclavian vein only which may or may not be extrapolated directly to the changes in left subclavian vein. We measured the subclavian vein in normal breathing, non anesthetized patients. This finding may not be reliably extrapolated in anesthetized patients or in patients with various pulmonary or vascular co morbidities, patients with obesity, critically ill patients or patients who are in severe hypovolemia.

Acknowledgements We would like to acknowledge our study participants, staffs and colleagues for their valuable support.

Conflict of interest The authors state no potential conflicts of interest.

Financial Disclosure There is no financial support for this study.

REFERENCES

- Fortune JB, Feustel P, Butler KL. Effect of patient position on size and location of the subclavian vein for percutaneous puncture. *Arch Surg*. 2003;138(9):996–1001. DOI: 10.1001/archsurg.138.9.996
- Schulman PM, Gerstein NS, Merkel MJ, Braner DA, Tegtmeier K. Ultrasound-Guided Cannulation of the Subclavian Vein. *N Engl J Med*. 2018;379(1):e1. DOI: 10.1056/NEJMc1406114 PMID: 29972747,
- Marik PE, Flemmer M, Harrison W. The risk of catheter-related bloodstream infection with femoral venous catheters as compared to subclavian and internal jugular venous catheters: A systematic review of the literature and meta-analysis. Vol. 40, *Critical Care Medicine*. 2012. p. 2479–85. DOI: 10.1097/CCM.0b013e318255d9bc PMID: 22809915
- Frykholm P, Pikwer A, Hammarskjöld F, Larsson AT, Lindgren S, Lindwall R, et al. Clinical guidelines on central venous catheterisation. Swedish Society of Anaesthesiology and Intensive Care Medicine. *Acta Anaesthesiol Scand* [Internet]. 58(5):508–24. DOI: 10.1111/aas.12295 PMID: 24593804
- Palepu G, Deven J, Subrahmanyam M, Mohan S. Impact of ultrasonography on central venous catheter insertion in intensive care. *Indian J Radiol Imaging*. 2009;19(3):191–8. DOI: 10.4103/0971-3026.54877 PMID: 2766872, PMID: 19881083
- NICE. Guidance on the use of ultrasound locating devices for placing central venous catheters. *Technol Apprais Guid*. 2016;(October 2002):49. www.nice.org.uk/guidance/ta49
- Franco-Sadud R, Schnobrich D, Mathews BK, Candotti C, Abdel-Ghani S, Perez MG, et al. Recommendations on the Use of Ultrasound Guidance for Central and Peripheral Vascular Access in Adults: A Position Statement of the Society of Hospital Medicine. *J Hosp Med*. 2019 Sep 1;14(9):E1–22. DOI: 10.12788/jhm.3287 PMID: 31561287, PMID: PMC10193861
- Yoon HK, Lee HC, Kang P, Lee JM, Park HP, Cho YJ. Effects of ipsilateral tilt position on the cross-sectional area of the subclavian vein and the clinical performance of subclavian vein catheterization: A prospective randomized trial. *BMC Anesthesiol*. 2020;20(1):1–9.
- Rodriguez CJ, Bolanowski A, Patel K, Perdue P, Carter W, Lukish JR. Classical positioning decreases the cross-sectional area of the subclavian vein. *Am J Surg*. 2006;192(1):135–7. PMID: 16769291, DOI: 10.1016/j.amjsurg.2005.09.005
- Sakuraya M, Okano H, Yoshihiro S, Niida S, Kimura K. Insertion site of central venous catheter among hospitalized adult patients: A systematic review and network meta-analysis [Internet]. Vol. 9, *Frontiers in Medicine*. Frontiers Media S.A.; 2022 DOI: 10.3389/fmed.2022.960135 PMID: PMC9464814
- Lister RB, Welfare OWDA, Cheri T, Park MAJ. “Stop sign” position for subclavian ultrasound: a single-blinded observational study of subclavian vein dimensions. *Eur J Emerg Med*. 2020;27(5):351–6. DOI: 10.1097/MEJ.0000000000000676 PMID: 32073415

12. Connolly MR, Auchincloss HG. Anatomy and Embryology of the Thoracic Outlet. *Thorac Surg Clin*. 2021;31(1):1–10. DOI: [10.1016/j.thorsurg.2020.09.007](https://doi.org/10.1016/j.thorsurg.2020.09.007) PMID: 33220766
13. Bannon MP, Heller SF, Rivera M. Anatomic considerations for central venous cannulation. *Risk Manag Healthc Policy*. 2011;4:27–39. DOI: [10.2147/RMHP.S10383](https://doi.org/10.2147/RMHP.S10383) PMID: 22312225, PMCID: PMC3270925
14. Arrighi DA, Farnell MB, Mucha P, Anderson DL. Prospective, Randomized Trial of Rapid Venous Access for Patients in Hypovolemic Shock. 1989;(September):927–30. DOI: [10.1016/s0196-0644\(89\)80454-8](https://doi.org/10.1016/s0196-0644(89)80454-8) PMID: 2669571
15. Lamperti M, Bodenham AR, Blaivas M, Augoustides JG, Ledonne J, Feller-kopman D, et al. International evidence-based recommendations on ultrasound-guided vascular access. 2012;1105–17. DOI: [10.1007/s00134-012-2597-x](https://doi.org/10.1007/s00134-012-2597-x) PMID: 22614241
16. Kim H, Chang JE, Lee JM, Han SH, Ryu JH, Hwang JY. The Effect of Head Position on the Cross-Sectional Area of the Subclavian Vein. *Anesth Analg*. 2018 Jun;126(6):1946–1948. PMID: 28863021.
17. Kitagawa N, Oda M, Totoki T, Miyazaki N, Nagasawa I, Nakazono T, et al. Proper shoulder position for subclavian venipuncture: A prospective randomized clinical trial and anatomical perspectives using multislice computed tomography. *Anesthesiology*. 2004;101(6):1306–12. DOI: [10.1097/00000542-200412000-00010](https://doi.org/10.1097/00000542-200412000-00010) PMID: 15564937
18. Matthews NT, Worthley LIG. Immediate Problems Associated with Infraclavicular Subclavian Catheterisation; A Comparison between Left and Right Sides. *Anaesth Intensive Care* . 1982 May 1;10(2):113–5. DOI: [10.1177/0310057X8201000203](https://doi.org/10.1177/0310057X8201000203) PMID: 7103038
19. Lavallée C, Ayoub C, Mansour A, Lambert J, Lebon JS, Lalu MM, et al. Subclavian and axillary vessel anatomy: a prospective observational ultrasound study. *Can J Anesth*. 2018;65(4):350–9. DOI: [10.1007/s12630-017-1032-8](https://doi.org/10.1007/s12630-017-1032-8) PMID: 29209928
20. Gu YJ, Lee JH, Seo JI. Effect of lumbar elevation on dilatation of the central veins in normal subjects. *Am J Emerg Med*. 2019;37(3):539–42. DOI: [10.1016/j.ajem.2018.07.032](https://doi.org/10.1016/j.ajem.2018.07.032) PMID: 30033135
21. Smith RN, Nolan JP. Central venous catheters. *BMJ*. 2013;347(November):1–11. DOI: [10.1136/bmj.f6570](https://doi.org/10.1136/bmj.f6570) PMID: 24217269