



ISSN:

2542-2758 (Print) 2542-2804 (Online)

ARTICLE INFO:

Received Date: 2023-04-09

Acceptance Date: 2024-07-02

Published Date:

KEYWORDS:

Abnormal Uterine Bleeding (AUB), Hysteroscopy, 3D Ultrasonography (3D USG), Transvaginal ultrasonography (TVS)

CORRESPONDING AUTHOR:

Roshana Khadka

Assistant Professor,

Department Radiodiagnosis and Imaging, Birat Medical College and Teaching Hospital, Nepal

Email: khadka_roshana@hotmail.com

Orchid ID: 0000-0003-4301-8406

Access the article online

DOI: <https://doi.org/10.62065/bjhs615>

CITATION:

Khadka R. Comparative Study between Three-Dimensional Transvaginal Ultrasonography and Hysteroscopy in Patients with Abnormal Uterine Bleeding at Birat Medical College Teaching Hospital. *Birat J. Health Sci.* 2024;9(2):67-72.

COPYRIGHT:

© Authors retain copyright and grant the journal right of first publication with the work simultaneously licensed under Creative Commons Attribution License CC - BY 4.0 which allows others to share the work with an acknowledgment of the work's authorship and initial publication in this journal.



Comparative Study between Three-Dimensional Transvaginal Ultrasonography and Hysteroscopy in Patients with Abnormal Uterine Bleeding at Birat Medical College Teaching Hospital

Roshana Khadka¹, Ajay yadav¹, Gyanendra Man Singh Karki², Prerana Dahal³, Sushil Taparia⁴

¹ Assistant Professor, Department Radiodiagnosis and Imaging, BMCTH² Associate Professor, Department of Obstetrics and Gynaecology, BMCTH³ Assistant Professor, Department of Obstetrics and Gynaecology, BMCTH⁴ Consultant Radiologist, Department of Radiodiagnosis and Imaging, Birat Nursing Home

ABSTRACT

Introduction: Hysteroscopy has been a gold standard in diagnosis of various uterine pathologies which are potential uterine causes of abnormal uterine bleeding (AUB) Recently Transvaginal 3D ultrasonography (3D USG) has boomed as a non-invasive imaging modality that promises to be resourceful in the detection and evaluation of pelvic pathologies contributing to the causes of AUB.

Objective: Compare the diagnostic accuracy of 3D USG and Hysteroscopy in evaluation of the causes of abnormal uterine bleeding

Methodology: Across sectional study conducted in the department of Radiodiagnosis and the department of Obstetrics and Gynecology (OBG) at Birat Medical College and Teaching Hospital enrolling 70 participants with history of abnormal uterine bleeding who consented for undergoing TVS and Hysteroscopy for the period of 6 months.

Results: 3D TVS and Hysteroscopy, both revealed notable differences in their diagnostic abilities. 3D TVS identified myomas in 56.25%, particularly detecting intramural myomas in 37.5%, which Hysteroscopy failed to identify. In contrast, Hysteroscopy was more effective at detecting submucosal myomas (42.86%) and polyps (42.86%), outperforming 3D TVS in both categories. Detection rates for hyperplasia were comparable, and both methods detected endometrial mass in one case each. These findings suggest that the two techniques complement each other in the evaluation of uterine abnormalities.

Conclusion: While 3D TVS is more effective at detecting intramural myomas, Hysteroscopy has a higher detection rate for submucosal myomas and polyps, thus highlighting the complementary roles of these diagnostic techniques.

INTRODUCTION

Abnormal uterine bleeding (AUB) refers to variations in the menstrual cycle, including changes in the frequency, regularity, duration, and volume of menstrual flow, excluding pregnancy-related bleeding. This condition is widespread, affecting a significant percentage of women globally, with an estimated prevalence ranging between 10% and 30% among those of reproductive age. The incidence is especially high during life stages marked by hormonal shifts, such as menarche and perimenopause, where these fluctuations often contribute to the onset of AUB. Various uterine conditions, including endometrial polyps, fibroids (myomas), intrauterine adhesions (synechiae), endometrial hyperplasia, and endometrial cancer, are significant contributors to AUB. These conditions disrupt the normal structure and function of the endometrium, leading to abnormal bleeding patterns.¹

In recent years, methods for assessing the uterine cavity have significantly advanced. Traditionally, dilation and curettage (D&C) were used, but this approach often failed to detect smaller or more challenging lesions within the uterus.² Hysteroscopy, by

contrast, is now regarded as the gold standard for diagnosing intrauterine abnormalities.^{3,4,5} It offers a direct view inside the uterus, enabling more precise detection of abnormalities and the ability to perform targeted biopsies and treatments in the same session, thereby improving patient convenience and satisfaction.⁶ Despite these advantages, hysteroscopy is an invasive and costly procedure with potential risks, including uterine perforation, which occurs in 0.1% to 1.3% of cases, and the possibility of ascending genitourinary infections.⁷ Additionally, hysteroscopy provides only an approximate assessment of fibroid size and limited information regarding the extent of myometrial invasion, which reduces its effectiveness in cases where deep myometrial involvement is critical.⁸

With technological advancements, 3D ultrasonography has emerged as a highly refined tool, offering a clearer and more detailed view of the endometrial cavity and overall uterine structure. This technique allows for better visualization of uterine abnormalities, such as fibroids and their impact on the uterine cavity.⁹ Additionally, 3D ultrasound improves the accuracy of diagnosing endometrial polyps and provides the ability to measure endometrial volume, which may lead to better diagnostic outcomes in cases of AUB.¹⁰ So, by comparing these two modalities, the study aims to identify which tool is more effective for the diagnosis of causes of AUB and to assess whether 3D TVS USG can serve as a reliable non invasive alternative to hysteroscopy in the evaluation of AUB.

METHODOLOGY

A cross-sectional analytical study was carried out from October 2023 to March 2024 in the Departments of Radiodiagnosis and Obstetrics and Gynecology (OBG) at Birat Medical College and Teaching Hospital. The study targeted patients presenting with abnormal uterine bleeding (AUB) to the OBG department, with consecutive sampling employed to recruit participants. The study group comprised individuals who had undergone both transvaginal sonography (TVS) and hysteroscopy for AUB within the past six months. The sample size was therefore calculated using the finite population correction formula¹¹: $Sample\ size = N \times X / X + (N - 1)$ where $N = population\ size$, $X = z^2 \times p(1 - p) / (MOE)^2$, with confidence level of 95% corresponding to a z-score of 1.96, 5% margin of error (MOE) and an estimated population proportion (p) of 0.5, yielding a sample size of approximately 70. Ethical approval was obtained from the Institutional Review Board of Birat Medical College and Teaching Hospital (IRC-PA-305/2023) and informed consent was secured from all participants. All patients presenting with the complains of AUB and willing to participate in the study were enrolled. Those presenting with pregnancy related bleeding, cervical and or vaginal masses and patients not giving their consent to participate were excluded from the study. Data were entered into MS Excel and analyzed using SPSS software. Descriptive statistics using percentages were applied to summarize and present findings for both normal and abnormal cases identified by 3D TVS and hysteroscopy. A 2x2 contingency table was constructed to compare the detection of normal and abnormal cases between the two modalities, facilitating clear identification of true positives, true negatives,

false positives, and false negatives. Sensitivity, specificity, positive predictive value (PPV) and negative predictive value (NPV) metrics were utilized to assess the diagnostic performance of 3D TVS relative to hysteroscopy. Lastly, the overall accuracy of 3D TVS in comparison to hysteroscopy was determined.

With an empty bladder, the patients were examined in the lithotomy position using Voluson Pro 720 transducer with frequency range 5-8 MHZ, which facilitated optimal visualization of the pelvic organs. The 3D image was obtained by switching on the 3D volume mode and defining the region of interest by a movable sector on the screen. The data were stored digitally on the internal disc drive for subsequent analysis after the ultrasound probe was removed. For the purpose of volume calculation, 3D data were retrieved and presented in multi-planer display mode which simultaneously displayed 3 perpendicular planes on the screen. The findings of TVS were described and compared with hysteroscopic findings. The diagnostic results categorized cases as either normal or abnormal based on findings from both modalities. Sensitivity, specificity, the positive predictive value (PPV), the negative predictive value (NPV) and overall accuracy of 3D TVS, were calculated to achieve a comprehensive framework for evaluating and comparing the diagnostic performance of 3D TVS and hysteroscopy in detecting uterine abnormalities.

RESULTS

The present study included 70 patients complaining of abnormal premenopausal uterine bleeding with age ranging from 20 to 65 years. The majority of those presenting with AUB were in the 40 to 50 age group (n = 35). The most common bleeding pattern was menorrhagia (40%) followed by menometrorrhagia (24.28%) then metrorrhagia (28.57%) then polymenorrhoea (7.1%). Out of 70 patients, 3D TVS was normal in 54 (77.14%) and abnormal in 16 (22.85%). Hysteroscopy was normal in 42 (60%) and abnormal in 28 (40%). (Table 1). Figure 1.

Table 1: 3D TVS versus Hysteroscopy results.

	3D TVS	Hysteroscopy
Normal	54(77.14%)	42(60%)
Abnormal	16(22.85%)	28(40%)
Total	70	70

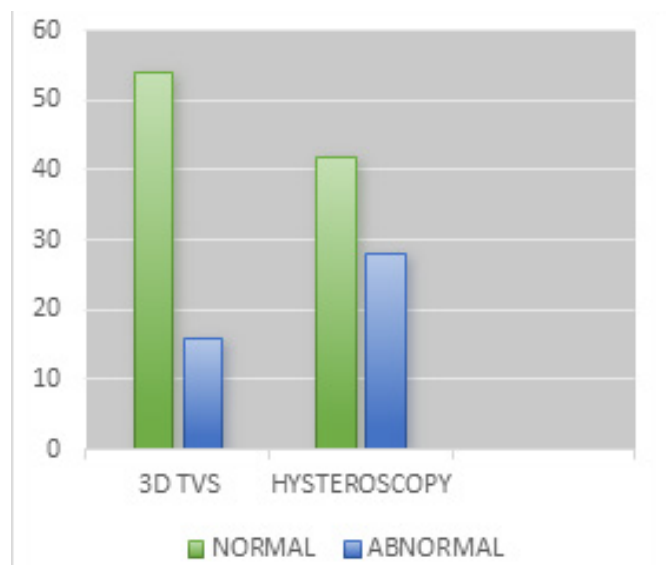


Fig 1: Comparison of findings

The abnormal findings detected by 3D TVS and Hysteroscopy were compared, showing notable differences between the two diagnostic methods. 3D TVS detected myomas in 56.25% of cases (9 out of 16), while Hysteroscopy identified myomas in 42.86% of cases (12 out of 28). In particular, intramural myomas were detected by 3D TVS in 37.50% of cases, but Hysteroscopy did not identify any. Conversely, submucosal myomas were detected in 42.86% of cases by Hysteroscopy, compared to 18.75% by 3D TVS. Polyps were more frequently identified by Hysteroscopy, which detected them in 42.86% of cases, compared to 25.00% by 3D TVS. Both methods showed similar detection rates for hyperplasia, with 3D TVS identifying it in 18.75% of cases and Hysteroscopy in 10.71%. Finally, an endometrial mass was found in 6.25% of cases by 3D TVS and 3.57% by Hysteroscopy, with only one case detected by each method (Table 2, Figure 2,3,4)

Abnormal Findings	3D TVS (n = 16)	Percentage (%)	Hysteroscopy (n = 28)	Percentage (%)
Total Myomas	9	56.25%	12	42.86%
- Intramural Myomas	6	37.50%	0	0.00%
-Submucosal Myomas	3	18.75%	12	42.86%
Polyps	4	25.00%	12	42.86%
Hyperplasia	3	18.75%	3	10.71%
Endometrial Mass	1	6.25%	1	3.57%

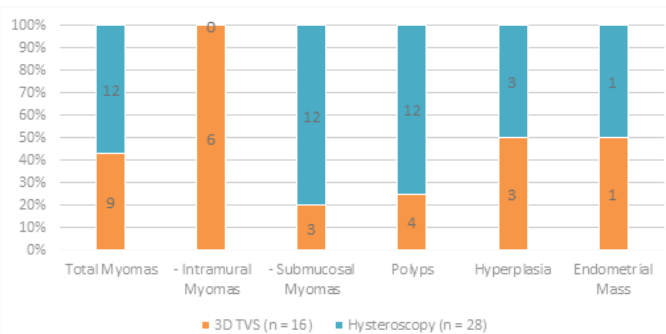


Fig 2: 3D TVS Vs Hysteroscopy in detecting uterine cavity lesions

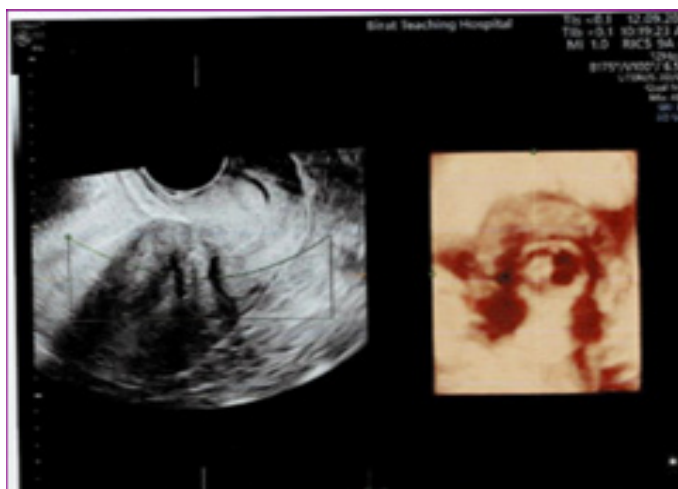

Fig 3: Submucosal myoma (3D TVS)

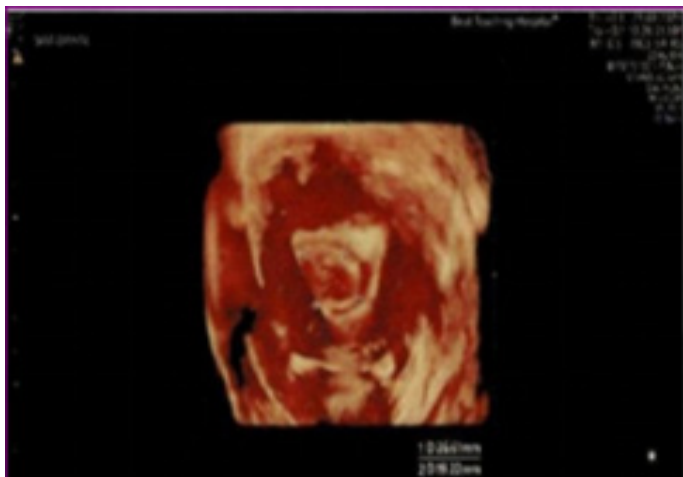


Fig 4: Endometrial polyp (3D TVS)

The sensitivity of the test was found to be 57.14%, specificity 77.78%, the positive predictive value (PPV) 57.14%, the negative predictive value (NPV) 77.78% and the overall accuracy of 3D TVS was found to be 82.86%. (Table 3)

Table 3.

	Percentage (%)
Sensitivity	57.14%
Specificity	77.78%
Positive Predictive Value (PPV)	57.14%
Negative Predictive Value (NPV)	77.78%
Accuracy	82.86%

DISCUSSION

Abnormal uterine bleeding (AUB) is a prevalent concern among women of reproductive age, constituting about one-third of outpatient visits in this demographic. By the age of 45.5 years, approximately 50% of women experience menstrual irregularities, a figure that increases to 75% by 47.8 years and reaches 95% by 50.8 years.¹² Ultrasonography has soared high as a diagnostic tool in the evaluation of pelvic pathologies and the transvaginal approach has made detection and evaluation of pathologies more clearly.¹³ In recent years, 3D transvaginal ultrasonography (3D TVS) has emerged as a non-invasive imaging method that allows for the acquisition of volumetric data and the rapid reconstruction of images in transverse, sagittal, and coronal planes. This technique provides highly accurate imaging of both the endometrial cavity and the external contours of the uterus.¹⁴ Uterine myomas, or fibroids, are typically categorized based on their location as intramural, subserosal, or submucosal, with submucosal fibroids being commonly associated with AUB. Accurate localization of these fibroids is essential for hysteroscopic resection, though its feasibility depends on the fibroid size, the degree of intramural involvement, and its protrusion into the endometrial cavity.¹⁵ Submucosal myomas are further classified based on the extent of their protrusion into the endometrial cavity: Type 0 refers to fibroid polyps that

are completely within the uterine cavity; Type I myomas are less than 50% embedded within the myometrium; and Type II myomas are more than 50% intramural, with only part of the fibroid protruding into the cavity.¹⁶ This classification is crucial in guiding treatment options, as hysteroscopic resection may be challenging or even contraindicated in Type II fibroids due to the significant myometrial involvement

In our comparative study analyzing the diagnostic effectiveness of 3D transvaginal sonography (3D TVS) and hysteroscopy in detecting uterine abnormalities, significant differences emerged in the detection rates of various conditions. 3D TVS was able to identify myomas in 56.25% of cases, which was notably higher than the 42.86% detection rate observed with hysteroscopy. Interestingly, intramural myomas were exclusively detected by 3D TVS, with a detection rate of 37.50%, whereas hysteroscopy failed to identify any cases of this type. On the other hand, hysteroscopy proved more effective in identifying submucosal myomas, detecting them in 42.86% of cases, as opposed to the lower 18.75% detection rate by 3D TVS. The sensitivity of the test was found to be 57.14%, specificity 77.78% with positive predictive value (PPV) 57.14%, the negative predictive value (NPV) 77.78% with overall accuracy of 3D TVS to be 82.86%. These findings suggest that while 3D TVS shows promising accuracy in diagnosing conditions related to the study population, its moderate sensitivity indicates that it may miss some cases, warranting consideration of complementary diagnostic methods for improved patient outcomes.

Similar patterns were observed in the research conducted by Van den Bosch et al.,¹⁷ where 3D TVS demonstrated robust diagnostic accuracy for submucosal myomas. However, hysteroscopy remained the more precise tool for detecting lesions located within the uterine cavity. Their study found that 3D TVS was able to detect submucosal myomas in 7% of cases and polyps in 26%, which aligns closely with the results of our study. In our findings, 3D TVS identified submucosal myomas in 18.75% of cases and polyps in 25% of cases, indicating similar diagnostic capabilities.

Further supporting this, a comparable study by Haemila et al.,¹⁸ which focused on women with premenopausal bleeding, revealed similar trends. In their research, 3D TVS detected myomas in 14 cases (20%), polyps in 8 cases (11.43%), and one case of endometrial mass. In contrast, hysteroscopy identified myomas in 6 cases (8.57%), polyps in 11 cases (15.72%), and one case of endometrial mass (1.43%). These findings emphasize the varying strengths of each diagnostic tool in different uterine conditions. A similar study conducted by Ayad et al.¹⁹ also reported comparable results, further highlighting the advantages of hysteroscopy over 3D TVS in detecting submucosal myomas and polyps. Their findings confirmed our observation that hysteroscopy had a detection rate of 42.86% for both abnormalities, thus reinforcing its superior ability to diagnose these particular conditions. However, in our study, 3D TVS was shown to be particularly effective in identifying intramural myomas, a finding that is consistent with the results of Exacoustos et al.,²⁰ who reported high diagnostic accuracy of 3D TVS for intramural fibroids.

Moreover, both diagnostic techniques demonstrated relatively similar detection rates for other uterine abnormalities, such as endometrial hyperplasia and endometrial masses. In our study, 3D TVS identified hyperplasia in 18.75% of cases, compared to 10.71% with hysteroscopy. For endometrial masses, the detection rates were 6.25% for 3D TVS and 3.57% for hysteroscopy, results that are in line with the existing literature on the subject. Overall, while 3D TVS proves to be a valuable diagnostic tool, especially for intramural myomas, hysteroscopy continues to be the more reliable method for detecting submucosal myomas and polyps, a conclusion supported by multiple studies across the field.

Our study strongly emphasizes the complementary roles of both 3D transvaginal sonography (3D TVS) and hysteroscopy in the accurate diagnosis of uterine abnormalities. While 3D TVS is an exceptionally effective diagnostic tool for detecting intramural myomas, it also provides highly detailed imaging of the uterine anatomy, which is critical for comprehensive evaluation. On the other hand, hysteroscopy proves to be superior when it comes to identifying submucosal myomas and endometrial polyps, especially in cases where surgical intervention is being considered. This makes hysteroscopy particularly valuable in pre-surgical planning, where precise identification of abnormalities is essential.

The combination of these two diagnostic techniques offers a more thorough and comprehensive approach to the evaluation of abnormal uterine bleeding (AUB). By utilizing both methods, clinicians can achieve a more accurate diagnosis, ensuring that the full range of uterine abnormalities is assessed. This integrated approach not only enhances diagnostic precision but also enables the development of tailored treatment plans that are better suited to each patient's specific condition. Ultimately, this multimodal approach can lead to improved patient outcomes by facilitating more targeted and effective therapeutic interventions

CONCLUSION

This study emphasizes the diagnostic strengths of 3D TVS and Hysteroscopy as essential diagnostic tools in identifying various abnormal uterine conditions which can be potential causes of abnormal uterine bleeding (AUB). While 3D TVS proved superior in detecting intramural myomas, due to its ability to provide detailed images of the myometrium and precise localization of fibroids, hysteroscopy demonstrated greater accuracy in identifying submucosal myomas and endometrial polyps. Both methods demonstrated similar detection rates for hyperplasia and endometrial masses.

The complementary roles of these modalities highlight the advantage of a multimodal approach in clinical practice. While one method may excel in detecting certain abnormalities, the use of both together allows for a more comprehensive and thorough evaluation. This integrated approach is particularly valuable in complex cases where uterine pathology is suspected, but a single imaging method may not provide sufficient information. Thus, employing both 3D TVS and hysteroscopy in tandem could significantly improve diagnostic precision and inform more effective treatment strategies for patients with AUB.

LIMITATION OF STUDY

It is a single center study so the results may not be applicable to other healthcare settings where different equipment, expertise, or protocols might be used. Also, since Both 3D TVS and Hysteroscopy are operator-dependent techniques variations in the skill and experience of the operators could influence the accuracy of the findings, potentially affecting the study's outcome.

ACKNOWLEDGEMENT

We would like to acknowledge the study participants and the Institutional Review Committee of Birat Medical College and Teaching Hospital.

CONFLICT OF INTEREST

We declare no conflict of interest in our study

FINANCIAL DISCLOSURE

We have no financial support to disclose

REFERENCES

1. Yela DA, Hidalgo SR, Pereira KCHM, Gabiatti JRE, Monteiro IMU. Comparative study of transvaginal sonography and outpatient hysteroscopy for the detection of intrauterine diseases. *Acta Med Port.* 2011;24(Suppl 2):65-70. Portuguese. Epub 2011 Dec 31. PMID: 22849887.
2. Upadhyay A, Tyagi M, Gupta S, Bansal R, Varma Y. Comparative study of hysteroscopy with ultrasonography and its correlation with histopathology in cases of abnormal uterine bleeding in perimenopausal women. *Int J Reprod Contracept Obstet Gynecol.* 2017;6(12):5309-14. DOI: [10.18203/2320-1770.ijrcog20220558](https://doi.org/10.18203/2320-1770.ijrcog20220558)
3. El-Sokkary M, Shafik A, Nader S. The role of endometrial volume in the prediction of endometrial hyperplasia. *Obstet Gynecol Int J.* 2016;4(6):228-31. doi: [10.15406/ogij.2016.04.00136](https://doi.org/10.15406/ogij.2016.04.00136). DOI: [10.15406/ogij.2016.04.00136](https://doi.org/10.15406/ogij.2016.04.00136)
4. Fleischer AC, Shappell HW, Parker LP, Hanemann CW. Color Doppler sonography of endometrial masses. *J Ultrasound Med.* 2002 Aug;21(8):861-5; quiz 867-8. DOI: [10.7863/jum.2002.21.8.861](https://doi.org/10.7863/jum.2002.21.8.861)
5. Van Dongen H, de Kroon CD, Jacobi CE, Trimbos JB, Jansen FW. Diagnostic hysteroscopy in abnormal uterine bleeding: a systematic review and meta-analysis. *BJOG.* 2007 Jun;114(6):664-75. DOI: [10.1111/j.1471-0528.2007.01326.x](https://doi.org/10.1111/j.1471-0528.2007.01326.x)
6. Allameh T, Mohammadzadeh F. Diagnostic value of hysteroscopy in abnormal uterine bleeding compared to pathology reports. *IJRM* 2007; 5 (3) :61-0.

- DOI: [10.18203/2320-1770.ijrcog20160471](https://doi.org/10.18203/2320-1770.ijrcog20160471)
7. Bradley LD, Gueye NA. The medical management of abnormal uterine bleeding in reproductive-aged women. *Am J Obstet Gynecol.* 2016 Jan;214(1):31-44. doi: 10.1016/j.ajog.2015.07.044. Epub 2015 Aug 5.
DOI: [10.1016/j.ajog.2015.07.044](https://doi.org/10.1016/j.ajog.2015.07.044)
PMID: 26254516
 8. Indman PD. Hysteroscopic complications. *J Am Assoc Gynecol Laparosc.* 1995;3(1):39-43.
DOI: [10.1016/j.ajog.2015.07.044](https://doi.org/10.1016/j.ajog.2015.07.044)
 9. Yaman C, Ebner T, Jesacher K, Obermayr G, Pölz W, Tews G. Reproducibility of three-dimensional ultrasound endometrial volume measurements in patients with postmenopausal bleeding. *Ultrasound Obstet Gynecol.* 2002 Mar;19(3):282-6.
DOI: [10.1046/j.1469-0705.2002.00644.x](https://doi.org/10.1046/j.1469-0705.2002.00644.x)
 10. Fleischer AC, Shappell HW. Color Doppler sonohysterography of endometrial polyps and submucosal fibroids. *J Ultrasound Med.* 2003 Jun;22(6):601-4.
DOI: [10.7863/jum.2003.22.6.601](https://doi.org/10.7863/jum.2003.22.6.601).
PMID: 12795556.
 11. Daniel WW. *Biostatistics: A foundation for analysis in the health sciences.* 7th ed. New York: John Wiley & Sons; 1999.
Treloar AE. Menstrual cyclicity and the pre-menopause. *Maturitas.* 1981;3(3-4):249-64.
DOI: [10.1016/0378-5122\(81\)90032-3](https://doi.org/10.1016/0378-5122(81)90032-3)
 12. Abbott JA. Adenomyosis and abnormal uterine bleeding (AUB-A)-Pathogenesis, diagnosis, and management. *Best Pract Res Clin Obstet Gynaecol.* 2017;40:68-81.
DOI: [10.1016/j.bpobgyn.2016.09.006](https://doi.org/10.1016/j.bpobgyn.2016.09.006)
 13. Treloar AE. Menstrual cyclicity and the pre-menopause. *Maturitas.* 1981;3(3-4):249-64.
DOI: [10.1016/0378-5122\(81\)90032-3](https://doi.org/10.1016/0378-5122(81)90032-3).
PMID: 7334935.
 14. Epstein E, Ramirez A, Skoog L, Valentin L. Transvaginal sonography, saline contrast sonohysterography, and hysteroscopy for the investigation of women with postmenopausal bleeding and endometrium > 5 mm. *Ultrasound Obstet Gynecol.* 2001;18(2):157-62.
DOI: [10.1046/j.1469-0705.2001.00472.x](https://doi.org/10.1046/j.1469-0705.2001.00472.x)
 15. Maymon R, Herman A, Ariely S, Dreazen E, Buckovsky I, Weinraub Z. Three-dimensional vaginal sonography in obstetrics and gynecology. *Hum Reprod Update.* 2000;6(5):475-84.
DOI: [10.1093/humupd/6.5.475](https://doi.org/10.1093/humupd/6.5.475)
 16. Wamsteker K, Emanuel MH, de Kruif JH. Transcervical hysteroscopic resection of submucous fibroids for abnormal uterine bleeding: results regarding the degree of intramural extension. *Obstet Gynecol.* 1993 Nov;82(5):736-40. PMID: 8414318
 17. Van den Bosch T, Valentin L, Van Schoubroeck D, Luts J, Bignardi T, Condous G, et al. Detection of intracavitary uterine pathology using offline analysis of three-dimensional ultrasound volumes: interobserver agreement and diagnostic accuracy. *Ultrasound Obstet Gynecol.* 2012;40(4):459-63.
DOI: [10.1002/uog.11163](https://doi.org/10.1002/uog.11163)
 18. Haemila FA, Youssef D, Hassan M, Soliman A, Mossad M. A prospective comparative study of 3-D ultrasonography and hysteroscopy in detecting uterine lesions in premenopausal bleeding. *Middle East Fertil Soc J.* 2005;10(3):238-43
 19. Ayad WA, Mahmoud MS. Comparative study between three-dimensional ultrasonography and office hysteroscopy in women with abnormal uterine bleeding. *Int J Basic Appl Sci.* 2017;7(1):39-42
 20. Exacoustos C, Manganaro L, Zupi E. Imaging for the evaluation of endometriosis and adenomyosis. *Best Pract Res Clin Obstet Gynaecol.* 2014 Jul;28(5):655-81. Epub 2014 May 2.
DOI: [10.1016/j.bpobgyn.2014.04.010](https://doi.org/10.1016/j.bpobgyn.2014.04.010).
PMID: 24861247