

A RARE CASE OF GASTRIC ECTOPIC PANCREATIC TISSUE - AN INCIDENTAL FINDING

Rajat Kumar Shah^{1*}, Mrinalini Singh², Dipesh Mandal Dhanuk³

Affiliation

1. Intern / Department of Pathology, Birat Medical College and Teaching Hospital, Nepal
2. Associate Professor/ Department of Pathology, Birat Medical College and Teaching, Nepal
3. Medical Officer, Birat Medical College and Teaching, Nepal

ARTICLE INFO

Received : 21 November, 2022

Accepted : 09 May, 2023

Published : 10 November, 2023

© Authors retain copyright and grant the journal right of first publication with the work simultaneously licensed under Creative Commons Attribution License CC - BY 4.0 that allows others to share the work with an acknowledgment of the work's authorship and initial publication in this journal.



CR 54

DOI: <https://doi.org/10.3126/bjhs.v8i2.59861>

Corresponding Author

Dr Rajat Kumar Shah
Intern

Department of Pathology
Birat Medical College & Teaching Hospital, Nepal

Email : rajatshah2013@gmail.com

ORCID ID: <https://orcid.org/0000-0003-4674-370X>

Citation

A Rare Case of Gastric Ectopic Pancreatic Tissue - An Incidental finding.
Rajat Kumar Shah, Mrinalini Singh, Dipesh Mandal Dhanuk.
BJHS 2023;8(2)21. 2062-2065.

ABSTRACT

Ectopic pancreas is an infrequent lesion presenting as a nodule or a submucosal mass in the gastrointestinal tract. Depending upon its anatomical location, it can cause clinical symptoms like abdominal pain, intussusceptions, or obstruction, or it can remain clinically silent. Though radiologic diagnostic tools are available, the preoperative diagnosis is tough and is seldom made. We report a case of a 61-year-old male with the chief complaint of pain in the abdomen for 15 days. Advanced diagnostic tools like Contrast enhanced CT scan can characterise the submucosal mass in the stomach and able to confirm the nature of the lesion, whether it was non-neoplastic, benign, or malignant. Therefore, surgical excision was done. The final confirmatory diagnosis of ectopic pancreas in the stomach was made on histopathologic examination.

KEY WORDS

Ectopic Pancreas, Stomach, Submucosal Mass

INTRODUCTION

Ectopic pancreas tissue is a rare entity. Ectopic pancreas is the presence of normal pancreatic tissue outside the pancreas without any vascular or anatomic connection with the main pancreatic gland. Other terms in the literature for ectopic pancreas include pancreatic rest, heterotopic, aberrant pancreas, or pancreatic choristoma. This anomaly is often an incidental finding during a laparotomy or autopsy. Most of the patients with ectopic pancreas are asymptomatic. Autopsy studies reveal a prevalence of ectopic pancreas of 0.5% to 13.7%, with the most commonly occurring sites in the GIT being reported as the stomach, duodenum, and jejunum^{1,2}. Rarely, ectopic pancreatic tissue is also reported in distant sites like the lungs, fallopian tubes, and umbilicus³.

The malignant transformation of this tissue is very rare. But it can be confirmed on HPE. We report a case of a 61-year-old male with a symptom of pain in the upper abdomen and a clinical diagnosis of submucosal mass in the stomach, which was found to be ectopic pancreatic tissue after histopathological examination.

CASE REPORT

A 61-year-old male presented at the surgery OPD of Birat Medical College and Teaching Hospital (BMCTH) with complaints of pain in the right upper abdomen for 15 days. There was no other significant history. His systemic examination and vitals were within normal limits. A CT scan of the abdomen revealed a submucosal soft tissue mass in the stomach measuring 3x3 cm, suggesting leiomyoma or GIST. Esophagogastric duodenoscopy revealed similar findings in the cardia of the stomach, along with features of diffuse corpus congestive gastritis.

Laparoscopic assisted and wedge resection of the tumour showed a 3x3 cm well-circumscribed soft to firm mass present in a lesser curvature of the cardia of the stomach region subserosal in position with no ulceration. A sample was sent for histopathological examination, where it was found to have a subserosal growth in the stomach measuring 3x2x1.5 cm (Figure 1). The cut section was grey or brown in color. Attachment to the normal gastric mucosa was also identified. The microscopic examination of the mass revealed the presence of pancreatic duct acini and connective tissue in the gastric muscularis propria and serosal layer. There was a predominance of benign proliferation of the exocrine portion of the pancreas only (Figure 2). The overlying gastric mucosa and submucosa show the presence of gastric fundic glands, which were histologically unremarkable and showed few chronic inflammatory cells infiltrated (Figure 3).

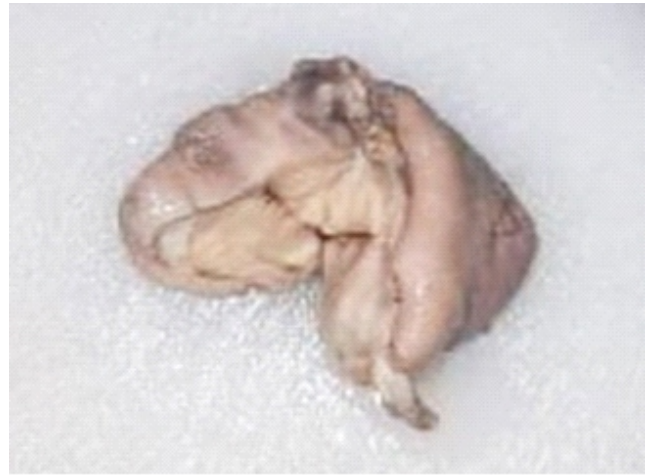

Figure 1: Gross photo of gastric tissue with grey brown mass

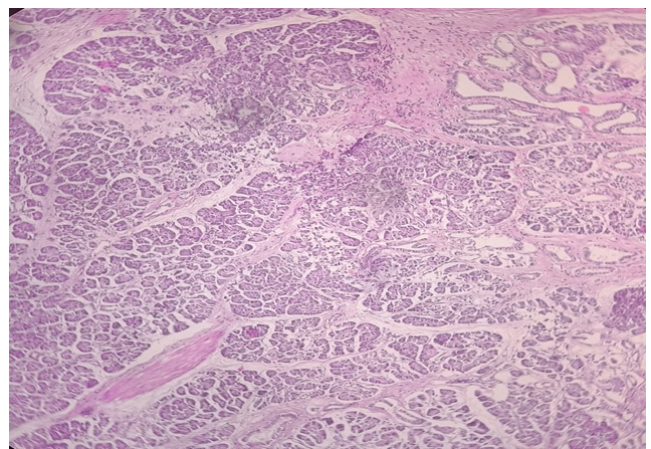


Figure 2: H & E stain showing pancreatic ducts, acini and intervening stroma

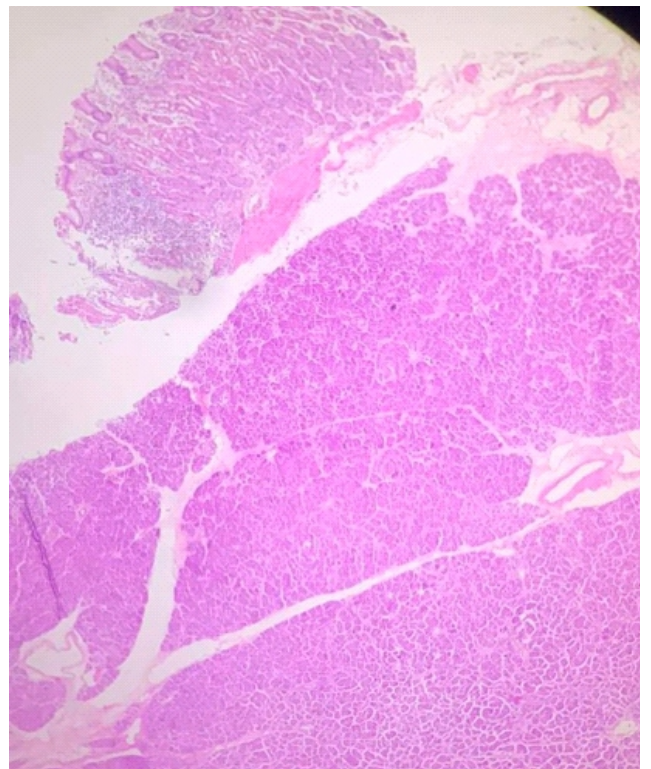


Figure 3: H & E stain showing proliferation of Pancreatic acini and ducts below normal gastric mucosa and submucosa

DISCUSSION

From the literature, it is known that ectopic pancreas is usually asymptomatic in nature, but few people can show symptoms like abdominal pain, diarrhoea, and weight loss. Among these symptoms, abdominal pain is the most common.⁴ Our patient also complained of pain in the abdomen and epigastric region for 15 days. The most common location of ectopic pancreatic tissue is the gastrointestinal tract.^{5,6} The commonest location in the gastrointestinal tract is the stomach. Our patient also showed ectopic pancreatic tissue in the pre-pyloric region of the stomach, involving the submuscular layer. It is challenging to differentiate ectopic pancreas from other submucosal tumours of the gastrointestinal tract, like leiomyoma, lipoma, and gastrointestinal stromal tumours. A similar pattern has been observed in our patient. Many tests, like ultrasound, CT scan, and endoscopy, were done to search for the cause of abdominal pain. These tests were not specific; they only revealed a mass in the stomach. Though endoscopy and other radiologic tests revealed a submucosal mass, the exact nature of the mass was only confirmed after surgical excision of biopsy tissue. Similarly, other studies have also suggested that radiologic and endoscopic studies are not sensitive enough to make a confirmatory diagnosis of ectopic pancreas. A histopathology examination is a must for the confirmation of the diagnosis.⁷

The ectopic pancreas can present as many types as possible. They can either show acini, ducts, or islet cells, just like normal pancreas. Or they can just show exocrine pancreatic tissue or islet cells only. Our patient showed exocrine pancreatic tissue only. According to the literature, we know that ectopic pancreas is often an incidental finding, but it has the potential to develop various complications like pancreatitis, calcification, cyst formation, and malignant transformation in a rare case.⁸ For clinical purposes, it is very important to keep in mind that the diseases that occur in the true pancreas can also develop in the ectopic pancreas.⁹

CONCLUSION

Ectopic pancreas is a rare entity, but the surgeons and the radiologist should keep this in mind as a differential diagnosis of submucosal gastric lesions. In symptomatic cases, surgical resections of the tissue are indicated.⁹

PATIENT CONSENT

Written informed consent was not obtained from the patient for the publication of this case report, but the patient's identity has not been revealed.

CONFLICT OF INTEREST

None

REFERENCES

1. Rezvani M, Menias C, Sandrasegaran K, Olpin JD, Elsayes KM, Shaaban AM. Heterotopic Pancreas: Histopathologic Features, Imaging Findings, and Complications. *Radiographics*. 2017 Mar-Apr;37(2):484-499. doi: 10.1148/rg.2017160091. PMID: 28287935
2. BROMBERG, Sansom Henrique et al. Pancreatic heterotopias: clinicopathological analysis of 18 patients. *Rev. Col. Bras. Cir.* [online]. 2010, vol.37, n.6 [cited 2022-06-22], pp.413-419. Available from: <http://old.scielo.br/scielo.php?script=sci_arttext&pid=S0100-69912010000600007&lng=en&nrm=iso>. ISSN 0100-6991. <https://doi.org/10.1590/S0100-69912010000600007>.
3. Tanaka K, Tsunoda T, Eto T, Yamada M, Tajima Y, Shimogama H, Yamaguchi T, Matsuo S, Izawa K. Diagnosis and management of heterotopic pancreas. *Int Surg*. 1993 Jan-Mar;78(1):32-5. PMID: 8473080.
4. Straatman, J., Meester, R.J., Grieken, N.C.T.v. et al. Clinical picture: multiple sites of ectopic pancreatic tissue. *SpringerPlus* 4, 293 (2015). <https://doi.org/10.1186/s40064-015-1072-x>.
5. DeBord JR, Majarakis JD, Nyhus LM. An unusual case of heterotopic pancreas of the stomach. *Am J Surg*. 1981 Feb;141(2):269-73. doi: 10.1016/0002-9610(81)90172-0. PMID: 7457747.
6. Wlaz J, Madro A, Kazmierak W, Celinski K, Slomka M. Pancreatic and gastric heterotopy in the gastrointestinal tract. *Postepy Hig Med Dosw (Online)* 2014;68:1069–1075. doi: 10.5604/17322693.1119720.
7. Mickuniene, R., Stundiene, I., Jucaitis, T. et al. A case of ectopic pancreas in the ileum presenting as obscure gastrointestinal bleeding and abdominal pain. *BMC Gastroenterol* 19, 57 (2019). <https://doi.org/10.1186/s12876-019-0971-7>
8. Bau, P. C., A. Lucchese, and F. B. Hohmann. "Ectopic pancreatic tissue in a Gallbladder. *SOJ Surgery* 3 (3): 1-2." Ectopic pancreatic tissue in a Gallbladder (2016). <http://dx.doi.org/10.15226/2376-4570/3/3/0013>
9. Betzler, A., Mees, S.T., Pump, J. et al. Clinical impact of duodenal pancreatic heterotopia – Is there a need for surgical treatment?. *BMC Surg* 17, 53 (2017). <https://doi.org/10.1186/s12893-017-0250-x>

