

LARGE RADICULAR CYST DISFIGURING THE MIDLINE FACE; A CASE REPORT

Brihaspati Sigdel^{1*}, Kuseshwar Sah², Bhima Neupane³

Affiliation

1. Professor, Department of Otolaryngology and Head and Neck Surgery, Gandaki Medical College and Teaching Hospital, Pokhara, Nepal.
2. PG Resident, III year, Department of Otorhinolaryngology, Gandaki Medical College and Teaching Hospital, Pokhara, Nepal.
3. Lecturer, Department of Anatomy, Manipal College of Medical Sciences, Pokhara, Nepal

ARTICLE INFO

Received : 17 February, 2022

Accepted : 16 August, 2022

Published : 15 November, 2022

© Authors retain copyright and grant the journal right of first publication with the work simultaneously licensed under Creative Commons Attribution License CC - BY 4.0 that allows others to share the work with an acknowledgment of the work's authorship and initial publication in this journal.



CR 48

DOI: <https://doi.org/10.3126/bjhs.v7i2.49309>

* Corresponding Author

Dr. Brihaspati Sigdel

Professor

Department of Otolaryngology and Head and Neck Surgery
Gandaki Medical College and Teaching Hospital, Pokhara, Nepal

Email: brihassig1@gmail.com

ORCID: <https://orcid.org/0000-0002-8546-6699>

Citation

Large Radicular cyst disfiguring the midline face; a case report. Brihaspati Sigdel, Kuseshwar Sah, Bhima Neupane. BJHS 2022;7(2):1826-1829.

ABSTRACT

A radicular cyst is an inflammatory odontogenic cyst of the jaw commonly found at the apices of the tooth of the anterior maxilla. It develops as a sequelae of untreated dental caries with pulp necrosis and periapical infection. Different treatment includes surgical endodontic treatment, extraction of the involving tooth, marsupialization, and enucleation with primary closure followed by rehabilitation. We presented a case of a huge midline radicular cyst of a 52 years lady who presented with increasing size of swelling at the midline of the upper lip region which makes patients ugly for 25 years. It leads to the mass effect at the philtrum of the upper labium at midlines leads to elevation and ugly looking face making her socially embarrassing. Endoscope-assisted complete excision was performed via midline mini visor incision and with no evidence of recurrence found at three-month follow-up.

KEYWORDS

Endoscopic-assisted excision, Facial disfigurement, Radicular Cyst.



INTRODUCTION

A radicular cyst (RC) is an inflammatory odontogenic cyst of the jaw that is associated with endodontic tooth involvement (WHO classification). Radicular cysts account for more than 60% of all jaw cysts.¹ It develops as sequelae of the untreated dental caries with pulp necrosis and periapical infection.² Periapical lesions originating from the infected pulp are the most common pathologic sequelae of the periapical alveolar bone of the jaw. The infectious source causes inflammation and necrosis of the dental pulp, which eventually spreads to the peri-radicular tissue. The chronic inflammatory condition stimulates the epithelial rests of Malassezia in the peri-radicular tissue, and the epithelial cells then proliferate and develop into cystic lesions.³

RC arises to control the infection as a low-intensity chronic stimulus triggered by bacteria and their products provide conditions to the organism, confining the aggression to the periapical region. During these events of defense, different cells produce cytokines, mainly interleukin (IL-1), IL-6, and tumor necrosis factor-alpha (TNF- α), which are involved in this immunoinflammatory response and play a role in bone resorption and in the stimulation of mitogenesis.⁴ In addition, foreign body-type material and other morphological findings might be observed in RCs, either potentiating the inflammatory process or as a result of the defensive mechanism of the organism itself.

The most common clinical symptom associated with cyst presentation is painless swelling. The most common location of radicular cysts is in the upper jaw, in the premolar region.

CASE PRESENTATION

A 52-year-old lady presented at the ENT Department with a complaint of painless swelling over the mid nasolabial region for 25 years which was slowly progressive in size. Now face was protruded just below the nose and the upper lip was lifted up. The swollen area was palpated intraorally and it was firm and non-tender and was approximately 4 × 4.5 cm in dimension. (Figure.1A) She had a mild nasal obstruction in the bilateral nostril externally. She feels socially embarrassed and most of the time she used to cover her lower half of the face. She didn't have any other significant past medical history. She was a chronic smoker for 30 years, 40 pack years. On facial examination, the swelling was filling the upper labial region and obstructing the nostril. Oral cavity examination revealed the bulging over the upper vestibule at the midline. Anterior rhinoscopy examination showed the elevation of the anterior floor of the left nostril and boggy swelling of the left inferior turbinate. Her blood investigation was within normal limits. Nasal endoscopy examination confirms the anterior rhinoscopy finding(Figure.2). The CT scan shows the well-defined mass with homogenous density at the midline between the crest of the maxilla and hard palate anteriorly (Figure.3).The patient underwent endoscopically assisted excision of the mass via intra-oral route at upper midline mini visor incision(Figure 4A). The flap was elevated above and below. The cyst was separated from the flap. The cyst was decompressed so that it was easy to separate from the

maxilla. After a cystic rupture, a brownish viscous fluid came out. The endoscope was used to visualize the entire dissection and separation of the cyst from the bony wall(Figure. 4B).It was completely removed and cyst was found 4*4.5 cm dimension (Figure. 5A&B).As there was also deviated nasal septum of the patient, endoscopic septoplasty was performed. The nose was packed with a merocel. The dead space made after cyst removal was packed with antibiotics impregnated ribbon gauze and removed at 5th POD.The patient was discharged at the 7th POD without any complaint(Figure. 1B).The postoperative healing phase remained uneventful. Histopathology revealed cystic structure lined by stratified squamous epithelium with granulation tissue and stroma containing dense acute and chronic inflammatory cells (Figure.6&7). On one month follow-up, the patient was quite pleased and satisfied, and the cyst had not recurred.

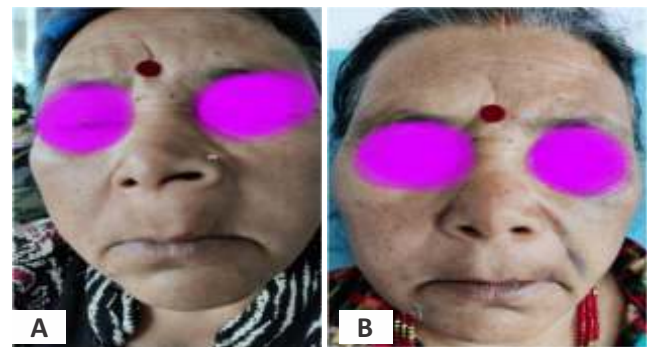

Figure 1: A. upper labial region swelling preoperatively
B. postoperative removal of swelling

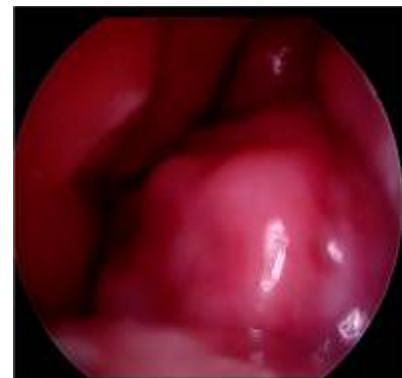

Figure 2: Showing elevation of left nasal cavity floor on endoscopic examination.

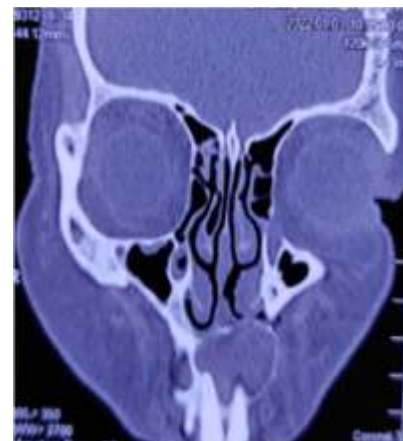

Figure 3: CT paranasal sinus of radicular cyst

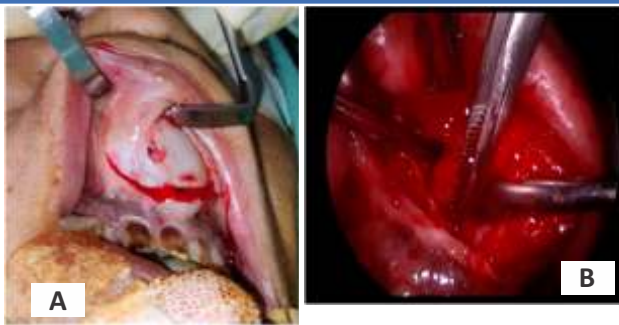

Figure 4: A. Sublabial mini-visor incision and flap elevation B. endoscopic cyst dissection.

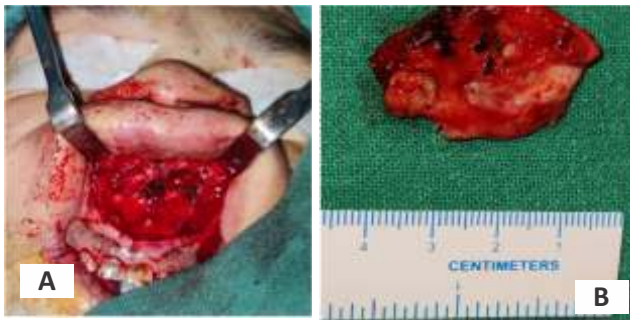

Figure 5: A. Intraoperative cystic cavity and B. Excised radicular cyst

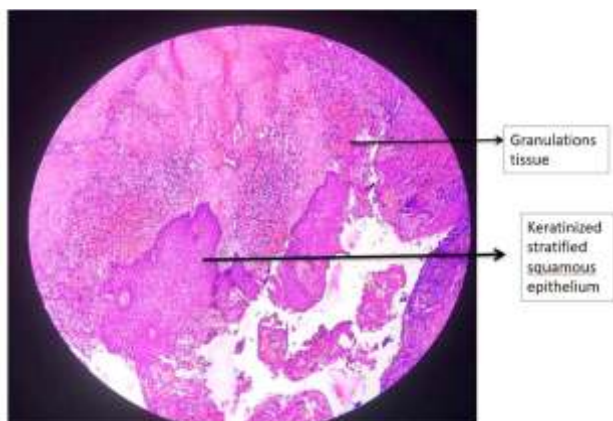


Figure 6: Histopathology showing keratinised stratified squamous epithelium.

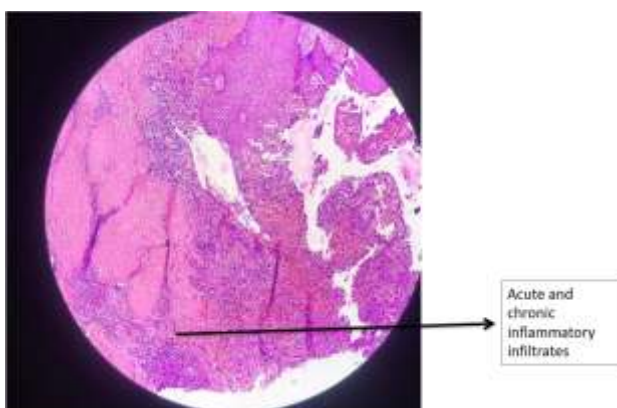


Figure 7: Histopathology slide showing acute and chronic inflammatory infiltrates.

DISCUSSION

The radicular cyst has been classified as inflammatory, because in the majority of cases it is a consequence of pulpal necrosis following caries, with an associated periapical inflammatory response.³ These cysts can occur in the periapical region of any teeth, at any age but are seldom seen associated with the primary dentition. Radicular cysts are more common between the third and fifth decades of life, more common in males than females, and more frequently detected in the front maxilla than other sections of the mouth.⁵ The findings in our instance are consistent with those found in female patients in their fifth decade who arrive with a lesion in the anterior maxillary region. The patient's visit is generally triggered by cosmetic concerns. A growing cyst is causing our patient social embarrassment due to a significant midline facial abnormality, for which she came for excision.

The pathogenesis of radicular cysts has been described as comprising of three distinct phases: the phase of initiation, the phase of cyst formation, and the phase of enlargement.⁶ The initial swellings of these radicular cysts are usually bony hard, but as they increase in size, the covering bone may become very thin despite initial subperiosteal bone deposition. Finally, when bone resorption progresses, the swellings become 'springy' or 'eggshell cracking'.^{7,8} The teeth that are related to it are always non vital and may have discoloration. Although there is usually no root resorption in the related teeth, there may be smooth resorption of the root apices. Cyst cavities may be filled with brown or straw-colored fluid when cysts are intact, and cyst fluid may have a dazzling gold look when light passes through it.

Histopathologically, RCs consists of a cavity lined by stratified squamous epithelium exhibiting spongiosis and/or exocytosis and are delimited by a fibrous wall containing a predominantly chronic inflammatory infiltrate.⁹ Rushton bodies are seen within the cystic epithelium of radicular cysts, with a reported incidence of about 10%.¹⁰ Since rushton bodies are commonly seen inside the epithelial lining of various odontogenic cysts, such as radicular cysts, dentigerous cysts, and odontogenic keratocysts, they are thought to be a secretory product of odontogenic epithelium.

The early stage of radicular cyst formation usually shows a proliferative epithelial lining, associated with an intense inflammatory infiltrate and marked intercellular edema, while the epithelium may show an arcading pattern penetrating into the underlying capsule.¹¹ The epithelium may also show spongiosis and be permeated by neutrophils. Almost all radicular cyst is lined by non-keratinized stratified squamous epithelium. Keratinization only occurs in about 2% of instances, and orthokeratinization is more common than parakeratinization.

Radiographically, RC is characterized by a round or oval, uni or multilocular, well-circumscribed radiolucency delimited by a radiopaque line, attached to the root of a tooth.¹² Bone expansion was more significant in the maxilla than in the mandible.¹³ RC can result in cortical expansion, permanent tooth buds being displaced, and producing root dilacerations.

Loss of the necrotic tooth's lamina dura, a history of dental caries, endodontic therapy, or trauma is other symptoms that can help with diagnosis. Caries manifest themselves in the related tooth's enamel/crown erosion.

Several treatment options are available for a radicular cyst such as surgical endodontic treatment, extraction of the offending tooth, enucleation with primary closure, and marsupialization followed by enucleation.^{2,14-16} In this case, endoscopic assisted surgical enucleation was done and was performed uneventfully.

CONCLUSION

The radicular cyst is the most common inflammatory jaw cystic lesion that occurs in infected and necrotic teeth pulps

at the midline of the maxilla. It usually occurs in the 5th decade of life. It grows anteriorly and elevates the upper lip. Our patients become socially embarrassed due to ugly faces. This case illustrates the successful management of a radicular cyst with endoscope-assisted enucleation and endodontic treatment.

PATIENT CONSENT

Written informed consent was obtained from the patient for publication of this case report and accompanying images.

CONFLICT OF INTEREST

None

REFERENCES

1. Mortazavi H, Baharvand M, Safi Y, Behnaz M. Common conditions associated with displacement of the inferior alveolar nerve canal: A radiographic diagnostic aid. *Imaging Sci Dent.* 2019 Jun;49(2):79-86. DOI: 10.5624/isd.2019.49.2.79. PMID: 31281784; PMCID: PMC6597375.
2. Penumatsa NV, Nallanchakravarthy S, Muppa R, Dandampally A, Panthula P. Conservative approach in the management of radicular cyst in a child: Case report. *Case reports in dentistry.* 2013 Feb 17;2013. <https://doi.org/10.1155/2013/123148>
3. Narula H, Ahuja B, Yeluri R, Baliga S, Munshi AK. Conservative non-surgical management of an infected radicular cyst. *Contemp Clin Dent.* 2011 Oct;2(4):368-71. DOI: 10.4103/0976-237X.91806. PMID: 22346170.
4. Prso IB, Kocjan W, Simić H, Brumini G, Pezelj-Ribarić S, Borčić J et al. Tumor necrosis factor- α and interleukin 6 in human periapical lesions. *Mediators Inflamm.* 2007;2007:38210. DOI: 10.1155/2007/38210. PMID: 17497030.
5. Holla VA, Chatra L, Shenai P, Rao PK, Veena K, Prabhu RV. Bilateral inflammatory cysts of the jaw: report of an unusual case. *Imaging Sci Dent.* 2012 Jun;42(2):105-9. DOI: 10.5624/isd.2012.42.2.105. Epub 2012 Jun 25. PMID: 22783480; PMCID: PMC3389048.
6. Colić S, Jurisić M, Jurisić V. [Pathophysiological mechanism of the developing radicular cyst of the jaw]. *Acta Chir Iugosl.* 2008;55(1):87-92. Serbian. DOI: 10.2298/aci0801087c. PMID: 18510067.
7. Lall AB, Arora R. Coincidental Overlapping Cystic Pathological Changes: A Case against Marsupialisation. *J Maxillofac Oral Surg.* 2013 Jun;12(2):214-7. DOI: 10.1007/s12663-011-0215-z. Epub 2011 Apr 20. PMID: 24431842; PMCID: PMC3681994.
8. Kolari V, Rao HTA, Thomas T. Maxillary, and mandibular unusually large radicular cyst: A rare case report. *Natl J Maxillofac Surg.* 2019 Jul-Dec;10(2):270-273. DOI: 10.4103/njms.NJMS_6_18. Epub 2019 Nov 12. PMID: 31798272; PMCID: PMC6883872.
9. Nair PN, Pajarola G, Luder HU. Ciliated epithelium-lined radicular cysts. *Oral Surg Oral Med Oral Pathol Oral Radiol Endod.* 2002 Oct;94(4):485-93. DOI: 10.1067/moe.2002.123862. PMID: 12374925.
10. Babburi S, Rudraraju AR, V A, P S. Rushton bodies: an update. *J Clin Diagn Res.* 2015 Feb;9(2):ZE01-3. DOI: 10.7860/JCDR/2015/10990.5533. Epub 2015 Feb 1. PMID: 25859536; PMCID: PMC4378819.
11. Robinson RA. Diagnosing the most common odontogenic cystic and osseous lesions of the jaws for the practicing pathologist. *Modern Pathology.* 2017 Jan;30(1):S96-103. <https://doi.org/10.1038/modpathol.2016.191>
12. Scholl RJ, Kellett HM, Neumann DP, Lurie AG. Cysts and cystic lesions of the mandible: clinical and radiologic-histopathologic review. *Radiographics.* 1999 Sep;19(5):1107-24. <https://doi.org/10.1148/radiographics.19.5.g99se021107>
13. Sukegawa S, Matsuzaki H, Katase N, Kawai H, Kanno T, Asaumi JI, Furuki Y. Morphological characteristics of radicular cysts using computed tomography. *Odontology.* 2020 Jan;108(1):74-83. DOI: 10.1007/s10266-019-00443-5. Epub 2019 Jul 10. PMID: 31292814.
14. Kadam NS, Ataide Ide N, Raghava P, Fernandes M, Hede R. Management of large radicular cyst by conservative surgical approach: a case report. *J Clin Diagn Res.* 2014 Feb;8(2):239-41. DOI: 10.7860/JCDR/2014/5763.4069. Epub 2014 Feb 3. PMID: 24701544; PMCID: PMC3972573.
15. Balaji Tandri S. Management of infected radicular cyst by surgical decompression. *J Conserv Dent.* 2010 Jul;13(3):159-61. DOI: 10.4103/0972-0707.71651. PMID: 21116394; PMCID: PMC2980615.
16. de Souza Batista, Victor Eduardo DDS, MSc; de Souza Batista, Fábio Roberto DDS; Silva, Marcellino Moço DDS, MSc Treatment of a Large Radicular Cyst, *Journal of Craniofacial Surgery*: July 2015 - Volume 26 - Issue 5 - p454-e455 DOI: 10.1097/SCS.0000000000001635

