

SINGLE-INCISION LAPAROSCOPIC APPROACH, THE NEW TREND IN THE MINIMAL INVASIVE SURGERY - AN OVERVIEW, CURRENT STATUS AND CORRELATION WITH OUR EXPERIENCE IN NOBEL MEDICAL COLLEGE TEACHING HOSPITAL

Sulaimankulov R^{1*}, Jolochieva G², Paudel B³

Affiliation

1. Department of General Surgery, Nobel Medical College Teaching Hospital, Biratnagar, Nepal
2. Department of Obstetrics & Gynaecology, Nobel Medical College Teaching Hospital, Biratnagar, Nepal
3. Department of Anaesthesiology, Critical Care & Pain Management, Nobel Medical College Teaching Hospital, Biratnagar, Nepal

ARTICLE INFO

Received : 09 July, 2020

Accepted : 01 September, 2020

Published : 05 October, 2020

© Authors retain copyright and grant the journal right of first publication with the work simultaneously licensed under Creative Commons Attribution License CC - BY 4.0 that allows others to share the work with an acknowledgment of the work's authorship and initial publication in this journal.



ORA 183

DOI: <https://doi.org/10.3126/bjhs.v5i2.31382>

* Corresponding Author

Dr. Ruslan Sulaimankulov

Department of General Surgery

Nobel Medical Teaching Hospital

Email ID: ruslansulaimankulov@gmail.com

ORCID ID: <https://orcid.org/0000-0002-1196-808X>

Citation

Sulaimankulov R, Jolochieva G, Paudel B. Single-Incision Laparoscopic Approach, The New Trend in The Minimal Invasive Surgery - An Overview, Current Status and Correlation with our Experience in Nobel Medical College Teaching Hospital. BJHS 2020;5(2)12: 1060-1064.

ABSTRACT

Introduction

The major purpose of the Minimal Access Surgery is to reduce the number and size of scars, decrease pain and rate of infections, reduce complications, and improve cosmetic effect. In order to achieve scarless surgery there was a development of the Natural Orifice Transluminal Endoscopic Surgery (NOTS), which did not gain popularity and induced growing interest to single-incision laparoscopy as a modern technique with minimal visible scars.

Objectives

The objective of this study is to correlate worldwide experience with outcomes of Single-Incision Laparoscopic Surgery (SILS) in our institute.

Methodology

A retrospective analysis was done for 9141 patients who underwent Laparo-endoscopic single-site surgery between the year 2011-2020 years (AD). The type of surgery, gender, age, operative time, conversion and complication rate were reported.

Results

Laparo-endoscopic single-site surgery was performed for 9141 patients, with a mean age of 46.3 years (range=2.5-90). Out of 9141 patients included in this study, 8668 patients underwent Cholecystectomy, 232 underwent simultaneous, 161 appendectomy, 54 ovarian cystectomy, 11 underwent myomectomy, 8 diagnostic laparoscopy and 7 cases of salpingo-oophorectomy. The mean operating time was 19.5 minutes (range=4-35 min). In our study complicated cases were 0.996%, conversion done for 0.1% and mortality was 0.02%.

Conclusion

The advantages of single access surgery include better cosmetic effect, reduced bleeding, infections, herniations and hospital stay.

KEY WORDS

Laparoscopic surgical procedure; natural orifice transluminal endoscopic surgery; minimal access surgical procedures; minimally invasive surgery; SILS; NOTES.



INTRODUCTION

The first laparoscopic cholecystectomy was performed by Muhe in 1985, and publicly reported by Mouret, Perissat and Dubois in 1987 and 1988.^{1,2} Laparoscopic surgery has now become the standard procedure for numerous abdominal surgical pathologies. Laparoscopic intervention boosts up the possibilities of minimal invasive surgery, thus it has become the method of choice for treating the major part of surgical abdomen pathologies. Single-incision laparoscopic method is a new modality in the field of minimal access surgery which leads to further reduction of the negative outcomes of standard laparoscopy. Single-incision laparoscopic surgery is an alternative to standard multiport laparoscopy. In order to achieve scarless surgery there was a development of the NOTES, however, for various reasons it did not gain popularity. The lack of success of NOTES induced growing interest to single-incision laparoscopy as a modern technique with minimal visible scars.

NOTES interventions are “hollow visceral transperitoneal”, which implies the transgastric, transoesophageal, transcolonic, transvesical or “squamous conduit intraperitoneal” transvaginal or transanal access to peritoneum, which is conducted through perforation of a hollow viscus. Hollow visceral transperitoneal access requires flexible interventional equipments. Squamous conduit intraperitoneal access is performed with standard rigid laparoscopic optics and instruments. The concept of SILS was established by the father of modern thoracoscopic surgery, Dr. Raimund Wittmoser.

Many equipment manufacturers produce single-incision laparoscopic surgery devices, which are disposable, except for two reusable ones - X-PORT (KARL STORZ, Germany) and ENDOCONE (Institute of medical science and technology, Dundee). The surgeon is able to use three instruments and an optic at once during the operation. Due to the worked out and updated proximally deviated curved coaxial articulating tools, the means of SILS have improved significantly.

The SILS procedure is used for a wide range of laparoscopic operations like colorectal resections, bariatric operations, nephrectomies, cholecystectomy and splenectomy.

In its early history, single-port surgery was labeled with a different term in every report, such as NOTUS (natural orifice transumbilical surgery) and E-NOTES (embryonic natural orifice transumbilical endoscopic surgery), R-NOTES (Robotic-assisted natural orifice transumbilical endoscopic surgery), U-NOTES (Umbilical natural orifice transluminal endoscopic surgery), LESS (Laparo-endoscopic single-site surgery), SIMPLE (single-incision multi-port laparo-endoscopic surgery), SPA (single-port access), SILS (single-incision laparoscopic surgery), OPUS (one-port umbilical surgery), SLaPP (single laparoscopic port procedure).^{3,4} To unify all these options in July 2008 LESSCAR - (Laparo-Endoscopic Single Site Surgery Consortium for Assessment and Research), suggested LESS Surgery as a term for all the procedures that used a single site for access.

METHODOLOGY

Single incision laparoscopic surgery allows for all procedures to be performed with multiport through one incision at umbilicus. There is a variety of hand-instruments available nowadays, including curved, coaxial and articulating ones, which allows greater freedom of intra-abdominal operations. A multidisciplinary consortium in 2005 proposed the Laparo-endoscopic single-site surgery (LESS) as a term for single-incision laparoscopic surgery. These types of surgeries are currently associated with access difficulties, lack of operative space and inadequate mobility of instruments. At the same time, LESS offers an advantage to surgeons, giving them familiar field of view and instruments similar to those used in multiport laparoscopy. LESS remains an advanced special technique used successfully in many hospitals. In minimal access surgery range it is currently taking the place between standard laparoscopy and NOTES.

Between 2011 and 2020 years (AD), 9141 cases underwent LESS in the Nobel Medical College Teaching Hospital, General Surgery department, Laparoscopy Unit. The first LESS procedure performed at our institute was done on 2nd Dec. 2011 by our team.

The following factors are reported: age, gender, operation duration, conversion rate, postoperative complication and mortality.

Inclusion criteria: The consenting patients of all ages and genders with symptomatic cholelithiasis planned for laparoscopic cholecystectomy.

Exclusion criteria: Any patients with contraindication to laparoscopic procedure such as pregnancy, bleeding disorder, critical conditions, chronic cardiovascular, pulmonary, liver, kidney diseases. Additionally patients having choledocholithiasis, cholangitis, biliary fistula and surgical jaundice were also excluded.

Statistical analysis was performed using Fisher test, Chi-square test and Mann-Whitney U test based on the distribution of the variables (MEDCALC software version 19.3, MedCalc Software Ltd, Belgium). Statistical significance was considered when *P values* < 0.05.

RESULTS

In Nobel Medical College we had done total 9141 LESS surgeries, included 8668 (94.8%) cholecystectomy, concomitantly double surgeries 232 (2.54%), 161 (1.8%) appendectomy, ovarian cystectomy 54 (0.6%), myomectomy 11 (0.12%), diagnostic laparoscopy 8 (0.09%) and 7 cases of salpingo-oophorectomy (0.08%) [Chart 1].

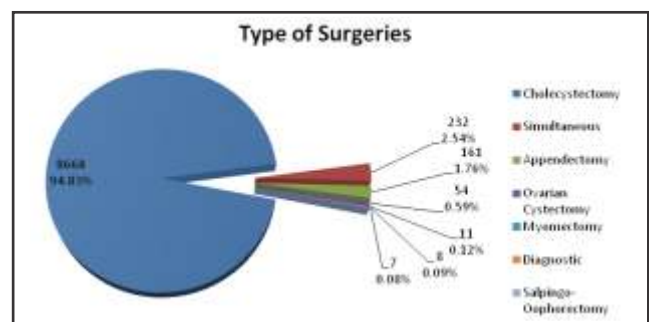


Chart 1: Pie diagram showing type of surgeries

In our study among 9141 series, complications were seen in 91 cases (0.996%), conversion in 9 patients (0.1%) and mortality was 2 (0.02%). Age of patients was minimal 2.5 and maximal 90 years old. The mean operating time was 19.5 minutes (range=4-35 min).

In LESS cholecystectomy gender rate was 1:3.6, where female were 6799 (78.4%) and male 1869 (21.6%). Appendectomy – 72 female (44.7%) and 89 male (55.3%), simultaneous surgery – 197 (84.9%) and 35 (15.1%) respectively.

Different type of simultaneous surgeries done by our team showed in below diagram. [Chart 2].

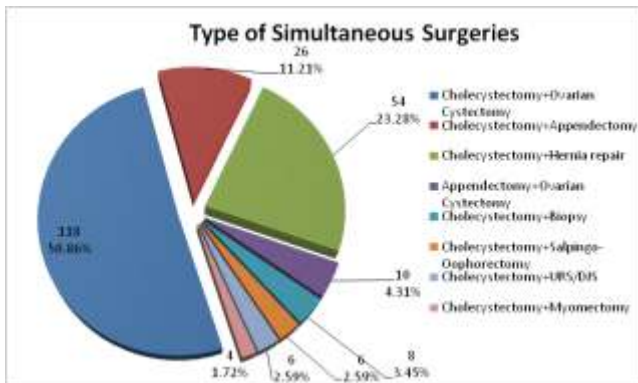


Chart 2: Pie diagram showing range of simultaneous surgeries.

The mean operative time is correlated both with the particularities of the case and the learning curve, as has been advocated by several studies. After huge number of operation our experience permitted to do fastest LESS cholecystectomy in Nepal and most probably all over the world. At 7th November 2019, 49 years old female patient, resident of Jhapa district, Nepal with diagnose of symptomatic cholelithiasis underwent LESS cholecystectomy which was successfully performed within 4 and half minute. Her postoperative period was smooth and patient was discharged at 2nd postoperative day. (Video: <https://youtu.be/-TXIbuhZOUQ>).

All results of 9141 cases which were done in Nobel Medical College by our team correlated with other similar publications.

DISCUSSION

The procedure called natural orifice transluminal endoscopic surgery (NOTES) was first described by Kalloo *et al.* in 2000, when they demonstrated a peroral transgastric endoscopic approach to the peritoneal cavity with long-term survival in animals.⁵ Gettman and colleagues in 2002 reported their series of transvaginal porcine nephrectomies.⁶ Rao and Reddy reported the first human case of NOTES in 2004 with a transgastric appendectomy.⁷

NOTES is a surgery type done solely through natural orifices such as transgastric or transoesophageal, transvaginal, transcolonic or transvesical.⁸

Robotic NOTES is a newly-developed technique using the Da Vinci surgical Robot (Intuitive Surgical, Sunnyvale, CA) to perform various surgical procedures.⁹

The transvaginal approach has been tested with some amount of success for NOTES, most commonly used in clinical practice for appendectomies and cholecystectomies and some urological and particularly gynecological applications.¹⁰ NOTES is a new technology, and will take long to be used in routine clinical practice.

The problems associated with transgastric approach as the orientation problem after bending back tip of the scope inside of abdomen, especially for surgeries on organs located in upper peritoneal cavity, difficulty of secure closure of the stomach or colon as well as inadequate amount of light to illuminate the operative area.

The most successful has been the vaginal approach, because closing the vagina is easy and it gives the possibility to use rigid laparoscopic instruments. However, some gynecologists are concerned about spread of endometriosis, pelvic adhesions, limitation in sexual life and following infertility after these procedures.

New multichannel devices and articulating instruments were developed, which resulted in the attempts of single-incision laparoscopic surgery. It eventually was named laparo-endoscopic single-site surgery (LESS).¹¹

Single-port laparoscopy is not a new method, which has already been used for over 40 years. In gynecology it has been used since the 1974 via laparoscopic tubal ligation with a single-puncture.¹² This technique was quite popular among gynecologists, because the uterus could be manipulated from vagina. That old type equipment had offset eyepieces among with a direct channel through which silicone ring applicator could be passed to band the Fallopian tubes.¹³ Vaginal manipulation of the uterus prevents the need for retraction. For triangulation the second instrument is needed. Pelosi *et al.* even reported an advanced pelvic extirpative surgery with the single puncture.¹⁴

Appendectomies have been done with a single incision as early as 1992.¹⁵ In this technique the appendix is coaxed out of the umbilicus to complete the operation after caecal mobilization. More recently this surgery has even been reported using transumbilical flexible endoscopy.¹⁶ The use of multiple trocars rapidly gained popularity due to the disadvantages of a single puncture. Conventional laparoscopy, which gained popularity even for complex procedures in surgery, was usually carried out through four or more ports. Increasing the number of incisions led to worse cosmetic effect, increased pain and risk of complications due to port site infections and hernias.¹⁷

One the major advantages of cutting down the number of ports would be the decrease of these complications rate. Furthermore, single-site surgery may be a closer step towards that elusive goal of NOTES.

The transumbilical technique for cholecystectomy, without additional incisions, was reported first by Navarre *et al.* in 1997 and later Piskun *et al.* in 1999.¹⁸ They used sutures for retract the gallbladder. Cuesta *et al.* published a report in 2008 about using Kirschner wires to anchor the gall

bladder.¹⁹ Curcillo and King made it popular by using an umbilical skin incision, which allowed keeping three or four ports at the distance of 1-2 cms from each other, which let them use one optic and two or three working instruments.²⁰ At the same time, Cadeddu with a group were working on almost the same method, using three separate low profile and short cannula through a single-incision in the umbilicus to do nephrectomies²¹.

Another method allows inserting 3 or 4 instruments through a single port by using special device which is inserted in the umbilicus. The first of these devices was the R- Port™ (Advanced Surgical Concepts, Wicklow, United Kingdom). This device was first used by Rao *et al.* in urology. The usage of the surgery was reported at the World Congress of Endourology in 2007. Later lots of new access devices were worked out, such as R-Port™ and the Uni-X™, SILS port™ by Covidien, SLASS™ by Ethicon, Air Seal™ by Surgique, Octoport™ by Daikin Surgical and X-Cone™ by Karl Storz [Figure 1]. These new access devices allowed inserting optics and more than two instruments, with trocars as in the GelPort and the SILS™ port and without them as in the R-Port™, through the same opening.²²



The major troubles of LESS surgery are the loss of triangulation, clashing of instruments and difficulties of lateral site manipulations. The articulating and prebent instruments were also developed later and helped to solve that type of issues.

Urologists and gynecologists use LESS more often than general surgeons. In general surgery it is mostly used for cholecystectomy and appendectomy. Many series of publications have been made of more than 100 cases of laparoscopic cholecystectomies including multi-institutional review, and the largest 2-year follow-up by Curcillo *et al.* Erbella *et al.* had a 98% success rate. Rivas *et al.* managed to do 87% of their cases with two trocars in the umbilicus and needed an additional port for other cases. There have been no major complications or hernias reported in these large series.²³ Some hospitals have reported other surgeries like colectomies, splenectomies, fundoplication, hernias, adrenalectomies, with good results.

The efficiency of the most of the reported LESS procedure is higher than conventional laparoscopy in terms of operative times, blood loss and length of hospital stay [Table 1].

Table 1: Frequency and percentage distribution of level of knowledge and practices regarding menstrual hygiene Pre-Test and post-Test

Authors and Year	Type of LESS	No of cases	Conversion rate	Complications rate
Bucher P. at al. 2009	Access device	11	0	0
Cuesta M.A. et al. 2008	Multi-port	10	0	0
Curcillo P.G. at al. 2010	All types	297	26	3
Erbella J. at al. 2010	SIMPLE	100	2	0
Kuon Lee S. at al. 2009	Access device	37	5	2
Navarra G. et al. 2008	Transumbilical two-ports	30	0	0
Palanivelu C. at al. 2008	Multi-port	10	4	1
Piskun G. et al. 1998	Transumbilical Multi-port	10	0	0
Podolsky E.R. at al. 2009	SIMPLE/SPA	5	0	0
Rao P. at al. 2008	R-Port	20	3	0
Rivas H. at al. 2009	SILS Port	100	13	0
Tacchino R. at al. 2009	Transumbilical three-ports	12	0	0
White W.M. at al. 2009	Access device	100	6	4
Zhu J.F. at al. 2009	Transumbilical three-ports	26	0	0
Sulaimankulov R. at al. 2020	Transumbilical Multi-port	9141	9	91

The acceptance of one incision among patients is much higher than of three or four openings. According to some research, transumbilical surgery has improved pain scales compared to standard laparoscopic cholecystectomy.²⁴⁻²⁶

There is a longer time for learning curve with LESS beyond conventional laparoscopy and it does not replace, for the moment, the “gold standard” status that belongs to the standard laparoscopic, but with a great developing potential in the future.

CONCLUSIONS

Single-port surgery has made a significant contribution into minimal access surgery. Many surgical, urological and gynecological centers, include Nobel Medical College, have adopted it for outstanding results in all sorts of intra abdominal surgeries. In line with numerous studies it proved to be practicable, reasonably safe and cosmetically more preferable than usual laparoscopy. However, a safe single-port surgery requires proper experience and good laparoscopic skills. Even with the best currently available SILS instrumentation, the LESS approach restricts instrument manipulation and retraction, it also significantly limits triangulation. It requires training and should be practiced in centers performing advanced laparoscopic surgery.

Our study correlated with others similar publications thus the existing evidence prove that the complication rate of SILS is less to the one of standard laparoscopic surgery.²⁴ The advantages of single access surgery include better cosmetic effect, reduced bleeding, infections, herniations and hospital stay.^{25,26}

LIMITATIONS OF THIS STUDY

The study was limited to our institution so further studies with a larger population would be better to establish the conclusion.

ACKNOWLEDGEMENT

The authors would like to thank Professor, Dr. Chitta Ranjan Das for his help.

CONFLICT OF INTEREST

The authors declare that they have no conflict of interest related to the publication of this manuscript.

FINANCIAL DISCLOSURE

There are no financial conflicts to disclose

REFERENCES

1. Mouret P. How I developed laparoscopic cholecystectomy. *Ann Acad Med Singapore*. 1996 Sep; 25(5) pp.744–7. PMID: 8924020
2. Litynski G.S. Profiles in laparoscopy: Mouret, Dubois, and Perissat: The laparoscopic breakthrough in Europe (1987-1988) *JSL*. 1999 Apr-Jun; 3(2) pp.163–7. PMID: 10444020
3. Curcillo P.G., Podolsky E.R. Re: Single-incision multiport laparoscopic (SIMPLE) surgery. *Surg Endosc*. 2010 Aug; 24(8) pp.2076–7. PMID: 20135169
4. Box G., Averch T., Cadeddu J., Cherullo E., Clayman R., Desai M., et al. Nomenclature of natural orifice transluminal endoscopic surgery (NOTES) and laparoendoscopic single-site surgery (LESS) procedures in urology. *J Endourol*. 2008 Nov; 22(11) pp.2575–81. PMID: 19046097
5. Kalloo A.N., Singh V.K., Jagannath S.B., Niiyama H., Hill S.L., Vaughn C.A., et al. Flexible transgastric peritoneoscopy: A novel approach to diagnostic and therapeutic interventions in the peritoneal cavity. *Gastrointest Endosc*. 2004 Jul; 60(1) pp.114–7. PMID: 15229442
6. Gettman M.T., Lotan Y., Napper C.A., Cadeddu J.A. Transvaginal laparoscopic nephrectomy: Development and feasibility in the porcine model. *Urology*. 2002 Mar; 59(3) pp.446–50. PMID: 11880100
7. Rao G.V., Reddy D.N., Banerjee R. NOTES: Human experience. *Gastrointest Endosc Clin N Am*. 2008 Mar; 59(3) pp.361–70. PMID: 18381176
8. Granberg C.F., Frank I., Gettman M.T. Transvesical NOTES: Current experience and potential implications for urologic applications. *J Endourol*. 2009 May; 23(5) pp.747–52. PMID: 19413495
9. Haber G.P., Crouzet S., Kamoi K., Berger A., Aron M., Goel R., et al. Robotic NOTES (Natural Orifice Transluminal Endoscopic Surgery) in reconstructive urology: Initial laboratory experience. *Urology*. 2008 Jun; 71(6) pp.996–1000. PMID: 18455769
10. Kaouk J.H., Haber G.P., Goel R.K., Crouzet S., Brethauer S., Firoozi F., et al. Pure natural orifice transluminal endoscopic surgery (NOTES) transvaginal nephrectomy. *Eur Urol*. 2009 Apr; 57(4) pp.723–6. PMID: 19913991
11. Gill I.S., Advincula A.P., Aron M., Cadeddu J., Canes D., Curcillo P.G., et al. Consensus statement of the consortium for laparoendoscopic single-site surgery. *Surg Endosc*. 2010 Apr; 24(4) pp.762–8. PMID: 19997938
12. Bailer P., Rauskolb R. Gynaecological laparoscopy. *Geburtshilfe Frauenheilkd*. 1975 Oct; 35(10) pp.747–53. PMID: 126893
13. Yoon I.B., King T.M. A preliminary and intermediate report on a new laparoscopic tubal ring procedure. *J Reprod Med*. 1975 Aug; 15(2) pp.54–6. PMID: 125337
14. Pelosi M.A., Pelosi M.A. Laparoscopic hysterectomy with bilateral salpingo-oophorectomy using a single umbilical puncture. *N J Med*. 1991 Oct; 88(10) pp.721–6. PMID: 1836254
15. Pelosi M.A., Pelosi M.A. Laparoscopic appendectomy using a single umbilical puncture (minilaparoscopy) *J Reprod Med*. 1992 Jul; 37(7) pp.588–94. PMID: 1387906
16. Palanivelu C., Rajan P.S., Rangarajan M., Parthasarathi R., Senthilnathan P., Praveenraj P. Transumbilical endoscopic appendectomy in humans: On the road to NOTES: A prospective study. *J Laparoendosc Adv Surg Tech A*. 2008 Aug; 18(4) pp.579–82. PMID: 18721008
17. Lowry P.S., Moon T.D., D'Alessandro A., Nakada S.Y. Symptomatic port-site hernia associated with a non-bladed trocar after laparoscopic live-donor nephrectomy. *J Endourol*. 2003 Sep; 17(7) pp.493–4. PMID: 14565880
18. Piskun G., Rajpal S. Transumbilical laparoscopic cholecystectomy utilizes no incisions outside the umbilicus. *J Laparoendosc Adv Surg Tech A*. 1999 Aug; 9(4) pp.361–4. PMID: 10488834
19. Cuesta M.A., Berends F., Veenhof A.A. The “invisible cholecystectomy”: A transumbilical laparoscopic operation without a scar. *Surg Endosc*. 2008 May; 22(5) pp.1211–3. PMID: 17943370
20. Podolsky E.R., Rottman S.J., Poblete H., King S.A., Curcillo P.G. Single port access (SPA) cholecystectomy: A completely transumbilical approach. *J Laparoendosc Adv Surg Tech A*. 2009 Apr; 19(2) pp.219–22. PMID: 19260790
21. Raman J.D., Bensalah K., Bagrodia A., Stern J.M., Cadeddu J.A. Laboratory and clinical development of single keyhole umbilical nephrectomy. *Urology*. 2007 Dec; 70(6) pp.1039–42. PMID: 18158008
22. Rane A., Rao P. Single-port-access nephrectomy and other laparoscopic urologic procedures using a novel laparoscopic port (R-port) *Urology*. 2008 Aug; 72(2) pp.260–4. PMID: 18468664
23. Erbella J., Bunch G.M. Single-incision laparoscopic cholecystectomy: The first 100 outpatients. *Surg Endosc*. 2010 Aug; 24(8) pp.1958–61. PMID: 20112110
24. Rao P.P., Rao P.P., Bhagwat S.M. Single-incision laparoscopic surgery - current status and controversies. *J Minim Access Surg*. 2011 Jan-Mar; 7(1) pp.6-16. PMID: 21197236
25. Goel A. Single Incision Laparoscopic Surgery - An Overview and Current Status. *Surgical Science*. 2012; 3 pp.503-505. DOI: 10.4236/ss.2012.310100
26. Sulaimankulov R., Das C.R., Jolochieva G., Koirala A., Bhattarai R. 8 Years of Experience in Laparoscopic Cholecystectomy by a Single Surgeon in Nobel Medical College, Nepal. 2019; 3(1) pp.11-15. DOI: 10.24969/hvt.2018.82

