

COMPLIANCE AND VISUAL OUTCOME OF “TREAT-AND-EXTEND” VERSUS “PRO RE NATA” DOSING OF INTRAVITREAL BEVACIZUMAB IN WET AGE-RELATED MACULAR DEGENERATION – A PERSPECTIVE FROM A DEVELOPING COUNTRY.

Joshi K^{1*}, Khatri A², Rijal RK³, K.C./Rai S⁴, Lamichanne G⁵, Yadav RD¹

Affiliation

1. Ophthalmologist, Lumbini Eye Institute, Bhairahawa, Nepal
2. Vitreoretina Surgeon, Vitreoretina Department, Birat Eye Hospital, Biratnagar, Nepal
3. Vitreoretina Surgeon, ASG Hospital, Kathmandu, Nepal
4. Professor, Pediatric Ophthalmologist, ShreekrishnaNetralaya, Bhairahawa, Nepal
5. Associate Professor, Medical Retina and Chief Medical Director, Lumbini Eye Institute, Bhairahawa, Nepal

ARTICLE INFO

Received : 15 November, 2019

Accepted : 12 February, 2020

Published : 30 June, 2020

© Authors retain copyright and grant the journal right of first publication with the work simultaneously licensed under Creative Commons Attribution License CC - BY 4.0 that allows others to share the work with an acknowledgment of the work's authorship and initial publication in this journal.



ORA 157

DOI: <https://doi.org/10.3126/bjhs.v5i1.29614>

* Corresponding Author

Dr. Kriti Joshi

Ophthalmologist, MD

Lumbini Eye Institute and Resarch Centre.

Email: crity_47@hotmail.com

ORCID ID: <https://orcid.org/0000-0001-8998-9852>

Citation

Joshi K, Khatri A, Rijal RK, Rai SKC, Lamichanne G, Yadav RD. Compliance and Visual Outcome of “treat-and- Extend” Versus “pro Re Nata” dosing of Intravitreal Bevacizumab in Wet Age-related Macular Degeneration – A Perspective From A Developing Country. BJHS 2020;5(1)11:921-926.

ABSTRACT

Introduction

Age- related Macular Degeneration (AMD) is the commonest cause of irreversible blindness and visual impairment in elderly, aged 50 years or older contributing 8.7% of global blindness. Among the two types: “dry” and “wet”, the “wet” variant is treated using anti-VEGFs, mainly via two regimen – PRN or TREX.

Objective

To study and compare the compliance, cost and visual outcome of “Treat-and- Extend (TREX)” versus “Pro Re Nata (PRN)” dosing of intravitreal bevacizumab in Wet AMD.

Methodology

Sixty-four eyes of 64 patients with treatment naïve neovascular AMD were included and randomly divided into two groups, with each group comprising 32 eyes, by lottery system: “Group A [TREX]” and “Group B [PRN]”. Group A was treated with intravitreal bevacizumab [1.25mg/0.05ml] at presentation and at 1-month interval for 3 consecutive months [loading dose] and monthly till dry macula was obtained. Group B was treated with the same in “as needed” basis. Both Groups were followed up, for 1 year.

Results

Mean gain in visual acuity in the PRN group was 0.09 +/- 0.35 log MAR unit and in TREX, it was 0.14 +/- 0.3 log MAR unit within the period of 1 year. 64% of the patients were compliant in TREX and 36% moderately complaint whereas in the PRN group, 24% were compliant, 60% moderately compliant and 16% noncompliant. Average hospital cost in PRN and TREX was NRs. 16, 170 (USD 149) and 23,785 (USD 220) respectively.

Conclusion

Compliance and visual outcome were better in TREX in comparison to PRN at 1 year of treatment with intravitreal bevacizumab for Wet AMD.

KEYWORD

ARMD, cost-effectiveness, PRN, TREX, Nepal,



INTRODUCTION

Age-related Macular Degeneration (AMD) is the commonest cause of irreversible blindness and visual impairment in elderly, 50 years or older contributing 8.7% of global blindness.^{1,2} Prevalence of AMD was found to be 3.1%-10.6% in Asian peoples. AMD is the third leading cause of blindness worldwide. In a previous population-based study in Nepal, AMD was found to contribute 8.7% of total blindness.³ It is often considered as a disorder primarily affecting macula which is characterized by progressive degeneration of photoreceptors or retinal pigment epithelial (RPE) complex. This results in focal deposition of acellular, polymorphous debris in between the retinal pigment epithelium and Bruch's membrane in and around macula which is known as drusen.^{4,5}

Conventionally, AMD is of 2 types: Dry / non-exudative AMD and Wet / exudative AMD. The "dry" form of macular degeneration is characterized by the presence of drusen and pigmentary changes, in the macula in early and intermediate stage and geographic atrophy (GA) in late stage. "Wet" AMD involves choroidal neovascularization (CNV) and hence termed neovascular AMD.⁶

CNV is the hallmark of neovascular AMD. "Type I" CNV involves the sub-RPE space and usually presents as a fibrovascular detachment of the RPE. "Type II" CNV involves the sub-neurosensory retinal space, and often appears as a gray-green lesion underneath the retina with overlying thickening of the retina. In Wet AMD, new immature blood vessels grow towards the outer retina from the underlying choroid. These immature blood vessels leak fluid and hemorrhage below or within the retina due to incompetent endothelial cells of pathologic new vasculature.^{7,8} This leads to distortion of vision that makes straight lines look wavy and appearance of central scotomas. These abnormal blood vessels and their bleeding eventually form a fibrovascular scar (subretinal disciform scar), which often appears as a white/yellow lesion with variable degrees of pigmentation, leading to permanent loss of central vision, if left untreated for a prolonged period.⁷

Neovascularization is largely driven by vascular endothelial growth factor A (VEGF-A) with VEGF165 appearing to be the most important isoform.⁹ Intravitreal injection of a vascular endothelial growth factor inhibitor (anti-VEGF) is the treatment of choice for wet AMD. Current approaches to inhibit VEGF involved the development of humanized monoclonal antibodies, "bevacizumab" (Avastin®; Genentech, Inc, South San Francisco, CA) and its derivative, "ranibizumab" (Lucentis®; Genentech, Inc), which neutralizes all active forms of VEGF and thus incapacitating the effect of VEGF on increased vascular permeability and presumably, angiogenesis. Newer anti-VEGF therapy includes "aflibercept" (VEGF Trap-eye; Regeneron Pharmaceuticals, Tarrytown, NY; Bayer Plc), which is a recombinant human fusion protein acting as a soluble decoy receptor for VEGF family.² Three drugs are currently

approved for the treatment of exudative AMD (pegaptanib, ranibizumab and aflibercept) by US Food and Drug Administration, and "bevacizumab" is frequently used "off-label" in ophthalmology. Other treatment options being laser photocoagulation and photodynamic therapy [PDT]. Unlike laser photocoagulation and photodynamic therapy, which only slowed the loss of vision, the anti-VEGF drugs frequently lead to long-term improvements in visual acuity. Doses of intravitreal bevacizumab (1.25 mg/0.05ml) injections has become common among many practitioners due to its better visual and anatomic outcome in AMD, market availability and relatively low cost.

Though most patients with AMD have the non-exudative (dry) form, most severe vision loss is due to exudative (wet) macular degeneration. Despite being third commonest cause of blindness worldwide, AMD is not yet a priority eye disease in the poorest and most populous regions of Asia and Africa. This is compounded by the fact that the available treatment for wet macular degeneration is out of reach to the average people of the developing countries.⁹

Poor compliance is the major issue in medical practice. It can be referred to as any deviation in patient's behavior from that recommended by the doctor. And the poor or inadequate compliance is referred to as the failure of the patient to get the prescribed drug for whatever reason. In this study we compared two different treatment modalities, "Treat and Extend" [TRES] and "pro Re Nata" [PRN] in Wet AMD on the basis of cost, compliance and visual outcome.

METHODOLOGY

A hospital-based prospective, observational analytical study was performed in 64 eyes of 64 patients diagnosed with treatment naïve wet AMD with choroidal neovascularization, aged 50 years or older and randomly divided into two groups, with each group comprising 32 eyes, by lottery system: "Group A [TRES]" and "Group B [PRN]".

Group A [TRES] was treated with intravitreal bevacizumab [1.25mg/0.05ml] at presentation and at 1-month interval for 3 consecutive months [loading dose]. Then, the patient was assessed by visual acuity and OCT findings in every visit. Patients were then continued with monthly injection till dry macula was obtained. Then, the time of next injection was extended by 2 weeks and further extension was made the time between injections as far apart as tolerated, as there was no signs of recurrence by 2 weeks each time. If there was active lesion or increased central retinal thickness at least by 100 micrometer as compared to previous visit, or had a visual acuity loss by 5 letters with sub-retinal fluid in OCT. Then time for next follow up was shortened by 2 weeks and so on until dry macula was obtained, and again extended by 2 weeks in the similar fashion for a duration of 1 year.



Group B [PRN] was treated with intravitreal bevacizumab [1.25mg/0.05ml] at presentation and monitored monthly with determination of BCVA and OCT for persistence of retinal thickness. And the eyes was treated on “as needed” basis depending upon the presence of intra- retinal or sub-retinal fluid. More specifically, if

1. There was loss of 5 letters in BCVA with fluid seen in macula in OCT.
2. If there was increased in CRT [in OCT] by at least 100 micrometers.
3. If there was new onset classic CNV OR
4. If there was new macular hemorrhage or persistent fluid is detected by OCT at least after one month of previous injection.

In each follow up, patient's UCVA, BCVA, anterior segment examination, posterior segment examination, IOP measurement and OCT were conducted and compared. Number and time of previous visits and number of total injections given were also recorded.

BCVA was obtained using log MAR acuity chart. For “TREX” group, the number of patients who continued treatment and followed-up appointments for 1 year from the time of diagnosis were determined. Patients who regularly received 3 consecutive IVB treatments after being diagnosed with wet AMD and follow up regularly for 1 year thereafter were grouped as the 'compliant group' (Group 1), while patients who did not regularly receive 3 consecutive intravitreal bevacizumab (IVB) treatments or could not follow up regularly for 1 year were grouped as the 'noncompliant group' (Group 2). Group 2 was further divided into 2 subgroups: patients who completed 3 consecutive months of IVB treatment but who were unable to complete 1 year of follow-up and treatment “moderately compliant” (Group 2a), and patients who were unsuccessful in completing their 1 year of follow-up and treatment, including the initial 3 consecutive monthly IVB injections “ poor compliance” (Group 2b).

For “PRN” group, the patients who completed regular follow up and received the treatment as advised for 1 year were considered 'compliant group' (Group 1), the patients who followed up regularly for 1 year but denied to receive treatment as advised irrespective of the cause were grouped as 'moderately compliant' (Group 2a) and those who lost follow up in the middle of the year were grouped as 'poor complaint' (Group 2b).

Compliance among the individual within the same group and that between two groups were compared and analyzed.

The total number of visits each patient had to attend and had attended were noted at the end of 1 year. Total number of intravitreal injections received by each patient within 1-year period were noted. Total expenses that each patient had to bear in individual group were calculated and average cost comparison was done among the individuals who fell under “complaint group”.

RESULTS

Among the 64 patients enrolled, 32 were placed in PRN group and the rest 32 in TREX group. Patients aging from 50 years to those more than 80 years were included in the study (Figure 1). Among them, most of the patients were of 60-70 years age group that consisted 37.5% of the total subjects. Moreover, mean age of the patients included in the study was 68.66 years with standard deviation of 9.51. Mean age of the patients in TREX group was 67.64 +/- 8.78 and that of PRN group was 69.68 +/-10.28 (Table 1).

Similarly, out of the 64 patients, 34 were male and 30 were female depicting no significant gender variation in the study (Figure 2). However, out of 32 patients included in PRN group, 12 were male and 20 were female. In contrast, there were 22 male participants and 10 female participants among the 32 patients included in TREX group.

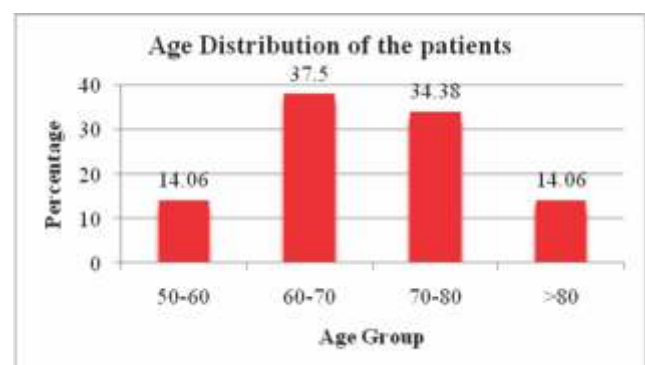


Figure 1 : Age Distribution of patients

Table 2 : Time of onset of Sensory block.

Treatment Group (Age)	Mean	SD	P-value
PRN	69.68	10.282	0.454
TREX	67.64	8.779	
Over All	68.66	9.51	

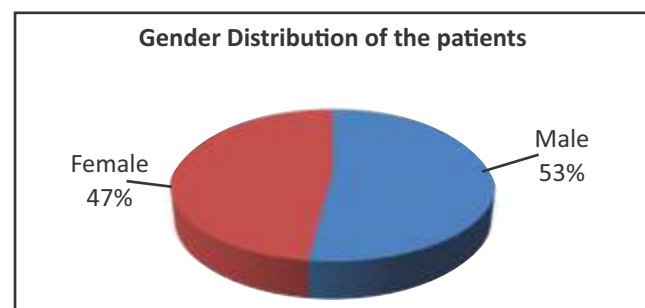


Figure 2 : Gender distribution of the patients

Among 32 patients enrolled in PRN, 8 of them or 24 % were complaint to the treatment, 19 (60%) were moderately complaint and 5 (16%) were non- compliant to the treatment. However, the cause of non-compliance and factors affecting the compliance of the patient were not studied in detail. Similarly, 20 (64%) of the patients in TREX

were complaint and 12 (36%) were moderately complaint ($p < 0.005$). There were no non-complaint cases in TREX group (Table 2 and Figure 3).

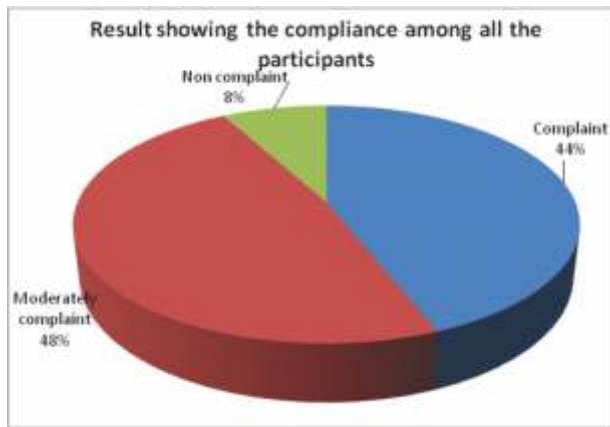


Figure 3 : Compliance among all participants

Group	Treatment group		p-Value
	PRN	TREX	
Complaint	8 (24%)	20 (64%)	0.002
Moderately complaint	19 (60%)	12 (36%)	
Non complaint	5 (16%)	0	

Visual Acuity	PRN		TREX		P – value
	Mean	Standard deviation	Mean	Standard Deviation	
Visual acuity on initial visit	1.1 log MAR unit	0.38 log MAR unit	0.99 log MAR unit	0.47 log MAR unit	0.026
Visual acuity on final visit	1.05 log MAR unit	0.34	0.787 log MAR unit	0.787 log MAR unit	
Gain in visual acuity	0.076 log MAR unit	0.394	0.18 log MAR unit	0.273	0.003

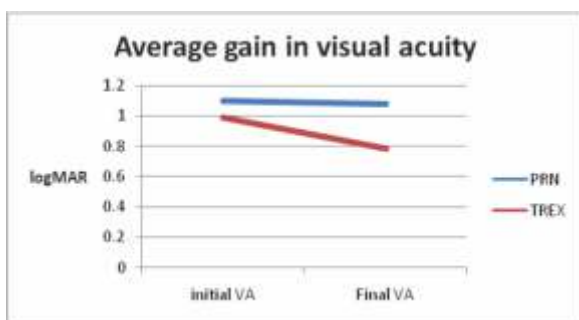


Figure 4 : Average gain in visual acuity in two groups

Average injection of intravitreal bevacizumab applied to PRN group at the end of 1 year was 2.83 +/- 1.472 ($p < 0.001$) and in TREX group was 4.31 +/- 1.014 ($p < 0.001$).

Average number of hospital visits in PRN group within 1 year was 6.88 +/- 1.59. On the other hand, average number of visits in TREX group was 6.64 +/- 1.036 in 1 year. The

difference in average visits among the two groups was not statistically significant.

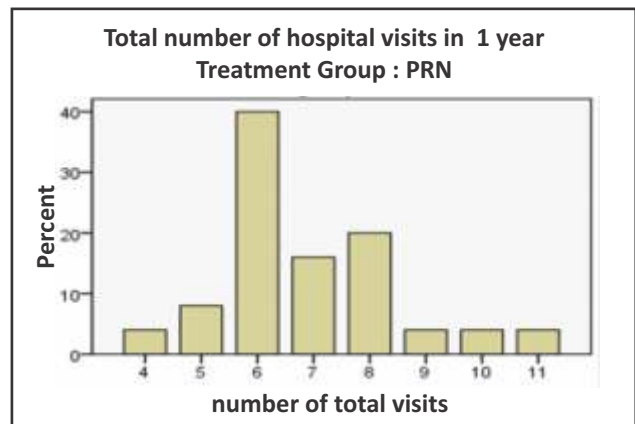


Figure 5 : Number of hospital visits in PRN group

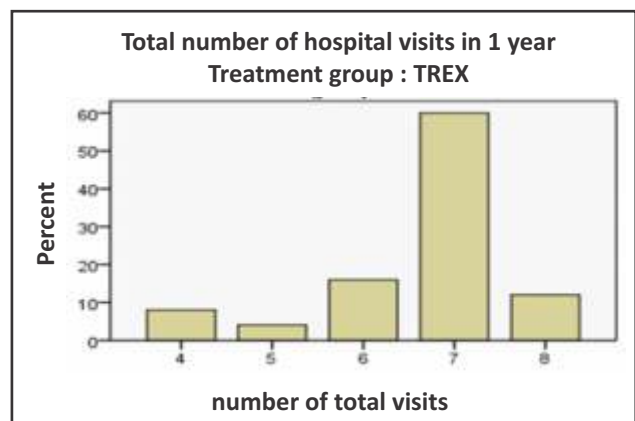


Figure 6: Number of hospital visits in TREX group

At the end of 1 year, mean of the total hospital expenses needed for patients of PRN group was NRs.16,170 with standard deviation of 5,695. On the other hand, mean of total hospital expenses required in TREX group was NRs. 23,785 with standard deviation of 6,303 ($p < 0.001$) (Figure 7)

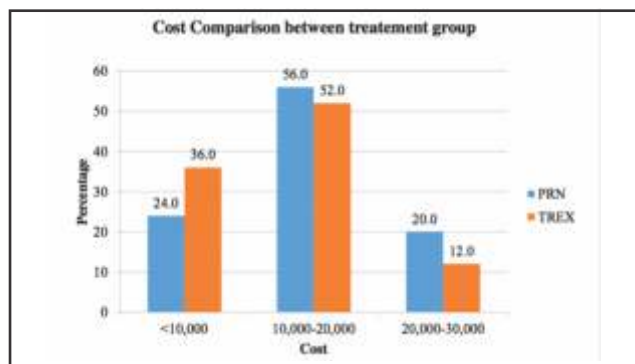


Figure 7 : Cost Comparison of TREX and PRN

DISCUSSION

AMD is a bilateral, progressive, non-curable disease primarily affecting elderly. And 15% of the patients with unilateral wet AMD are found to develop wet AMD in fellow eye in each successive years.^{10,11} It is an “aging macular disorder” which follows normal aging process of macula as

aging is associated with cumulative oxidative injury.¹⁰ However, along with physiological aging changes in RPE and Bruch's membrane, genetic and environmental factors also influence the development pattern and progression of age related macular degeneration. As wet age-related macular degeneration develops, presence of subretinal/sub-RPE serous or hemorrhagic fluid originating from subretinal neovascularization in the macula, appears as the preliminary sign of the disease. This leads to the detachment of neurosensory retina or the RPE from Bruch's membrane. The detachment disturbs the fine arrangement of the photoreceptors leading to increase or decrease in the distance between the photoreceptors which subsequently leads to distortion of image called metamorphopsia and micropsia or macropsia respectively. This often presents as the first symptom of wet ARMD.¹¹

Intravitreal application of bevacizumab is one of the most accepted and preferred treatment option for wet AMD in current era. And its use in treatment of wet AMD, was first reported by Rosenfeld et al¹² in 2005 in a patient with recurrent neovascular AMD who had previously failed photodynamic therapy with verteporfin in with intravitreal triamcinolone acetonide and intravitreal pegaptanib therapy. Since then, multiple prospective and retrospective studies were performed to see the effectiveness of bevacizumab for treatment of wet AMD.

Treatment with intravitreal bevacizumab has shown to have increased likelihood of moderate vision recovery and decrease the risk of moderate vision loss. It is also associated with improvement in mean visual acuity at one year. However, there are significant variation in improvement in different dosing regimen of bevacizumab.¹³

Management of neovascular AMD using intravitreal anti-VEGF monotherapy, has led to the achievement of optimal visual outcomes with subsequent maintenance of an exudation-free macula.¹⁴ Despite significant progress in retaining good vision, there is no universally accepted treatment regimen for nAMD that defines the frequency and duration of treatment needed to achieve the optimal visual outcomes while simultaneously balancing the burden of long-term, frequent and high-cost treatment.¹⁵ Initially, anti-VEGFs were recommended according to pro re nata (PRN / as needed) regimen where re-treatment was indicated with cut off of 5 letters loss. But later on, it was realized that this could limit the potential benefit of treatment. So, Spaide and Freund first described treat and extend (TRES) regimen a decade ago, and since then it has become able to grab attention of many retina specialist due to its practice efficiency and cost-containment. TRES approach minimizes clinical visits and treatments while maintaining the optimal visual outcomes. It also minimizes the financial and psychological costs of need for frequent treatment. However, a small proportion of patients may not require long-term treatment with intravitreal injection therapy after episodes of monthly PRN treatments till no evidence of exudation is seen, at least through 2 years of follow-up. Isolating this population and then using a TRES approach for the

remainder of the population may be a reasonable approach.^{15,16}

Abedi et al¹⁷ performed a single arm prospective study on "Treat and Extend" use of Ranibizumab (0.5mg) or bevacizumab 1.25mg for 24 months and found that 95% lost and 30% gained more than 15 ETDRS letters and there was increased likelihood of vision loss in cases with better baseline vision. Patients started off with a low baseline vision were more likely to improve with treatment and the baseline visual acuity was the only variable significantly associated with change in visual acuity. Whereas in this study, it was found that better baseline vision resulted in better final visual outcome and stage of disease, presence of active lesion in OCT, initial CRT and patients' compliance were important variables affecting the outcome.

Rayess et al¹⁸ evaluated the outcome of treat and extend regimen of anti-VEGF for up to 3 years of follow-up and found that overall, a significant gain in visual acuity was achieved with fewer hospital visits and fewer number of injections and similar was the case in this study too.

Similarly, Gupta et al¹⁹ performed a retrospective study of Treat and Extend regimen of Ranibizumab in nAMD to evaluate the visual outcome, number of injections and direct medical cost of a "treat and extend" regimen, unlike our study, he found that direct annual medical cost per patient based on previous clinical trial protocols were comparable in two groups. He also reported there was significant visual improvement in TRES as found in our study.

When all is said and done, there are still many factors to be taken into consideration while choosing the approach to maintenance therapy for wet AMD. First, these drugs do not cure or change the course of wet AMD, so ongoing therapy is likely to be needed for many years in most patients. Second, the optimal treatment regimen is not known, and the best approach for treatment may differ for different patient. Third, consideration of efficacy, safety, and treatment burden is utmost to provide best treatment approach.²⁰

Regardless of the treatment approach chosen, one very important concept must be analyzed and understood-irrespective of the regimen, early treatment after early detection with smaller lesion leads to better results.

CONCLUSION

Despite higher number of injections required and more average ? hospital cost required, final visual outcome was better in TRES regimen of intravitreal bevacizumab in neovascular AMD. Further, compliance of the patients to follow up and treatment was better in TRES regimen. In contrary, despite the need of frequent hospital visit, the final visual and anatomical outcome was relatively poor in PRN regimen of intravitreal bevacizumab. Due to increased need of unnecessary hospital visits, despite the low cost, patients' compliance to follow up and treatment was found to be poor in PRN regimen.



LIMITATION AND RECOMMENDATION

Despite all the fact, there are also few limitations of the study. Since, the duration of the study is only of 1 year further long-term studies of similar kind is required to draw a conclusion on long term effects of these two regimen in course of treatment of neovascular AMD. Further, the study is needed to be conducted with larger sample size and longer period of follow up visits. Moreover, study of each variable is needed to be done as a separate entity.

ACKNOWLEDGEMENT

We would like to thank Mr. Mahesh Aryal for performing OCT in all our patients and Mrs. Rojina Khan for allocating appointments for our patients.

DISCLOSURES

Funding:

No funding was received from any person, institute or organization to conduct the study.

Competing interests

We declare no competing interest.

Ethical Clearance

The research was approved by the institutional review board (IRB) of Lumbini Eye Institute (LEI) and Institutional Review Committee (IRC) of National Academy of Medical Sciences (NAMS) and has adhered to the protocol of Helsinki.

FINANCIAL DISCLOSURE

None

CONFLICT OF INTEREST

None

REFERENCES

- Resnikoff S, Pascolini D, Etya'ale D, et al. Policy and Practice. Bull World Health Organ 2004; 82: 844–851. Available from : <https://www.who.int/bulletin/volumes/82/11/en/844.pdf> (Accessed Date Nov 2019)
- Ratnapriya R, Chew E. Age-related macular degeneration - Clinical Review and genetic update. Clin Genet 2013; 84: 160–166. doi: 10.1111/cge.12206
- Klein B, Klein R, Sponsel W, et al. Prevalence of glaucoma: the Beaver Dam eye study. Ophthalmology; Available from: <http://www.sciencedirect.com/science/article/pii/S0161642092317749> (1992).
- Thapa R, Paudyal G, Shrestha MK, et al. Age-related macular degeneration in Nepal. Kathmandu Univ Med J (KUMJ) 2011; 9: 165–9. DOI: 10.3126/kumj.v9i3.629
- Age-related macular degeneration (AMD): Overview. Informed Health Online [Internet]. Cologne, Germany: Institute for Quality and Efficiency in Health Care (IQWiG) 2015; 2006–2008. Available from: <https://www.ncbi.nlm.nih.gov/books/NBK315804/>
- Bowes Rickman C, Farsiu S, Toth CA, et al. Dry age-related macular degeneration: Mechanisms, therapeutic targets, and imaging. Invest Ophthalmol Vis Sci; 54. DOI: 10.1167/iovs.13-12757.
- Yonekawa Y, Miller J, Kim I. Age-Related Macular Degeneration: Advances in Management and Diagnosis. J Clin Med 2015; 4: 343–359. doi: 10.3390/jcm4020343.
- Ambati J, Fowler B. Mechanisms of age-related macular degeneration. Neuron 2012; 75: 26–39. doi: 10.1016/j.neuron.2012.06.018.
- Grisanti S, Ziemssen F. Bevacizumab: Off-label use in ophthalmology. Indian J Ophthalmol 2007; 55: 417–420. doi: 10.4103/0301-4738.36474
- Harman D. Aging: a theory based on free radical and radiation chemistry. J Gerontol 1956; 11: 298–300. doi: 10.1093/geronj/11.3.298
- Jager RD, Mieler WF, Miller JW. Age-Related Macular Degeneration. N Engl J Med 2008; 358(24):2606–2617. doi: 10.1056/NEJMra0801537
- Michels S, Rosenfeld PJ, Puliafito CA, Marcus EN, Venkatraman AS. Systemic Bevacizumab (Avastin) Therapy For Neovascular Age-Related Macular Degeneration: Twelve-Week Results Of An Uncontrolled Open-Label Clinical Study. Ophthalmology 2005; 112(6):1035–1047. DOI: <https://doi.org/10.1016/j.ophtha.2005.02.007>
- Tufail A, Patel PJ, Egan C, Hykin P, Da Cruz L, Gregor Z, et al. Bevacizumab for Neovascular Age related Macular Degeneration (ABC Trial): Multicentre randomised double masked study. BMJ 2010; 340(7761):c2459. DOI: 10.1136/bmj.c2459
- Larsen M, Mone JS. Treat and Extend Regimen for nAMD. Retina Today, 2018; 3–11. Available from: <http://retinatoday.com/2011/04/treat-and-extend-a-better-approach-to-individualized-dosing-for-wet-amd/>
- Gemenetzki M, Patel PJ. A Systematic Review of the Treat and Extend Treatment Regimen with Anti-VEGF Agents for Neovascular Age-Related Macular Degeneration. Ophthalmol Ther 2017; 6(1):79–92. doi: 10.1007/s40123-017-0087-5
- Wykoff CC, Ou WC, Brown DM, Croft DE, Wang R, Payne JF, et al. Randomized Trial of Treat-and-Extend versus Monthly Dosing for Neovascular Age-Related Macular Degeneration: 2-Year Results of the TREX-AMD Study. Kidney Int Reports 2017; 2(4):314–321. doi: 10.1016/j.oret.2016.12.004
- Abedi F, Wickremasinghe S, Islam AF, Inglis KM GR. Anti-VEGF treatment in neovascular age-related macular degeneration: a treat-and-extend protocol over 2 years. Retina 2014; 38(8):1531–8. doi: 10.1097/IAE.0000000000000134.
- Vardarinos A, Gupta N, Janjua R, Iron A, Empelelidis T, Tsaousis K. 24-Month Clinical Outcomes of a Treat-and-Extend Regimen With Ranibizumab for Wet Age-Related Macular Degeneration in a Real Life Setting. BMC Ophthalmol 2017; 17(1):1–7. doi: 10.1186/s12886-017-0451-1.
- Gupta OP, Shienbaum G, Patel AH, Fecarotta C, Kaiser RS, Regillo CD. A Treat And Extend Regimen Using Ranibizumab For Neovascular Age-Related Macular Degeneration: Clinical And Economic Impact. Ophthalmology 2010; 117(11):2134–2140. doi: 10.1016/j.ophtha.2010.02.032.
- Regillo CD. Anti-VEGF Maintenance Therapy for Neovascular AMD. 2014; 63–67. Available from: http://retinatoday.com/pdfs/0514RT_F_Regillo.pdf

