

# EFFECTIVENESS OF INTRA-ARTICULAR STEROID INJECTION IN TREATMENT OF IDIOPATHIC FROZEN SHOULDER FOLLOWED BY PHYSIOTHERAPY AND HOME EXERCISE PROGRAM.

Sah S<sup>1\*</sup>, Karn S<sup>3</sup>, Sigdel D<sup>2</sup>, Dahal M<sup>1</sup>, Kathet R<sup>2</sup>, Yadav R<sup>1</sup>, Adhikari AR<sup>3</sup>.

## Affiliation

1. Consultant, Department of Orthopedics, Koshi Zonal Hospital, Biratnagar, Morang
2. Consultant, Department of Medicine, Koshi Zonal Hospital, Biratnagar, Morang
3. Consultant, Department of Physiotherapy, Koshi Zonal Hospital, Biratnagar, Morang

## ARTICLE INFO

### Article History

Received : 7 January, 2019

Accepted : 24 April, 2019

Published : 30 April, 2019

© Authors retain copyright and grant the journal right of first publication with the work simultaneously licensed under Creative Commons Attribution License CC - BY 4.0 that allows others to share the work with an acknowledgment of the work's authorship and initial publication in this journal.



ORA 100

DOI: <http://dx.doi.org/10.3126/bjhs.v4i1.23932>

### \* Corresponding Author

Dr. Shambhu Sah

Consultant Orthopedic Surgeon

Department of Orthopedics

Koshi Zonal Hospital, Biratnagar, Nepal.

Email: drssah@yahoo.com

Orcid ID : <http://orcid.org/0000-0002-8606-9564>

## Citation

Sah S, Karn S, Sigdel D, Dahal M, Kathet R, Yadav R, Adhikari AR. Effectiveness of Intra-articular Steroid Injection in Treatment of Idiopathic Frozen Shoulder Followed by Physiotherapy and Home Exercise Program. BJHS 2019;4(1)8: 611 - 615.

## ABSTRACT

### Introduction

Idiopathic frozen shoulder (IFS) is a common chronic and disabling condition of shoulder pain characterized by progressive loss of active and passive range of motion (ROM) with unclear pathogenesis. The ideal treatment protocol is still controversial but commonly used treatment includes single agent or combination of oral non-steroid anti-inflammatory drugs (NSAIDs), oral steroids, intra-articular steroid injection and physiotherapy.

### Objective

The objective of this study was to evaluate the effectiveness of intra-articular methylprednisolone injection for pain and ROM in patients suffering from idiopathic frozen shoulder who did not respond to oral NSAIDs with or without oral steroid.

### Methodology

70 patients suffering from IFS were enrolled in this cross-sectional study from May 2017–October 2018 from outpatient department of orthopaedic and physiotherapy of Koshi Zonal Hospital. All the patients underwent treatment protocol that comprised of Intra-articular steroid injection followed by five days of oral NSAIDs along with five days regime of physical therapy at the physiotherapy centre, followed by home exercise program. Each patient was followed up at every two weeks interval from intra-articular injection till 6th week. Each patient was evaluated for range of motion (ROM), Numerical Pain Rating Scale (NPRS) and Shoulder Pain and Disability Index (SPADI) before the treatment protocol and at every follow up visit. Data was analyzed using Microsoft Excel Program.

### Results

All patients enrolled for the study had satisfactory response. The mean age of the patients was 51.8 years (range 40-65 years). The mean age of the 26 male patients was 54 years (range 45-65), whereas the mean age of 44 female patients was 50.5 years (range 45-60). Mean duration of illness was 26.5 weeks (range 18-32 weeks), SPADI before medication was 83.14, at 2nd week was 50.92, at 4th week was 38.63 and at 6th week was 27.22.

### Conclusion

Combination of intra-articular methylprednisolone injection, physiotherapy and home exercise program is effective in IFS for rapid improvement in pain and ROM.

### KEY WORDS

Disability index, frozen shoulder, idiopathic



## INTRODUCTION

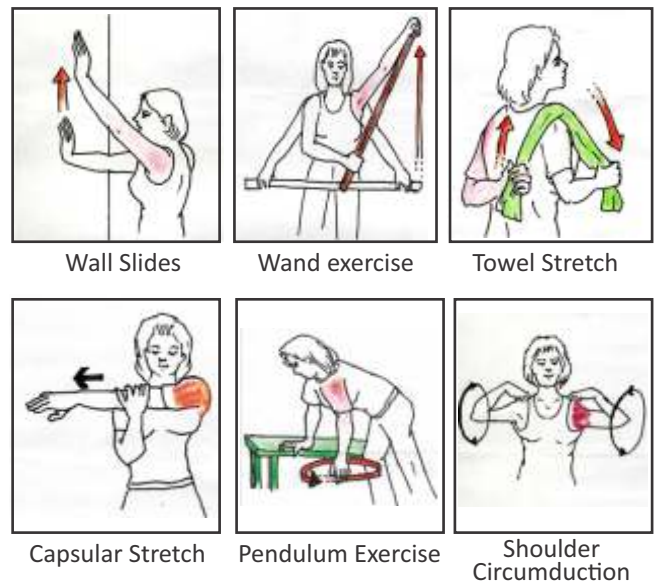
Frozen shoulder or adhesive capsulitis has been defined as a common condition of uncertain aetiology characterized by significant restriction of both active and passive shoulder motion that occurs in the absence of a known intrinsic shoulder disorder. The term "frozen shoulder" was coined by Codmen in 1934.<sup>1</sup> It can be classified into primary and secondary types. The primary frozen shoulder is idiopathic whereas the secondary frozen shoulder includes an association with a primary cause which may be any trauma, a rotator cuff tear, hemiparesis, cardiovascular disease or diabetes mellitus etc. As the definition suggests, idiopathic frozen shoulder is characterized by spontaneous chronic pain in the shoulder accompanied by gradual loss in both the active and passive range of motions and fibrosis of the capsule of the shoulder joint ultimately leading to stiffness and disability.<sup>1,2,3</sup>

Frozen shoulder affects 2% to 5% of general population, typically between 4<sup>th</sup> to 6<sup>th</sup> decade of life. The natural history of idiopathic frozen shoulder comprises of three stages. The first stage of "freezing" is characterized by increasing pain and stiffness lasting 2-9 months. Freezing stage is followed by the stage of persistent stiffness which lasts 4-12 months termed as "frozen" stage. Shoulder motions are lost in this frozen stage. The frozen stage then progresses to "thawing" stage of spontaneous recovery characterized by return of the restricted motion and reduction in pain. Thawing stage lasts 12-42 months. The common goals for treatment include pain management with restoration of movement and functions of shoulder. Conservative treatment includes options like non-steroidal anti-inflammatory drugs (NSAIDs), corticosteroids injections, physical therapy, whereas treatment options like capsular distension, manipulation under anaesthesia, arthroscopic capsular release are considered on failure of conservative treatment.<sup>4,5,6</sup> This study was aimed at determining the effectiveness of intra-articular steroid injection followed by physical therapy for pain and range of shoulder motions in patients who did not respond to conservative treatment with NSAIDs with or without oral corticosteroids.

## METHODOLOGY

70 patients were enrolled for this cross sectional study by convenient sampling from the Orthopaedic and Physiotherapy department of Koshi Zonal Hospital from May 2017 to October 2018 according to Helsinki's Declarational for studying the role of intra-articular methyl prednisolone injection supervised by physiotherapist followed by home exercises program in management of idiopathic frozen shoulder. All the patients enrolled for this study were in the frozen stage of frozen shoulder as diagnosed by the orthopaedician. Informed written consent was taken from all the patients who accepted to participate in the study. The patients included in the study were earlier treated conservatively with NSAIDs with or without oral

steroid in or outside the institution for IFS but did not respond to the treatment with persisting complaints of pain and limitation in movement. Those patients who could follow up in every two weeks interval for three doses of intra-articular injection, and could attend mandatory five day physiotherapy at the centre for stretching and ROM exercises with oral NSAIDs for 5 days after intra-articular injection were selected for the study. The patients were prescribed NSAIDs for five days only during first intra-articular injection and were then taught shoulder exercises for 5 days by the physiotherapist at the institution as home exercise program to be done by patients themselves. The home exercise program comprised of wall slides, wand exercises, towel stretch, active capsular stretch exercise, pendulum exercise and shoulder circumduction.



**Figure 1:** Exercises included in home exercise program (Left shoulder affected).

The patients included in this study were diagnosed cases of idiopathic frozen shoulder aged 40 to 70 years, clinically suffering from pain and decreased ROM (at least 50% loss of external rotation) and normal x-rays on antero-posterior and axillary lateral radiographs of the glenohumeral joint with duration of illness at least four months. We also investigated some blood examinations such as TC, DC, ESR, CRP, and RBS. Exclusion criteria were diabetes mellitus, contraindications of injections and any previous shoulder surgery. The glenohumeral joint was injected via an anterior or posterior approach. The solution injected contained 2ml of 2% plain lidocaine and 40mg methylprednisolone acetate (Depo-Medrol; Pfizer). Outcome measures used were Shoulder Pain and Disability Index (SPADI) Table:1, Numerical pain rating scale (NPRS), and both active and passive range of motion (ROM) which was measured using universal goniometer.<sup>7,8,9</sup> Data were analyzed by using Microsoft excel program.

**Table 1: SPADI****PAIN SCALE (How severe is your pain )**

1. At its worst.	No pain 0 1 2 3 4 5 6 7 8 9 10 Worst Pain Imaginable
2. When lying on involved side.	No pain 0 1 2 3 4 5 6 7 8 9 10 Worst Pain Imaginable
3. Reaching for something on a high shelf.	No pain 0 1 2 3 4 5 6 7 8 9 10 Worst Pain Imaginable
4. Touching the back of your neck.	No pain 0 1 2 3 4 5 6 7 8 9 10 Worst Pain Imaginable
5. Pushing with the involved arm.	No pain 0 1 2 3 4 5 6 7 8 9 10 Worst Pain Imaginable

**DISABILITY SCALE (How much difficulty did you have)**

1. Washing your hair.	No difficulty 0 1 2 3 4 5 6 7 8 9 10 So difficult required help
2. Washing your back.	No difficulty 0 1 2 3 4 5 6 7 8 9 10 So difficult required help
3. Putting on an undershirt or pullover sweater.	No difficulty 0 1 2 3 4 5 6 7 8 9 10 So difficult required help
4. Putting on a shirt that buttons down the front.	No difficulty 0 1 2 3 4 5 6 7 8 9 10 So difficult required help
5. Putting on your pants.	No difficulty 0 1 2 3 4 5 6 7 8 9 10 So difficult required help
6. Placing an object on a high shelf.	No difficulty 0 1 2 3 4 5 6 7 8 9 10 So difficult required help
7. Carrying a heavy object of 10 pounds.	No difficulty 0 1 2 3 4 5 6 7 8 9 10 So difficult required help
8. Removing something from your back pocket.	No difficulty 0 1 2 3 4 5 6 7 8 9 10 So difficult required help

**RESULTS**

70 patients were included in this study with mean age 51.8 years (range 40-65years), 26 male (37.14%) patients with mean age 54 years (range 45-65 years) and 44 female (62.86%) patients with mean age 50.5 years (range 40-65 years). The mean duration of illness was 26.54 weeks (range 18-32 weeks).

At diagnosis SPADI pain score was  $83.71 \pm 6.18$ , SPADI disability score was  $82.57 \pm 6.06$ , total SPADI score was  $83.14 \pm 4.75$  and mean NPRS score was 8. After our treatment protocol we found good results (Table 2 and Table 3).

**Table 2: Distribution of age, sex, side of shoulder and duration**

Mean $\pm$ SD age (Range)	51.8 $\pm$ 7.46 (40-65) years
Number of male patients	26
Mean $\pm$ SD age (Range)	54 $\pm$ 6.45 (45-65) years
Number of female patients	44
Mean $\pm$ SD age (Range)	50.5 $\pm$ 7.78 (40-65) years
Male frozen shoulder right / left	10/16
Female frozen shoulder right / left	22/22
Duration of symptoms ( weeks)	26.54 $\pm$ 3.96

**Table 4: Numerical pain rating scale NPRS (0 being labelled as "no pain" and 10 being labelled as "worst pain" imaginable)**

Before medication	1st week (1st intra-articular injection)	2nd week (2nd intra-articular injection)	4th week (3rd intra-articular injection)	After 3rd intra-articular injection follow up 2 weeks i.e. 6th week
8	6	5	3	2

Steroid flare reaction or severe pain was found in eleven (15.7%) patients (1st dose IA injection in 9 patients and 2nd dose IA in 2 patients) after intra-articular (IA) injection; side effect typically starts a few hours after the injection and wears off within 24-72 hours.

**Table 3: SPADI Score (%)**

Score (% Mean)	Before intra articular injection	day (1st intraarticular injection)	week (2nd intra-articular injection)	4 week (3rd intra articular injection)	up 3rd intra-articular injection
	Pain score	83.71 $\pm$ 6.18 (70-100)	68.6 $\pm$ 6.64 (80-60)	53 $\pm$ 8.83 (44-70)	39.63 $\pm$ 10.8 (30-60)
Disability	82.57 $\pm$ 6.06 (70-90)	66.93 $\pm$ 6.88 (55-80)	48.86 $\pm$ 11.27 (40-70)	37.64 $\pm$ 11.48 (30-60)	27 $\pm$ 11.75 (20-50)
Total SPADI	83.14 $\pm$ 4.75 (70-90)	67.76 $\pm$ 5.72 (59.5-80)	50.93 $\pm$ 9.92 (42-70)	38.64 $\pm$ 10.97 (30-60)	27.23 $\pm$ 11.65 (20-50)

**Table 5: Range of motion (ROM) active and passive**

	Flexion		Abduction		External-rotation		Internal-rotation	
	Active	Passive	Active	Passive	Active	Passive	Active	Passive
Before intra-articular injection	87.34 $\pm$ .89	91.86 $\pm$ 3.68	77.16 $\pm$ .54	82.5 $\pm$ 6.67	21.47 $\pm$ 2.28	24.46 $\pm$ 2.99	33.68 $\pm$ 2.73	36.7 $\pm$ 1.54
1st intra-articular injection (Day 1)	93.4 $\pm$ 3.65	99.66 $\pm$ 3.93	79.27 $\pm$ .16	86 $\pm$ 5.04	23.83 $\pm$ 8.24	28.19 $\pm$ 3.32	35 $\pm$ 2.43	38.91 $\pm$ 1.7
2nd intra-articular injection (At 2 weeks)	106.5 $\pm$ 4.01	113.61 $\pm$ 4.87	94.17 $\pm$ .77	102.37 $\pm$ 5.31	29.16 $\pm$ 4.21	35.69 $\pm$ 3.68	41 $\pm$ 1.12	47.39 $\pm$ 2.03
3rd intra-articular injection (At 4 weeks)	125.44 $\pm$ 5.02	131.7 $\pm$ 3.96	121.28 $\pm$ 4.01	130.44 $\pm$ 4.52	40.57 $\pm$ 4.08	48.23 $\pm$ 3.98	50.41 $\pm$ 2.45	56.36 $\pm$ 3.5
After 3rd injection follow up 2 weeks (At 6 weeks)	143 $\pm$ 4.76	153 $\pm$ 4.56	143.97 $\pm$ 3.99	154 $\pm$ 4.73	53.1 $\pm$ 4.09	60.93 $\pm$ 4.57	53.3 $\pm$ 2.6	59.83 $\pm$ 3.32

## DISCUSSION

The aim of this study was to evaluate the effectiveness of intra-articular steroid injection along with physiotherapy in pain and range of motion of the patients with frozen shoulder who did not respond to oral NSAIDs with or without oral steroids. The patients enrolled in this study had decreased range of motion in external rotation and abduction during diagnosis. The chances of any other associated disease were ruled out with the help of normal x-ray and blood investigation. Clinical diagnosis of idiopathic frozen shoulder may be difficult because symptoms are similar to rotator cuff tendinitis in early phase; glenohumeral joint motion is reduced along with increased scapulothoracic motion. Chronic fibrosing and chronic inflammation condition of capsule can be shown in biopsies with pathology of IFS but patho-anatomy is not fully understood. There is no definitive test for the diagnosis of frozen shoulder. Although studies have reported clinical diagnosis of frozen shoulder can be done if there is painful restriction of active and passive motion in at least two planes of motion especially external rotation. Pathophysiological investigations have revealed thickening and shortening of joint capsule in idiopathic frozen shoulder associated with more densely packed collagen, this leads to joint restriction.<sup>10,11,12</sup>

There is variety of therapeutic interventions available for restoring motion and diminishing pain. The interventions includes non-steroid anti-inflammatory drugs, active and passive mobilization, oral steroids, intra-articular steroid injection, hydro-dilatation, manipulation under anaesthesia, suprascapular nerve block and arthroscopic capsular release. The ideal treatment for idiopathic frozen shoulder remains controversial even though many treatment options are described in literatures. In our study we found promising results in improvement in range of motion (both active and passive ROM) and pain, this may be attributed to reduction in synovial inflammation that decreases capsular fibrosis and hence, improving range of motion and relieving pain. Studies have reported reduction in capsular fibrosis following intra articular steroid injection in both short and long terms.<sup>13,14,15</sup> On the other hand, physical therapy and stretching of the capsule of the shoulder joint may have stretched the thickened capsule and restored flexibility. Studies have reported that physiotherapy and home based exercise program can be the first line of treatment in the treatment of idiopathic frozen shoulder.<sup>4</sup> Various studies shows intra-articular steroid with physiotherapy have better outcomes.<sup>15</sup> Physiotherapist instructs the patient with the standardized home exercise and encourages performing these three times each day and all patients were encouraged to continue performing their usual activities of daily living.<sup>16</sup> Supervised physiotherapy in intra-articular injection

provides faster improvement in shoulder ROM.<sup>15</sup> We have given exercises sketch chart (Fig. 1) and encouragement about those activities of daily living which can help to improve range of motion.

The side effects of intra-articular steroid include local reaction such as pain and swelling within 48 hours most likely resulting from a transient reactive synovitis, flare-up pain like pseudo-gout and pseudo-sepsism.<sup>17</sup> We found severe pain in eleven (15.7%) patient after using intra-articular solution; these patients were treated with oral Tramadol 50mg (S.O.S) along with the regime of five days of NSAIDS followed by physiotherapy. Such patients were also advised complete rest of shoulder (till pain subsided, physiotherapy was stopped for 2-3 days) and ice compression. We always gave intra-articular injection using aseptic technique after blood investigation and x-ray; however no treatment is without risk and cautiousness should be taken.

## CONCLUSION

The results of the study suggest that intra-articular methylprednisolone with oral NSAIDS, followed by physiotherapy and home based exercises are effective and results in promising clinical and functional improvement in pain and range of motion.

## RECOMMENDATION

Our study result recommends that combination of intra-articular methylprednisolone with five days NSAIDS supervised by physiotherapist for five day after injection and then home exercises is one of the better management for idiopathic frozen shoulder.

## LIMITATION OF THE STUDY

Our study was single centre study and had small sample size, so we recommend a larger sample size and multi-centric study with longer follow up.

## CONFLICT OF INTEREST

The authors declare no financial support or potential conflict of interest.

## ACKNOWLEDGMENT

We are grateful to Medical Superintendent Dr. Roshan Pokharel for his encouragement and supporting this study.

## FINANCIAL DISCLOSURE

None.

## REFERENCES

1. Koh KH. Corticosteroid injection for adhesive capsulitis in primary care: a systematic review of randomised clinical trials. *Singapore Medical Journal*. 2016 Dec; 57 (12):646. DOI: 10.11622/smedj.2016146.
2. Dias R, Cutts S, Massoud S. Frozen shoulder. *BMI: British Medical Journal*. 2005 Dec 17; 331 (7530):1453. PMID: 16356983.
3. Le HV, Lee SJ, Nazarian A, Rodriguez EK. Adhesive capsulitis of the shoulder: review of pathophysiology and current clinical treatments. *Shoulder & elbow*. 2017 Apr; 9 (2):75-84. DOI: 10.1177/1758573 - 216676786.
4. Chan HB, Pua PY, How CH. Physical therapy in the management of frozen shoulder. *Singapore Medical Journal*. 2017 Dec; 58 (12):685. DOI: 10.11622/smedj.2017107.



5. Biradar R, Nandi SS, Patel A, Pillai A. Intraarticular corticosteroid injection in adhesive capsulitis: are two doses better than a single dose? A randomized prospective study. *International Journal of Research in Orthopaedics*. 2016 Sep 3; 2 (3):159-63. DOI: <http://dx.doi.org/10.18203/issn.2455-4510.IntJResOrthop20163123>.
6. Rawat MS, Juyal A, Agrawal A. Evaluation of the role of intra-articular Steroid injection in frozen shoulder. *International Journal of Orthopaedics*. 2018; 4 (1):792-4. DOI: <https://doi.org/10.22271/ortho.2018.v4.i1l.113>.
7. Roach KE, Budiman-Mak E, Songsiridej N, Lertratanakul Y. Development of a shoulder pain and disability index. *Arthritis & Rheumatism: Official Journal of the American College of Rheumatology*. 1991 Dec; 4 (4):143-9. PMID: 11188601.
8. Tallia AF, Cardone DA. Diagnostic and Therapeutic Injection of the Shoulder Region. *South African Family Practice*. 2006 Jan 5; 48 (3):48. PMID: 12674455.
9. MacDermid JC, Solomon P, Prkachin K. The Shoulder Pain and Disability Index demonstrates factor, construct and longitudinal validity. *BMC musculoskeletal disorders*. 2006 Dec; 7 (1):12. DOI:10.1186/1471-2474-7-12.
10. Milgrom C, Novack V, Weil Y, Jaber S, Radeva-Petrova DR, Finestone A. Risk factors for idiopathic frozen shoulder. *The Israel Medical Association Journal*. 2008 May 1; 10 (5):361. PMID: 18605360.
11. Hollmann L, Halaki M, Kamper SJ, Haber M, Ginn KA. Does muscle guarding play a role in range of motion loss in patients with frozen shoulder? *Musculoskeletal Science and Practice*. 2018 Oct 1;37:64-8. PMID: 29986193.
12. Ajmal SM, Bashir MS, Burq SI, Ahmad A, Gilani SA. Comparison of Restricted Movement Pattern among Patients of Idiopathic, Diabetic and Traumatic Adhesive Capsulitis. *Annals of King Edward Medical University*. 2018 Jun 20;24(2):744-50. DOI: <http://dx.doi.org/10.21649/journal.akemu/2018/24.2.22-28>.
13. Marx RG, Malizia RW, Kenter K, Wickiewicz TL, Hannafin JA. Intra-articular corticosteroid injection for the treatment of idiopathic adhesive capsulitis of the shoulder. *HSS Journal*. 2007 Sep 1;3(2):202-7. PMID : 18751795.
14. Shekhar V, Reddy GV. Role of Intra Articular Steroid Injection In Early Adhesive Capsulitis of Shoulder. *IOSR Journal of Dental and Medical Sciences*. Volume 16, Issue 3 Ver. II (March. 2017), PP 38-4. DOI: 10.9790/0853-1603023840.
15. Bal A, Eksioglu E, Gulec B, Aydog E, Gurcay E, Cakci A. Effectiveness of corticosteroid injection in adhesive capsulitis. *Clinical Rehabilitation*. 2008 Jun;22(6):503-12. PMID: 18511530.
16. Kumar K, Thomas A, Tetsworth K, Hohmann E. Is there a short-term benefit from an intra-articular steroid injection in female patients with adhesive capsulitis of the shoulder treated with physiotherapy? *Journal of Orthopaedic Surgery*. 2017 Feb 16;25(1):2309499017690463. DOI: 10.1177/2309499017690463.
17. Gross C, Dhawan A, Harwood D, Gochanour E, Romeo A. Glenohumeral joint injections: a review. *Sports Health*. 2013 Mar;5(2):153-9. PMID: 24427384.

