

# Melanotrichoblastoma: A Rare Case Report from B. P. Koirala Institute of Health Sciences, Dharan, Nepal

Pokharel S,<sup>1</sup> Karki S,<sup>1</sup> Pradhan A,<sup>1</sup> Agrawal S<sup>2</sup>

## Affiliation

1. Department of Pathology, B. P. Koirala Institute of Health Sciences, Dharan-18, Sunsari, Nepal
2. Department of Dermatology & Venereology, B. P. Koirala Institute of Health Sciences, Dharan-18, Sunsari, Nepal

## ARTICLE INFO

### Article History

Received : 07 March, 2017

Accepted : 07 April, 2017

Published : 30 April, 2017

© Authors retain copyright and grant the journal right of first publication with the work simultaneously licensed under Creative Commons Attribution License CC - BY 4.0 that allows others to share the work with an acknowledgment of the work's authorship and initial publication in this journal.



CR 7

### \* Corresponding Author

Dr. Sairil Pokharel  
Assistant Professor  
Department of Pathology  
B. P. Koirala Institute of Health Sciences  
Dharan-18, Sunsari, Nepal  
Email: sairilp@gmail.com

## ABSTRACT

Melanotrichoblastoma is a variant of pigmented trichoblastoma. It shows heavily pigmented epithelial lobules and differentiation toward the hair bulb. Abundant dendritic melanocytes are found within the tumor masses. These melanocytes show positivity for S100 protein, HMG45/gp 100 and tyrosinase. The case is being reported because of its rarity.

A twenty eight year lady presented to Dermatology OPD with a single nodular lesion on the right temporal region since last five years. Punch biopsy was done. Haematoxylin and eosin stained slides were studied and immunohistochemistry analysis was also done.

Variably sized epithelial lobules of basaloid cells spanning the entire dermis was noted on H and E stained slides. Some lobules showed pale looking cells- a reminiscent of follicular germinative cells. Intralesional melanocytes with pigmentation were observed. Immunohistochemistry results showed the melanocytes positive for HMB-45 and S100 and the stroma positive for CD 34. Hence, a definitive diagnosis of Melanotrichoblastoma was made.

This case is being presented to emphasize the difficulty posed by adnexal tumors in clinical diagnosis due to their clinical similarity with malignant lesion and rarity.

## KEY WORDS

Pigmentation, melanocytes, epithelial cells

## Citation

Pokharel S, Karki S, Pradhan A, Agrawal S. Melanotrichoblastoma: A Rare Case Report from B. P. Koirala Institute of Health Sciences, Dharan, Nepal. BJHS 2017; 2 (1) 2 : 145-147.

## INTRODUCTION

Trichoblastomas (TBs) are benign skin adnexal tumors, under the category of trichogenic tumors. It shows proliferation of epithelial and mesenchymal cells which recapitulate the hair follicle development.<sup>1</sup> Melanotrichoblastoma is a type of pigmented trichoblastoma showing densely pigmented epithelial lobules and differentiation toward the hair bulb. Abundant dendritic melanocytes are found within the tumor lobules. On immunohistochemistry analysis, these dendritic melanocytes show positive expressions of S100 protein, gp100/HMB45 and tyrosinase.<sup>1</sup>

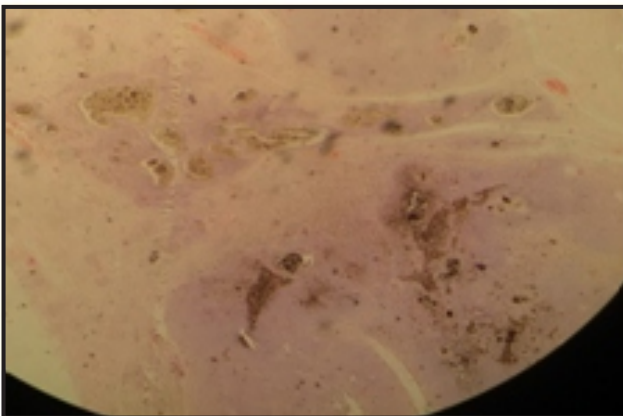
We are reporting this case due to its rareness and similarities with other neoplastic lesions of skin that can lead to diagnostic dilemma.

## CASE REPORT

A twenty eight year old lady, from the OPD of Dermatology, presented with a slowly growing, cauliflower-like, non tender, skin colored nodule on right temporal region since last five years. The lesion was excised with clinical differential diagnoses of melanocytic nevus and syringocystadenoma papilliferum. Punch biopsy specimen from lesion was stained with H and E stain and immunohistochemistry analysis was also done. The slides were evaluated with light microscopy. Gross examination revealed a lobulated, skin covered soft tissue of 2x2 cm size. Cut surface was solid, grey-white and soft.

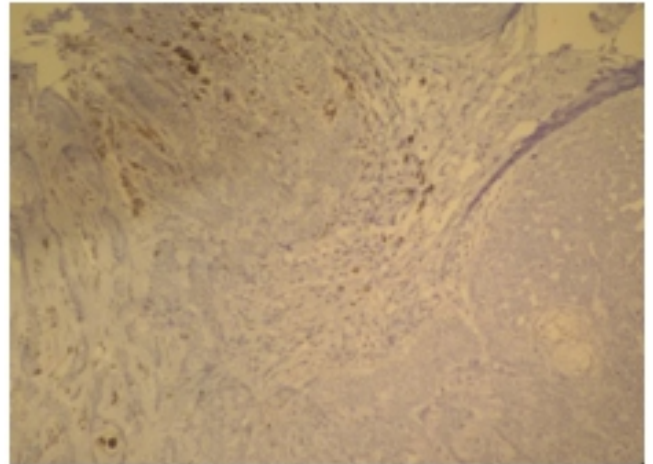
Microscopy of representative sections revealed variably sized epithelial lobules of basaloid cells spanning the entire dermis with no connections of tumor to the overlying epidermis. The tumor cells had oval nuclei with focal peripheral palisading and brisk mitotic activity. Some lobules showed pale looking cells- a reminiscent of follicular germinative cells. Dense deposits of melanin were seen within the tumor nests as well as around it. (Figure 1)

**Figure 1: Scanning magnification of the trichoblastoma (x100, Hematoxylin and eosin)**

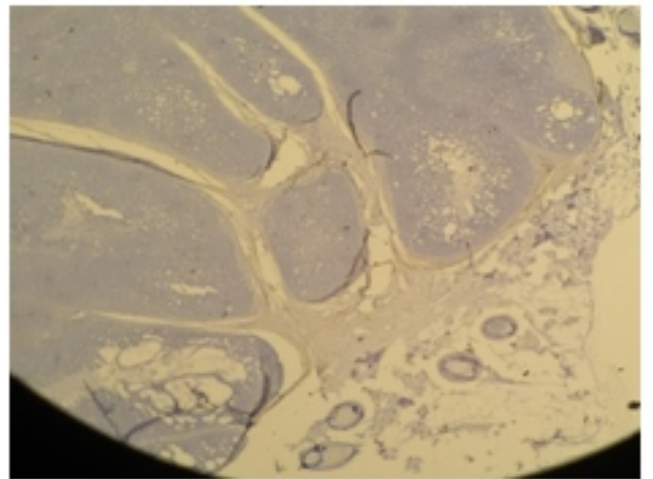


Immunohistochemistry results showed intralesional melanocytes positive for HMB-45 (Figure-2) and S100 and the stroma positive for CD 34 and CD10 (Figure-3). Bcl-2 oncoprotein was focally as well as weakly expressed. No expression of EMA and NSE were noted. PAS stain (with and without diastase) was negative. Hence, a definitive diagnosis of Melanotrichoblastoma was made.

**Figure 2: Dendritic melanocytes within tumor nests showing HMB 45 expression (x400)**



**Figure 3: Stromal expression of CD10 ( X 100)**



## DISCUSSION

Trichoblastoma is a rare, benign and slow growing tumor showing differentiation toward the primitive hair follicle. It presents clinically as a slowly growing nodule located predominantly in the head and neck region, most of the times involving scalp. Though it can be seen in all age groups, except children, people in fifth to seventh decade of life are mostly affected.<sup>2</sup> It can grow up to 3cm. Some cases can reach upto 8-10cm in size.<sup>3</sup>

Melanotrichoblastomas are most of the times mistaken for pigmented variant of basal cell carcinoma (BCC), melanoma/ melanocytic nevus. However these diagnosis were ruled out based on clinical and histopathological findings. Clinically,

the patient, a young lady, presented with a well circumscribed nodular lesion on the temporal region. Histological examination revealed thinned out epidermis overlying the tumor. Ulceration and dysplastic changes of epidermis were not observed. Important histological features of BCC like retraction spaces between tumor nests and surrounding stroma and connection with the overlying epidermis were not seen in our case.

Differentiation toward the hair germ is not found, and the pigmentation is restricted to the upper part of dermis in BCC<sup>3</sup>. Nuclei were monomorphous and showed no atypia. In a study done by Cordoba A et al, CD10 was found to be useful in identifying BCC with widespread follicular differentiation

and trichoblastomas. CD10 is expressed in peritumoral stromal cells in trichoblastomas whereas in BCCs epithelial staining is positive.<sup>4</sup>

Tumor nests showing dense melanin deposits within as well as around them and the proliferation of dendritic melanocytes having features of hair follicle melanocytes were the most striking features in this case.

### CONCLUSION

The case, melanotrichoblastoma, is being presented because of its rarity and increased chances of clinical misdiagnosis as melanotic neoplasm – nevus and melanoma.

### CONFLICT OF INTEREST

The authors declare no conflict of interest.

### REFERENCES

1. Kanitakis J, Brutzkus A, Butnaru AC, Claudy A. Melanotrichoblastoma: immunohistochemical study of a variant of pigmented trichoblastoma. *Am J Dermatopathol.* 2002;24:498–501
2. Brenn T, Mackee PH. Tumors of the hair follicle. In: Mackee PH, Calonje E, Granter SR, editors. *Pathology of the skin with clinical correlations.* 3<sup>rd</sup> ed. Elsevier Mosby; 2005. p. 15527.
3. Kadu S, Schaeppi H, Kerl H, Soyer HP. Subcutaneous trichoblastoma. *J Cutan Pathol* 1999;26:4906
4. Córdoba A, Guerrero D, Larrinaga B, Iglesias ME, Arrechea MA, Yanguas JI. Bcl-2 and CD10 expression in the differential diagnosis of trichoblastoma, basal cell carcinoma, and basal cell carcinoma with follicular differentiation. *Int J Dermatol.* 2009;48:713–7. c Pregnancy; A Meta-Analysis. *Contraception.* 1995; 52:337-341.