

SPECTRUM OF EXFOLIATIVE CYTOLOGY AT BIRAT MEDICAL COLLEGE TEACHING HOSPITAL

Shaukin S^{1*}, Kafle SU², Singh M³

Affiliation

1. Lecturer, Department of Pathology, Birat Medical College Teaching hospital.
2. Assosicate Professor and HOD, Department of Pathology, Birat Medical College Teaching hospital.
3. Assistant Professor, Department of Pathology, Birat Medical College Teaching hospital.

ARTICLE INFO

Received : 02 July, 2019

Accepted : 11 August, 2019

Published : 31 August, 2019

© Authors retain copyright and grant the journal right of first publication with the work simultaneously licensed under Creative Commons Attribution License CC - BY 4.0 that allows others to share the work with an acknowledgment of the work's authorship and initial publication in this journal.



ORA 123

DOI: <http://dx.doi.org/10.3126/bjhs.v4i2.25456>

* Corresponding Author

Dr. Shilpi Shaukin

Lecturer

Department of Pathology

Birat Medical College Teaching hospital.

Email ID : shilpiha20@gmail.com

ORCID ID : <https://orcid.org/0000-0003-0523-3666>

Citation

Shaukin S, Kafle SU, Singh M. Spectrum of Exfoliative Cytology at Birat Medical College Teaching Hospital. BJHS 2019;4(2)9: 734 - 737.

ABSTRACT

Introduction

Exfoliative cytological study of body fluids is easy, simple, rapid, cost effective and patient compliant investigation that helps in characterizing the disease into their varying subtypes. These presumptive and sometimes definitive diagnoses are in most cases the cornerstone which helps in staging and prognosis of the patient

Objective

To determine the spectrum of malignant and non-malignant lesions in exfoliative cytology

Methodology

This was a quantitative retrospective cross sectional study conducted at Birat Medical College Teaching Hospital from 24th December 2014 to 24th December 2018. All the exfoliative samples received at the lab were accepted in our study.

Results

Of the 300 samples received, the maximum number were those of sputum followed by pleural fluid and ascitic fluid. Peritoneal fluid, Cerebrospinal fluid, synovial fluid, fluid from suspected abscess and breast fluid were also received. Malignancy was found in 1.67% of the samples studies .

Conclusion

A study of different cytomorphological features of exfoliative cytology samples will help in establishing the role of cytology as an important diagnostic tool in improving the effectiveness of diagnosis , treatment & prognosis of the patient in the medical field.

KEY WORD

Body fluids, cytology, malignant effusions



INTRODUCTION

Historically the origins of cytology can be tracked back to the early 500 BC, when the first reports on visual morphological diagnosis during autopsy were compiled.¹ The invention of the microscope by Hans and his son, Zacharias Janssen, ushered in the era of microscopic examination and diagnosis.² German physiologist Johannes Peter Muller is considered to be the father of medical microscopy. He was the first to establish microscopic criteria for the differential diagnosis between benign and malignant neoplasms.³ Kun attempted for the first time to use a needle for diagnosing tumor in 1846.⁴ In 1853 the first microscopic examination of cells sampled via needle aspiration from breast tissue was conducted by Paget.⁵ In 1921 at the John Hopkins Hospital in Baltimore Guthrie started the use of air-dried films with Romanowsky staining.⁶

Malignant cells in sputum were observed for the first time in 1843 by Walter Hayle Walshe.⁷ Later in 1846 he illustrated cancer cells in sputum of a patient with lung cancer and in the vomitus of another patient with gastric cancer.⁸ Hampeln, in 1887, published the first case of primary carcinoma of the lung and pleura with an illustration of a drawing of cancer cells.⁹ In 1935, Dudgeon and Wrigley established the cytological examination of sputum for the diagnosis of cases with lung cancer.^{10,11} Quincke studied the properties of chylous fluids numerating the difficulties of examining such material.¹² An important advance in cytology was the use of air drained films by Paul Ehrlich in the identification of malignant cells not only in blood but also in various serous effusions.¹³ The discovery of lumbar puncture by Quincke in 1891 inaugurated the cytologic study of CSF.¹⁴ Widal and Ravaut in 1900 employed Romanowsky dyes in analyzing cytological preparations from pleural fluids.^{15,16}

From those humble beginnings cytological analysis today has become an indispensable pillar of modern medicine. This simple, rapid, cost effective and patient compliant investigation from various body fluids helps us in characterizing the disease into their varying subtypes. These presumptive and sometimes definitive diagnoses are in most cases the cornerstone which dictates the management plan of the patient. The cytological and physical examination by pathologists not only helps to ascertain the etiological agent but also helps in understanding the disease process and monitoring response to treatment.¹⁷

Body cavities bounded by epithelial lining maintain a minimum amount of fluid. The collection of excess amounts of fluids in these chambers are due to disproportionate formation and/or removal as governed by Starling's law.¹⁸ The various causes leading to effusions include infection, inflammation and malignancy. The major body fluids examined include those from the peritoneal, pleural, synovial, cerebrospinal and pericardial spaces.¹⁹

METHODOLOGY

This was a quantitative retrospective cross sectional study conducted at Birat Medical College Teaching Hospital from 24th December 2014 to 24th December 2018. All the exfoliative samples received at the lab were accepted in our

study. Urine samples were excluded from this study. All the samples were processed in a 3000 rpm centrifuge for five minutes. Following which 4 smears were prepared, 2 each were stained with Papanicolaou and Giemsa respectively. Each of the slides was examined by a minimum of two pathologists and then a conclusion was drawn. Data was collected and tabulated by using Microsoft Excel sheet and SPSS.

RESULTS

Of the 300 cases studied 57.3% were male and 42.7% were female as shown in table 1.

Table 1 : Frequency of gender distribution

Gender	Number	Percent
Male	172	57.33
Female	128	42.67
Total	300	100

Table 2 : Distribution of various types of samples received

Sample	Number	Percent
Sputum	184	61.33
Pleural	53	17.67
Ascitic	41	13.67
Peritoneal	7	2.33
CSF	6	2.00
Synovial fluid	4	1.33
Abscess	4	1.33
Breast	1	0.33
Total	300	100

The gender distribution in accordance to each sample type is expressed in table 3.

Table 3 : Gender distribution according to each sample type

Sex	Sputum	Pleural	Ascitic	Peritoneal	CSF	Synovial	Abscess	Breast	Total
Male	105	34	21	3	4	3	2	0	172
Female	79	19	20	4	2	1	2	1	128
Total	184	53	41	7	6	4	4	1	300

On categorizing the samples on the basis of their age groups maximum cases belonged to the age group of 70 to 80 years. These were 74 cases comprising 24.67% of the total sample size. Ages ranged from a 4 day old child up to 95 years. Mean age of the study population is 57.8 years with a median age of 62 years and a standard deviation of 18.61. Samples and their frequency in each age group are shown in the table 4 below.

Table 4 : Distribution of different types of specimen according to age group

Age	Sputum	Pleural	Ascitic	Peritoneal	CSF	Synovial	Pus	Breast	Total	Percent
0-10	0	0	0	0	1	0	1	0	2	0.67
10-20	3	2	1	0	1	0	1	0	8	2.67
20-30	5	5	3	0	1	2	0	0	16	5.33
30-40	6	5	13	1	0	2	0	1	28	9.33
40-50	19	5	7	4	0	0	0	0	35	11.67
50-60	21	12	5	2	2	0	1	0	43	14.33
60-70	56	6	5	0	0	0	0	0	67	22.33
70-80	53	16	4	0	1	0	0	0	74	24.67
80-90	19	2	1	0	0	0	1	0	23	7.67
90-100	2	0	2	0	0	0	0	0	4	1.33
Total	184	53	41	7	6	4	4	1	300	



Sputum: The diagnosis of the sputum samples were classified into benign and suspicious. In benign category it was subdivided into 174 descriptive cases, 4 fungal, 2 reactive and one each inflammatory and lymphocytic. The remaining 2 were in the suspicious category as shown in table 5.

Sputum Diagnosis	Number	Percentage
Descriptive	174	94.56
Fungal	4	2.17
Reactive	2	1.09
Suspicious	2	1.09
Inflammatory	1	0.54
Lymphocytic	1	0.54

Pleural fluid: Samples were examined under microscope and classified as Benign, Malignant and Metastatic adenocarcinomas. Under benign a subcategorisation was done into Descriptive, Lymphocytic, Inflammatory, Reactive, Neutrophilic as shown in table 6.

Pleural fluid Diagnosis	Number	Percentage
Descriptive	23	43.39
Lymphocytic	12	22.64
Inflammatory	10	18.87
Reactive	3	5.67
Malignant	2	3.77
Neutrophilic	2	3.77
Mets adeno	1	1.89
Total	53	100

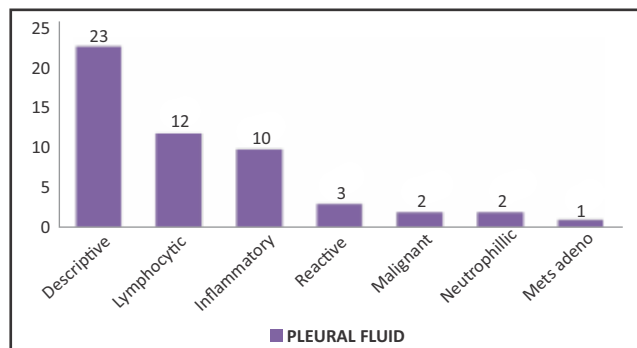


Figure 1: Spectrum of diagnosis in pleural fluid samples

Ascitic fluid: The ascitic fluid samples on analysis were found to be benign in most cases which were further classified into descriptive, inflammatory, lymphocytic and reactive. Other diagnosis obtained ten, metastatic adenocarcinoma as represented in table 7.

Ascitic fluid Diagnosis	Number	Percent
Descriptive	30	73.17
Inflammatory	6	14.63
Lymphocytic	2	4.88
Mets adeno	1	2.43
Reactive	2	4.88

Others: All 7 of the peritoneal fluid samples were benign, 5 of these were descriptive, while 1 sample each was categorized as hemorrhagic and inflammatory. Of the 6 CSF samples 3 were lymphocytic, 2 descriptive and 1 inflammatory. Fluid obtained from 4 suspected abscess lesions showed suppuration in 3 of them while 1 was inflammatory. Synovial fluid on analysis showed 3 inflammatory samples and 1 infective. The single Breast fluid sample obtained was malignant.

The total number of samples with a diagnosis of malignancy was five. There were two sputum samples which were reported as to be suspicious of malignancy. Of all the five malignant samples two were pleural fluid samples and 1 was the breast fluid sample. The remaining two were metastatic adenocarcinomas seen in one ascitic fluid and one pleural fluid respectively.

	Khatib et al	Gupta et al	Maharjan et al	Shrestha et al	Pradhan et al
Number of samples	414	185	1129	385	584
Sex ratio	1:1	1.6:1	1.33:1	1.56:1	NA
Most common age group	40 - 50	30 - 40	50-59	31-40	NA
Most common sample	Peritoneal	Peritoneal	Pleural	Peritoneal	Peritoneal
Malignancy reported	7.48%	5.4%	5.8%	2.59%	18.66%
Malignancy in pleural fluid	9.42 %	5.47%	3.8%	6.38%	19.64%
Malignancy in Ascitic Fluid	9.52%	5.43%	5.8%	2.29%	18.8%

DISCUSSION

We studied a total of 300 cases, over 60 percent of which were sputum samples. The male to female ratio in our study was 1.34 which is comparable with other similar studies.²⁰⁻²⁴

The cases were most in the 70 to 80 age group (24.67%). 109 of the 184 sputum samples were patients in their seventh to eighth decades.

Of the aspirated samples pleural aspirates (17.67%) were the most in number followed closely by ascitic fluid (13.67%) and peritoneal wash (2.33%). Peritoneal fluid and pleural fluids form the most common samples as examined by other authors.²⁰⁻²⁴

Malignancy was reported in 1.67 % of all the samples we studied. 3 of these were pleural fluid samples while 1 each was from an ascitic tap and breast fluid. Of the 5 cases, 2 were metastatic adenocarcinoma while the others could not be characterized. The percentage of malignancy in other studies range from 2.59% to 18.66%.²⁰⁻²⁴ Similar data were reported by other studies where the most commonly diagnosed malignancy was Adenocarcinoma and the sample were mostly obtained from either the peritoneal or pleural fluid.²⁰⁻²⁴ Two of our samples of sputum were suspicious of malignancy. In these two cases further imaging and image guided biopsy were advised.

A total of 5.66% of pleural fluid and 2.43% of ascitic fluid samples were shown to be malignant. Pleural fluid samples showed malignancy rates from 3.8% to a maximum of

19.64%.²⁰⁻²⁴ Ascitic fluid analysis in other studies showed malignancy percentages ranging from 2.29% to 18.8%.²⁰⁻²⁴

CSF formed 2 % of our total sample case which was similar to other studies.^{20,23,24} Khatib et al and Shulbha et al had a higher number of CSF samples, 15.4% and 25.97% respectively.^{21,22} None of these studies showed malignancy which was similar to our study.

Synovial fluid samples were 1.33% of our sample size, similar to other studies.^{20-22, 24} Gupta et al showed a higher percentage of synovial fluid samples 6.4%.²³ 75 % of our synovial samples were inflammatory as corroborated in his study by Ostovicetal²⁶. We found no malignancy in our synovial fluid analysis as was the case in the other studies which is in keeping with the nature of tumor cells to rarely infiltrate the joint.²⁶ The findings of other similar studies on exfoliative samples are shown in the table 8.

CONCLUSION

Exfoliative cytology should be suggested in all cases of effusion and suspected malignancies which helps in reaching at a particular diagnosis and aids in further

management. Besides these tests, application of cytospin and applying tumor markers to these exfoliative samples can further increase the gamut of these tests.

Limitations of the study : Lack of Cytospin Slides
Lack of special stains

ACKNOWLEDGEMENT

We would like to acknowledge Dr. Surya Parajuli for his technical assistance.

CONFLICT OF INTEREST

None declared

FINANCIAL DISCLOSURE

No funding sources

ETHICAL APPROVAL

The study was approved by the Institutional Review Committee, Birat medical college

REFERENCES

- Underwood JCE. Introduction to Pathology. Part I: General and Systematic Pathology. Edinburgh: Churchill Livingstone; 2004. p 4. Doi = {10.1002/dc.22887}
- Hajdu SI. Cytology from antiquity to Papanicolaou. *Acta Cytol* 1977;21:668–676. PMID:341630
- Haggard HW. The conception of cancer before and after Johannes Muller. *Bull NY Acad Med* 1938;14:183–197. PMID: 19312055
- Kun M. A new instrument for the diagnosis of tumors. *Month J Med Sci* 1847;7:853–854. doi = {10.1002/dc.22887}
- Paget J. Lectures on Tumors. London: Longman; 1853. doi = {10.1002/dc.22887}
- Guthrie C. Gland puncture as a diagnostic measure. *Bull Johns Hopkins Hospital* 1921;32:266–269.
- George Nicholas Papanicolaou (1883–1962). *CA Cancer J Clin* 1973;23:171–173. doi = {10.1002/dc.22887}
- Walshe W. The Nature and Treatment of Cancer. London Taylor and Walton; 1846. <https://archive.org/details/b21307659/page>
- Hampeln P. U" bereinen Fall von prima"renLungen-Pleura-Carinom. *St. Petersburg med Wochenschr* 1887;12:137. Doi = {10.1002/dc.22887}
- Dudgeon LS, Barrett N. The examination of fresh tissues by the wet-film method. *Br J Surg* 1934;22:4–22. <https://doi.org/10.1002/bjs.1800228503>
- Dudgeon LS, Patrick SV. A new method for the rapid microscopical diagnosis of tumours: with an account of 200 cases so examined. *Br J Surg* 1927;15:250–261. <https://doi.org/10.1002/bjs.1800155810>
- Quincke H. U" berfethaltigeTranssudate: HydropsChylosus and HydropsAdiposus. *Dtsch Arch Klin Med* 1875;16:121–139. doi = {10.1002/dc.22887}
- Ehlich P. Beitr"ag zur A" tiologie und Histologiepleuritischer Exsudate. *Charite'-Annalen* 1882;7:199–230. doi = {10.1002/dc.22887}
- Quincke H. U" ber Hydrocephalus, Verhandlungen des Congressus fur innereMedizin, Vol10. Wiesbaden: JF Bergman; 1891. doi = {10.1002/dc.22887}
- Widal F, Ravaut P. Applications cliniques de l'etudehistologique des e'panchementsse'ro-fibrineux de la ple'vere. *C R SocBiol* 1900; 52:648,651,653. doi = {10.1002/dc.22887}
- Widal F, Sicard JA, Ravaut P. A propos du cytodagnostic du tabes. *Rev Neurol* 1903;11:289–292. doi = {10.1002/dc.22887}
- EnaDowerah, Sandip Das. Cytological evaluation of peritoneal fluid with special reference to malignancy. *International Journal of Biomedical Research*. 2014;5(6):396-399DOI: <https://doi.org/10.7439/ijbr.v5i6.668>
- Kumavat PV, Kulkarni MP, Sulhyan KR. Cytological study of effusions. *Indian Medical Gazette*. 2013;August:306-313. <http://medind.nic.in/ice/t13/i8/icet13i8p306.pdf>
- Nguyen G. Essentials of fluid cytology. 2009:9-71. <https://pathology.ubc.ca/files/2012/06/FLUIDCYTOLOGYBook09R1.pdf>
- Maharjan, S., Ranabhat, S., Tiwari, M., Bhandari, A., Osti, B., & Neopane, P. (2017). Exfoliative cytology analysis from different sites of the body. *Journal of Chitwan Medical College*, 7(2), 33-39. <https://doi.org/10.3126/jcmc.v7i2.23674>
- Khatib M W , Patel M P, Demde B R, Aher C V. Exfoliative cytology of body fluids: an analysis. *Asian Pac. J. Health Sci.*, 2016; 3 (4):117-119. doi: 10.21276/apjhs.2016.3.4.18
- Shulbha V S, Dayananda B S. Cytology of body fluids - an aid to primary diagnosis. *Indian Journal of Pathology and Oncology*, April-June 2015;2(2);81-83 <https://pdfs.semanticscholar.org/50ca/ff87db1a478b8a745bc06ee277e1ebd7cdb9.pdf>
- Gupta R, Dewan D, Raina R, Gupta M. Exfoliative cytology of body fluids: a study from provincial hospital of Gupta et al region, India. *Int J Res Med Sci* 2016;4:1016-9. DOI: <http://dx.doi.org/10.18203/2320-6012.ijrms20160720>
- Pradhan S B, Pradhan B , Dali S Cytology of body fluids from different sites: An approach for early diagnosis of malignancy *J Nep Med Assoc* 2006; 45: 353-356 PMID: 17676071
- Ostović KT, Kaić G, Ostović I, Skoro M, Novak NP, Morović-Vergles J. The importance of urgent cytological examination of synovial fluids in differentiation inflammatory and noninflammatory joint diseases. *CollAntropol* 2010;34(1):145–52. PMID:20432743

