

Case Report

## ROLE OF LOW-LEVEL NITROGEN LASER THERAPY IN TUBERCULAR COLD ABSCESS NOT RESPONDING TO SURGERY & CHEMOTHERAPY A SERIES OF CASE REPORT

Jain N K<sup>1</sup>, Bajpai A<sup>2</sup>, Avashia S<sup>3</sup>, Gupta P K<sup>4</sup>

<sup>1</sup> MBBS, DTCD, Research Associate

Department of Respiratory Medicine, M. G. M. Medical College, Indore

<sup>2</sup> MD, DTCD, Professor of Chest and TB

Head, Department of Respiratory Medicine, M. G. M. Medical College, Indore

<sup>3</sup> MD, DTCD, Assistant Professor

Department of Respiratory Medicine, M. G. M. Medical College & M. Y. Hospital, Indore

<sup>4</sup> Laser Biomedical Applications and Instrumentation Division,

Raja Ramanna Center for Advanced Technology (RRCAT), Indore

### ABSTRACT

**Background:** Tubercular empyema is one of the commonest chronic diseases in the developing countries of the world including India. As the problem of drug resistant strain of *tubercular bacilli* is increasing, new modalities of treatment that could act against resistant strain are needed.

**Objective:** The purpose of this study was to evaluate the efficacy of low-level nitrogen laser therapy (LLLT) as an adjuvant to anti-tubercular treatment in case of tubercular empyema that was not responding to conventional anti-tuberculosis drugs and repeated pus aspiration.

**Patient:** The patient, a 19 year old male was diagnosed with tubercular empyema. He was not improving by conventional treatment and pus aspiration. The patient was administered intralesional nitrogen laser (337 nanometer, average power 5 mW) for 780 seconds at intervals of 72 hours up to 10 weeks.

**Results:** After the fifth laser irradiation session, decrease in chest pain was reported and pus mixed with blood pleural fluid aspirated. After the tenth laser irradiation session, serous pleural fluid was aspirated. After 20 sessions of laser irradiation the empyema was healed completely and the patient also regained almost complete expansion of lung.

**Conclusion :** LLLT was observed to results in the healing of the tubercular empyema and also found to make the empyema free of *Mycobacterium tuberculosis*. However, further randomized studies with more patients are needed to prove the efficacy of this method.

**Key words:** -*Mycobacterium tuberculosis*, empyema, laser

### Correspondence:

Dr. Nageen Kumar Jain, MBBS, DTCD  
Research Associate, Department of Medicine  
M. G. M. Medical College, Indore, India  
Telephone: 0731 2366642  
Mobile: 09826093544  
Fax No. 0731 2512500  
E-mail: jain\_nageen@yahoo.co.in

### INTRODUCTION

Tuberculous empyema presents a more difficult problem, since the lung and pleura are usually involved with irreversible pathological changes which make expansion and proper functioning of the lung impossible. However, it appeared theoretically possible that if tuberculous empyema were treated at an early stage, before irreversible changes took place that a cure might be obtained.

This report deals with the successful treatment of a patient with tuberculous empyema by use of low level laser therapy.

## CASE REPORT

A 19-year-old male, was admitted on February 2008 with two weeks history of high grade fever, dry cough and left sided chest pain. Patient had been treated for sputum positive pulmonary tuberculosis from April 2007 to October 2007. History of contact with known tuberculous patient was positive. He had received Isoniazid (INH) 600 mg, Rifampicin (RIF) 600mg, Ethambutol (EMB) 1200 mg, Pyrazinamide (PZA) 1500 mg Directly Observed Treatment, Short course (DOTS Category-I).

On general examination, he was cachectic, febrile, trachea shifted towards right side. Systemic examination revealed dull percussion on left side of chest. Auscultation of chest revealed breath sound absent in left chest.

A full blood examination showed Haemoglobin of 11.6gm%, white cell count 12,700, Erythrocytes Sedimentation Rate of 30mm at the end of 1<sup>st</sup> hour. Blood sugar, urea, creatinine were normal. Human Immunodeficiency Virus, T- cell interferons were negative and Tubercular antibody were positive. Thick pus from pleural cavity showed acid-fast bacilli (AFB) in Ziehl Neelsen (ZN) staining. Culture on Lowen stein – Jensen slopes(L-J) was negative but Deoxyribo Nucleic Acid testing for *Mycobacterium tuberculosis* amplified using the polymerase chain reaction (PCR) was positive. Sputum for acid-fast bacilli was negative on ZN staining. Culture of sputum on L-J slopes was negative. Culture for pyogenic organisms was negative. X-ray of chest revealed homogenous opacity left side of chest with shifting of the mediastinum towards right side (Figure-1).

After confirmation of the diagnosis, patient was put on DOTS category –II along with repeated aspiration because patient was not ready for intercostal tube drainage. In spite of this treatment for 2 months, amount of pleural fluid was increasing radiologically and patient deteriorated clinically.

The study has been approved by institutional review board. After obtaining the informed consent, we gave

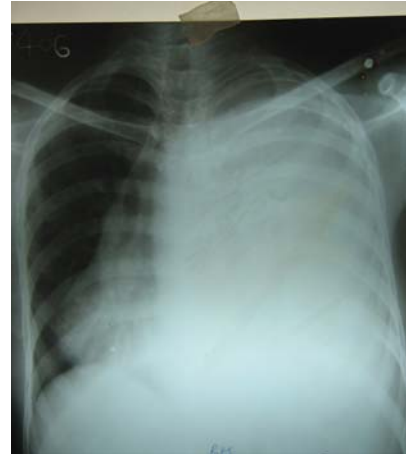

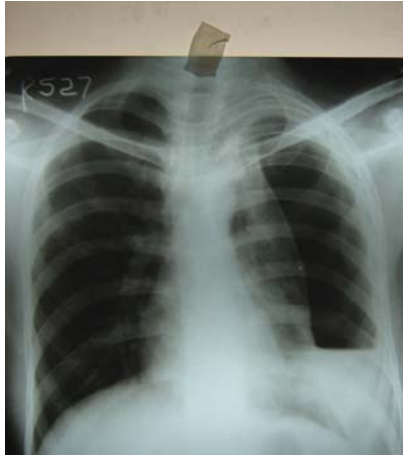
Fig. 1: X-ray of chest showing homogenous opacity left side of chest with shifting of mediastinum to right side.

intrapleural laser therapy along with continuation of DOTS category-II. The intrapleural laser therapy required local anesthesia. The nitrogen laser used in this study (wave length 337 nm, energy 300 microjoules and an average power output of 5 mW at the tip of the fiber) was manufactured by Raja Ramanna Center for Advanced Technology, Indore, India.

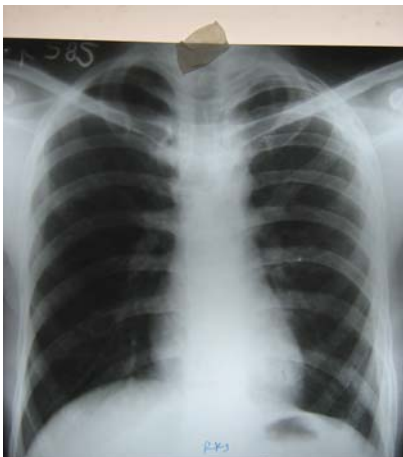
The empyema was exposed to nitrogen laser irradiation for 780 seconds at 72 hours interval for total 20 sitting. For laser irradiation the sterilized jalco canula (16 Gauge, 50 mm length) was introduced inside the pleural cavity and after aspiration of fluid from pleural cavity, the optical fiber of the laser equipment was introduced into the pleural cavity. At each session whole of the plural cavity was irradiated.

After the fifth laser irradiation session, decrease in chest pain was reported and pleural fluid aspiration became pus mixed with blood. After the tenth laser irradiation session, serous pleural fluid aspirated. After 20 sessions of laser irradiation the empyema was healed completely, PCR for M.TB complex negative and the patient also regained almost complete expansion of lung. Follow-up x-rays of chest revealed resolution of empyema on left side of chest and complete expansion of left lung (Figure-2 and 3).

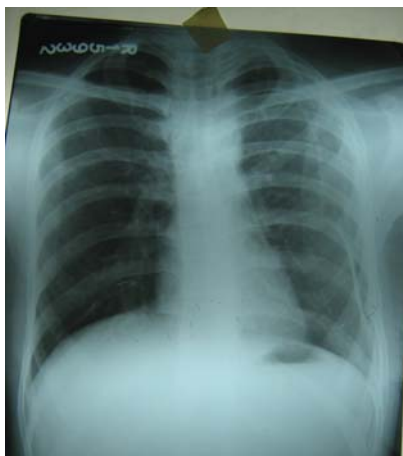Patient develops left sided mild pneumothorax after two months of stopping treatment which was managed conservatively. There was no recurrence of disease during 2 years of follow up.



**Fig. 2:** X-ray of chest showing left sided hydropneumothorax



**Fig. 3** X-ray of chest showing complete resolution of empyema



**Fig-4** X-ray of chest showing left sided mild pneumothorax

## DISCUSSION

This study was motivated by the encouraging results obtained earlier by us on the use of low level nitrogen laser therapy in chronic pulmonary tuberculosis

non-responding tubercular lymphadenopathy and sinus.<sup>1,2,3</sup> Results of the case study showed that patient who had received antitubercular treatment 2 months and had been aspirated showing no response to the therapy responded to intrapleural nitrogen laser irradiation. The exact mechanism of therapy by nitrogen laser irradiation is not clearly understood. The high intensity focused nitrogen laser irradiation has been shown to lead to direct inhibition of bacteria.<sup>4</sup> Even low intensity nitrogen laser irradiation has been shown to result in significant changes in fluidity of lipid regions in cell wall of laser-exposed cells which could affect infectivity of *mycobacterium tuberculosis* in the host.<sup>5</sup> Experiments also suggest that nitrogen laser irradiation can influence the immune response. For example nitrogen laser irradiation was observed to enhance the intracellular killing of internalized bacteria in human neutrophils.<sup>6</sup> However; more work is required for a more clear understanding of the mechanisms involved in the observed therapeutic effect of nitrogen laser irradiation.

## SUMMARY

A patient with tuberculous empyema and non-expandable lung was treated by the intra pleural low level laser therapy. LLLT resulted in prompt expansion of the lung and disappearance of the empyema. The LLLT may be specific in the treatment of tuberculous empyema when used before irreversible pathological changes have taken place.

## CONCLUSION

Nitrogen laser irradiation was observed to result in the healing of the tubercular empyema which was not responding to conventional antitubercular and pus aspiration. The laser irradiation was also found to make the fluid free of *mycobacterium tuberculosis*. Further randomized studies with more patients are therefore, desirable to establish this mode of therapy for the treatment of tubercular empyema.

## ACKNOWLEDGEMENT

We thank Shri. S.Sendhil Raja , SO/E / Laser Biomedical Applications and Instrumentation

---

Division, Raja Ramanna Center for Advanced Technology, Indore, India and his team for providing the Nitrogen Laser instrument. This project was funded by Board of Research in Nuclear Sciences, (BRNS) Mumbai.

## REFERENCES

1. Bajpai A, Jain N, Avashia S, Gupta P.K. Randomized, double-blind study on role of low level nitrogen laser therapy in treatment failure tubercular lymphadenopathy, sinuses and cold abscess" Indian J Tuberculosis, 2010; 57, 80-86
2. Bajpai A, Bhargava. S, Jain N, Gupta P.K. Role of low level nitrogen laser therapy in chronic drug resistant pulmonary tuberculosis. Indian Journal of Tuberculosis, 2006; 53, 135-140.
3. Bajpai A, Bhargava S, Gupta P.K., Jain N. Role of low level nitrogen laser therapy in the treatment of nonresponding tubercular lymphadenopathy and sinuses. Indian Journal of Tuberculosis, 2006; 53, 229-231.
4. Sachdeva R, Bhagwanani N.S., Chitnis, D.S. The nitrogen laser inhibits the growth of wide range of microbes in vitro. Laser therapy, 1995; 7, 23-26.
5. Dube A, Jayasankar K, Prabakaran L, Kumar V, Gupta P.K. Nitrogen laser irradiation (337 nm) causes temporary inactivation of clinical isolates of Mycobacterium tuberculosis. Laser in Medical Science, 2004; 19, 52-56.
6. Sachdeva R, Bhagwanani N.S., Chitnis, D.S. Low incident energy levels enhances the biocidal activity of human neutrophils on internalized bacteria: an in vitro study. Laser therapy; 1995; 7, 107-112.