

Beauty of Distalization – Case Series

Dr. Amit Prakash¹, Dr. Chandni Bharti², Dr. Jijo C Eapen³, Dr. Saumya Upahayay⁴, Dr. Bhagyashree Nayak⁵

¹Professor, Department of Orthodontics & Dentofacial Orthopedics, Awadh Dental College and Hospital, Jamshedpur

²Reader, Department of Orthodontics, People's Dental academy, Bhanpur, Bhopal

³Consultant Orthodontist, Trivandrum. Kerala

⁴Assistant Professor. Department of Orthodontics & Dentofacial Orthopedics, Peoples Dental Academy, Bhanpur, Bhopal

⁵Post graduate student, Ayodhya Bypass, Bhopal

Corresponding author: Dr. Chandni Bharti; Email: drchandnibharti@gmail.com

ABSTRACT

Maxillary molar distalization has been in used in orthodontics over a centennial. This approach has been used to attain space in the maxillary arch for relief of crowding, correction of Class II molar relationship and reduction of an increased overjet. This article reports the successful use of five molar distalization appliances, they are; the pendulum, distal jet, K- loop molar distalizer, double-loop Ni-Ti and the C- space regainer. All the five patients were in the age group of 12-20 years, who had Class II molar relationship with mild overjet and normal mandibular arch. In all the five patients maxillary molar distalization was efficient in correcting the borderline Class II malocclusion. Pendulum appliance was more efficient than others because it is easy to fabricate, cost-effective, less frequent activation and minimum anchorage loss. The practitioner requires a thorough understanding of the clinical indications of this procedure so that undue side effects can be minimized along with better incorporation in the orthodontic patient care.

KEYWORDS: C- space regainer. Distal jet, K-loop molar distalizer, Double-loop Ni-Ti appliance Pendulum appliance

INTRODUCTION

Correction of Class II malocclusion without extractions requires maxillary molar distalization by means of intraoral or extra-oral forces¹. For cases with minimal arch length discrepancy and mild Class II molar relationship associated with a normal mandibular arch, molar distalization is of significant value. Conventional extraoral traction has been successful in correcting Class II malocclusion, either by restraining forward growth of the maxilla or by distalizing maxillary molars. However, these appliances rely partially or totally on patient cooperation. This is the reason why clinicians often prefer intraoral distalization appliances that minimize the need for patient cooperation.

Numerous alternative intraoral noncompliant appliances such as pendulum¹, the distal jet², the K-loop molar distalizer³, Double loop NiTi⁴ and C space regainer⁵ have been developed, and many well-documented studies have substantiated their effects.

These appliances have drawbacks of anchor loss, proclination of the maxillary incisors, tipping of the maxillary molars, and difficulty in keeping the molars in position following distal movements. Space is easier to gain in the maxillary arch than in the mandible because of increased trabecular structure of supporting bone and increased anchorage afforded by palatal vault.

Indications for distalization¹⁻³

1. Class II or end on molar relationship
2. Mixed or permanent dentition
3. Mild to moderate crowding in maxillary arch
4. Hypodivergent or average growth pattern
5. Well aligned teeth or mild crowding in mandibular arch
6. Straight profile
7. Functional – Normal TMJ
8. Skeletal-Class I skeletal pattern
-Normal/short lower face height
9. Loss of arch length due to premature loss of second deciduous molar

Contraindications

1. Temporomandibular Joint disorder
2. Class II skeletal jaw base
3. Skeletal open bite
4. Excess lower face height
5. Dental: Class I or III molar relation.
6. Dental open bite/shallow bite

In this article five cases are presented in which maxillary molar distalization was carried out using five different distalization appliances. In these cases, maxillary molar distalization was efficient in correcting the borderline Class II cases. Regardless of different techniques available, one should think several issues before considering any of these appliances for use especially side effects, arch length, treatment timing and patient co-operation.

CASE 1

A 12 years old male patient presented with the chief complaint of crowded teeth. He had endomorphic body type, convex profile with low FMA angle, Class II molar relation with upper and lower anterior crowding along with deviated midline (Fig 1 and 2). Pendulum appliance was used in this case to correct the Class II malocclusion. Maxillary molar distalization was completed in five months. Space gained in right side was 7 mm and left side 5.5 mm (Fig 3 and 4). The rate of distalization was almost 1mm per month. Overcorrection of Class II molar relation was done, and Nance button was given to hold the gained space. Headgear was given for uprighting of molars.

Dentoalveolar changes observed in this case include maxillary molar distalization with distal crown tipping and intrusion, mesial movement of premolars, and anterior anchorage loss.

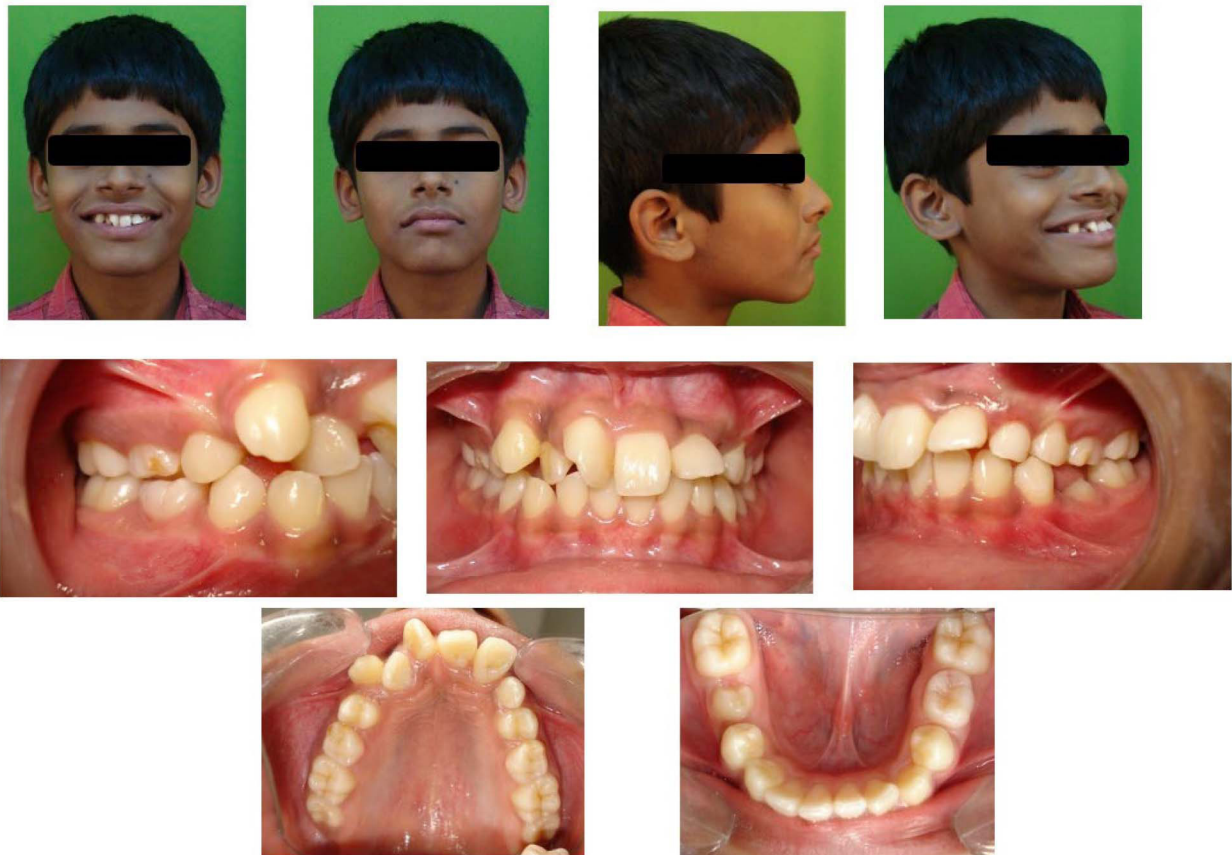

Fig. 1 Pre-treatment photographs

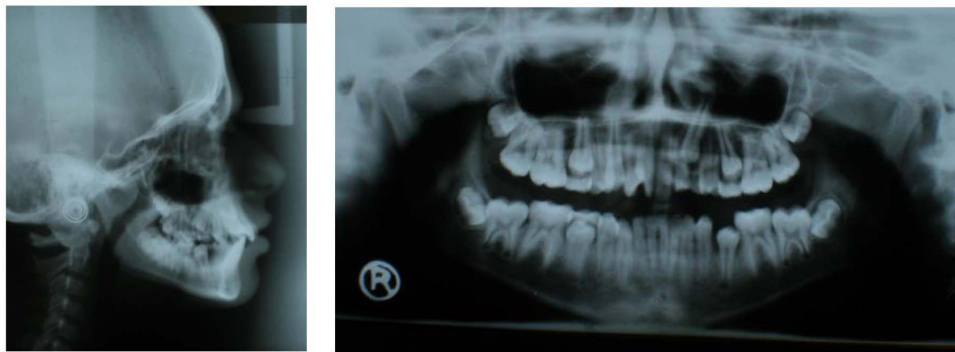


Fig. 2 Pre-treatment lateral cephalogram and orthopantomogram

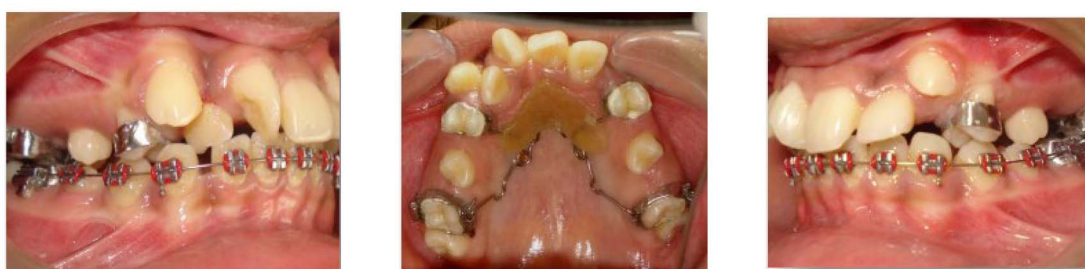

Fig. 3 Post distalization photographs

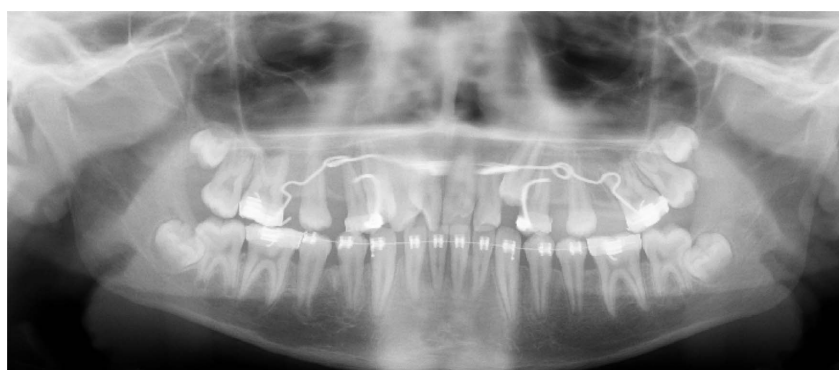

Fig. 4 Post distalization orthopantomogram

CASE 2

A 14 years old female patient presented with the chief complaint of crowded teeth. She was mesomorphic with straight profile and low FMA angle, Class II molar relation with upper anterior crowding (Fig 5 and 6). Space analysis suggested 6 mm of discrepancy in upper arch and 2 mm in lower arch. Treatment objectives were to relieve the crowding in both the arches, and correction of the molar relationship. She had missing central incisor on upper left side; our objective was to replace it with fixed prosthesis. Treatment plan was to distalize the upper first molars with the distal jet appliance and fixed

mechanotherapy with the PEA appliance to achieve good occlusion and soft tissue profile. This appliance was used because it gives good soft tissue changes and also dentoalveolar corrections are satisfactory. After cementation of Distal jet appliance in upper arch, activation was done with allen wrench. Space gained after eight months was 5 mm on the right side and 6mm on the left side (Fig 7). The rate of distalization was less than 1mm per month, but molar distalized bodily with very minimal anchorage loss.

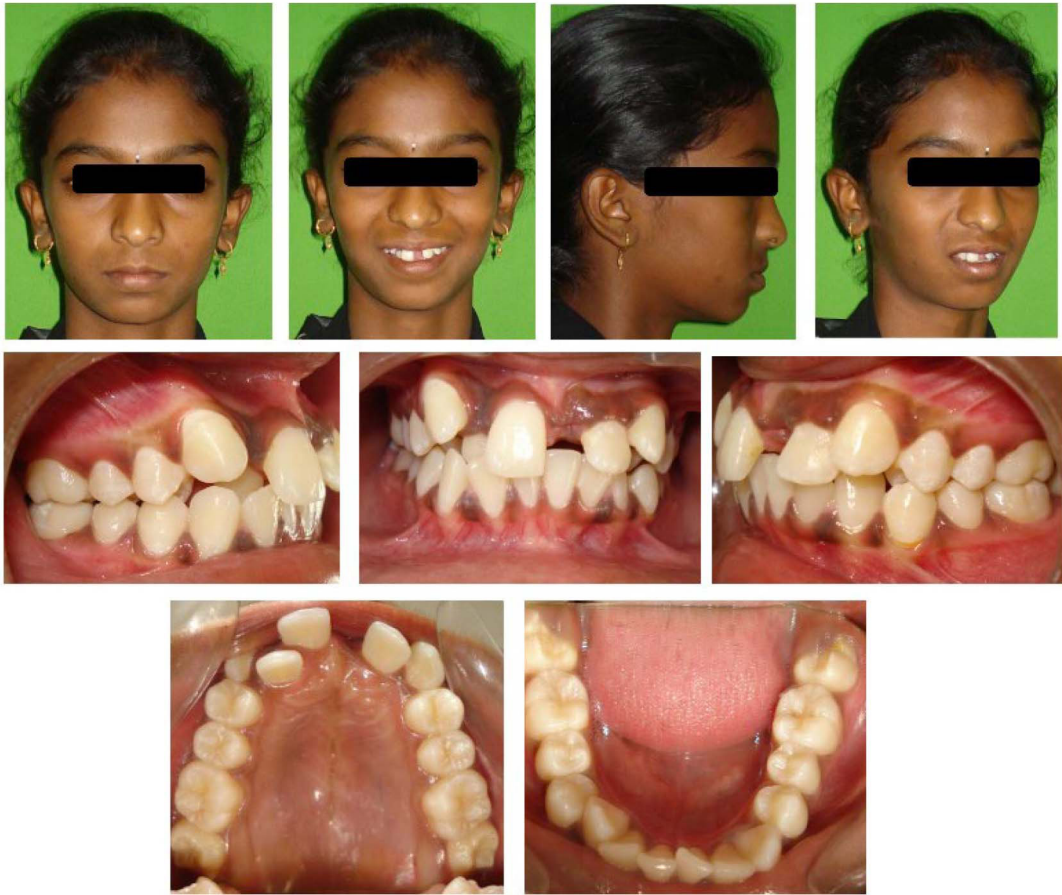

Fig. 5 Pre-treatment photographs

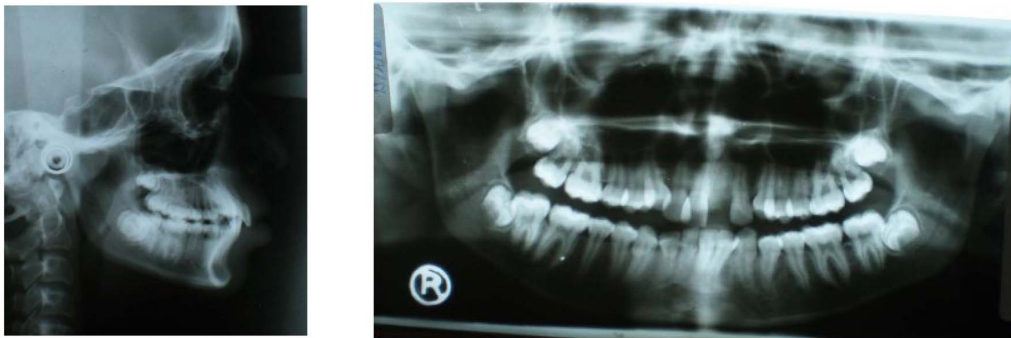

Fig. 6 Pre-treatment lateral cephalogram and orthopantomogram

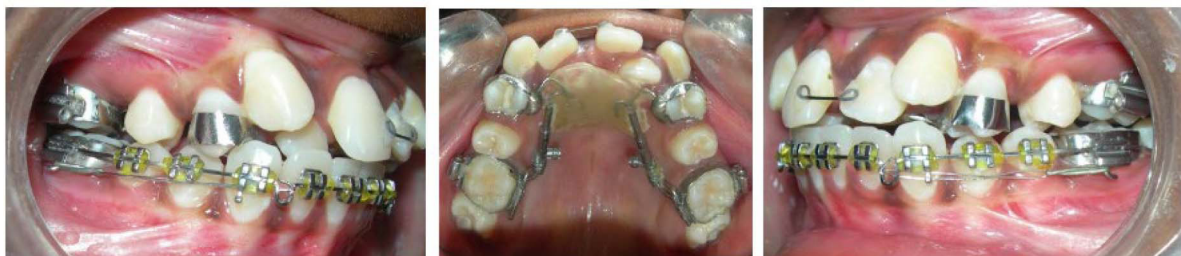

Fig. 7 Post distalization photographs

CASE 3

A 17 years old female patient presented with the chief complaint of forwardly placed teeth. She was mesomorphic, convex profile with average FMA, Class II molar and canine relationship on the right side and deep bite (Fig 8 and 9). Space analysis showed 1 mm of spacing in the upper arch and no discrepancy in the lower arch. The treatment objective was to correct the molar

relationship, midline deviation, overjet and overbite. K loop molar distalizer was fabricated with 0.017x 0.025 TMA wire and placed on the right side. Space gained after four months was 5 mm with anchorage loss of 1mm near premolar region (Fig 10 and 11). Distal movement of molar was in bodily manner and the rate of distalization was almost 1mm per month.

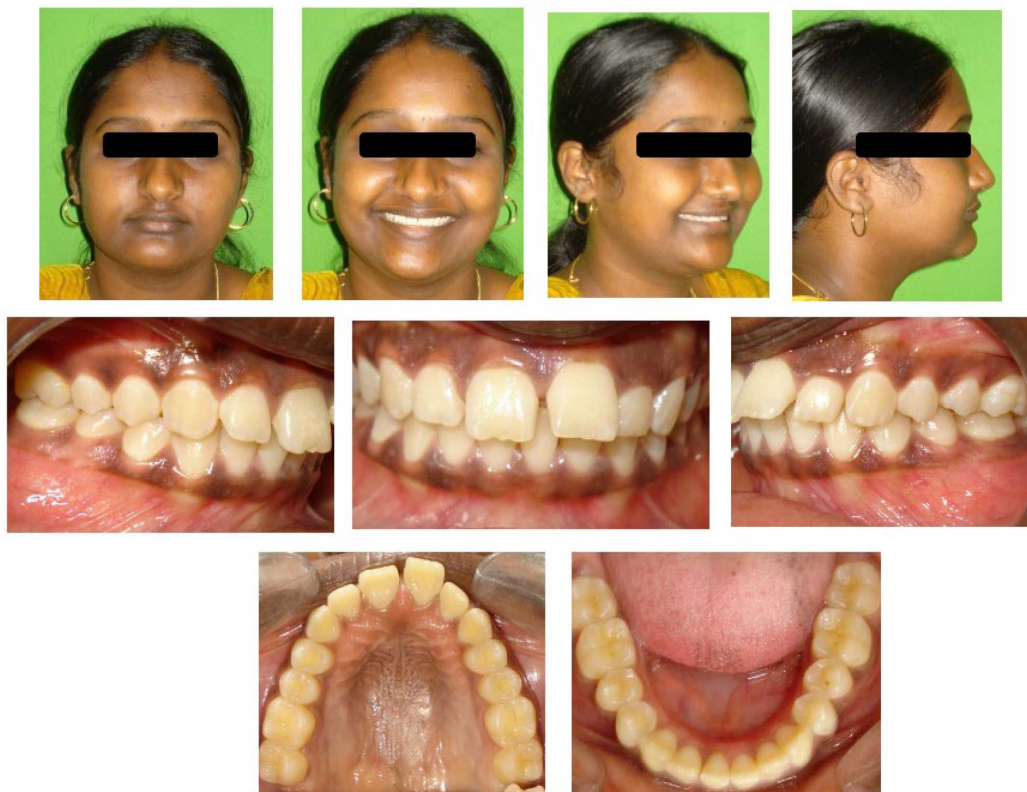

Fig. 8 Pre-treatment photographs

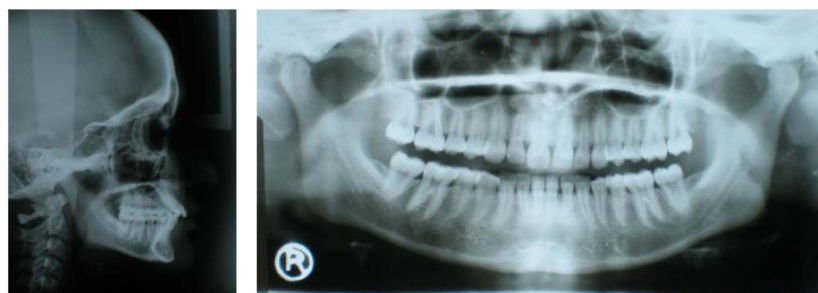

Fig. 9 Pre-treatment lateral cephalogram and orthopantomogram

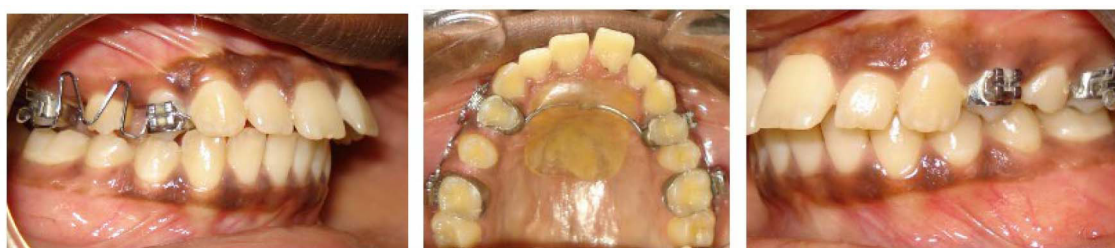

Fig. 10 Post distalization photographs

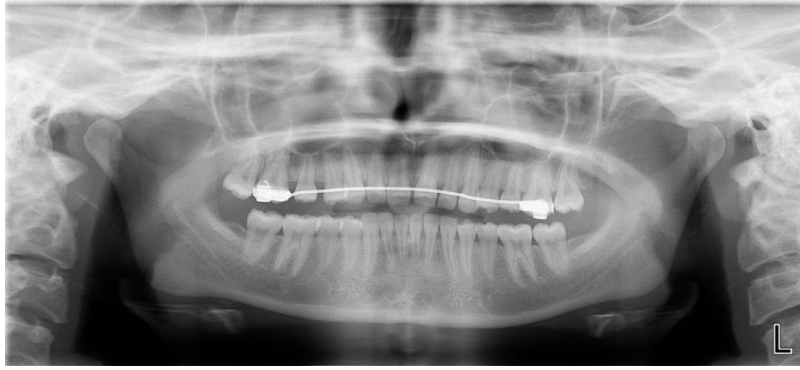

Fig. 11 Post distalization orthopantamogram

CASE 4

A 20 years old female patient presented with chief complaint of irregularly placed teeth. She had an ectomorphic body type, straight profile with low FMA angle, Class II molar relation with hypodivergent jaw bases. Upper centric lines were deviated towards right side (Fig 12 and 13). Space analysis revealed upper arch discrepancy of 9mm and lower 3mm. The treatment objective was to distalize the upper first molars with Double loop Ni Ti appliance to correct the molar relationship and to unravel the crowding without removing any permanent teeth. 0.022" MBT prescription

brackets were bonded and initial aligning and leveling was carried out with 0.016 Ni-Ti wire. Insertion of Double loop Ni Ti arch wire which is fabricated with "0.019x 0.025" neosentalloy wire was done in the upper arch. Class II elastics and uprighting springs on the first premolar were given to prevent anchorage loss. Space gained in arch was 4.5 mm on left side and 3 mm on right side in four months (Fig 14 and 15). Distalization of molar with mild amount of tipping was seen. The rate of distalization was 1mm per month. Soldered TPA was used for holding the gained space.

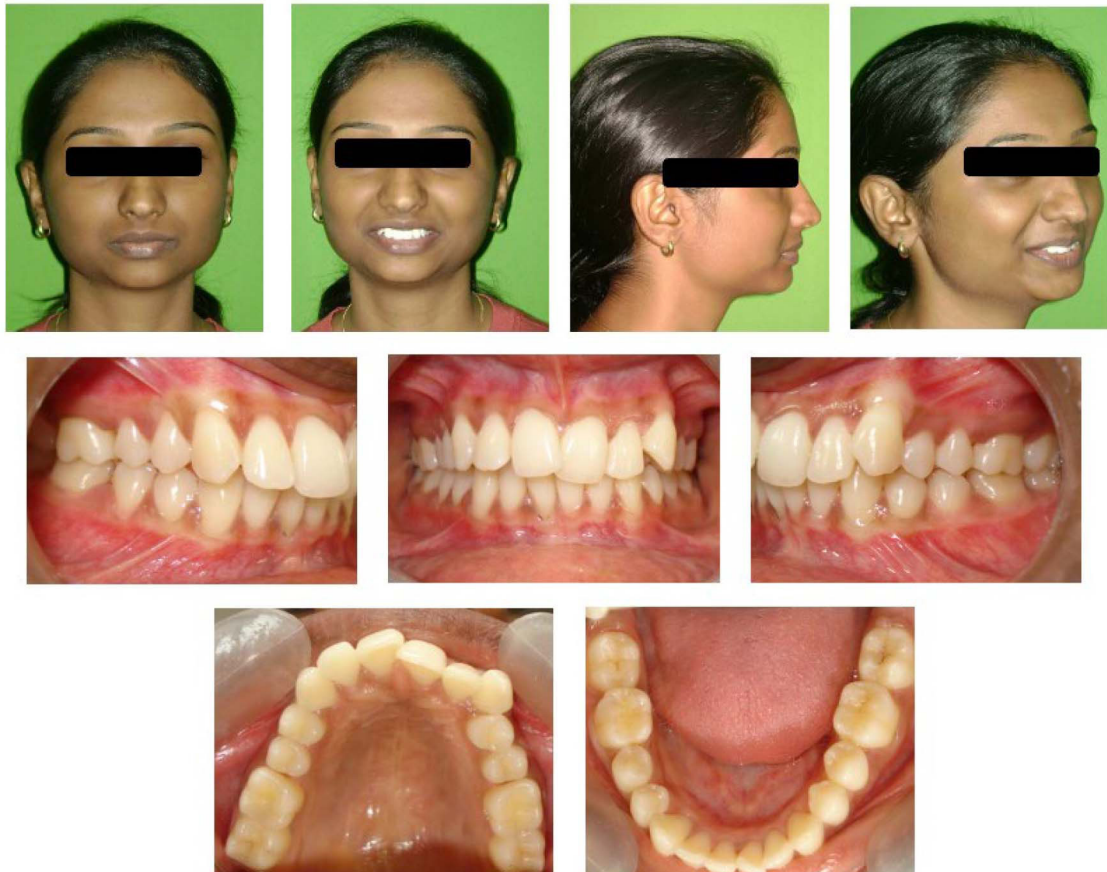

Fig. 12 Pre-treatment photographs

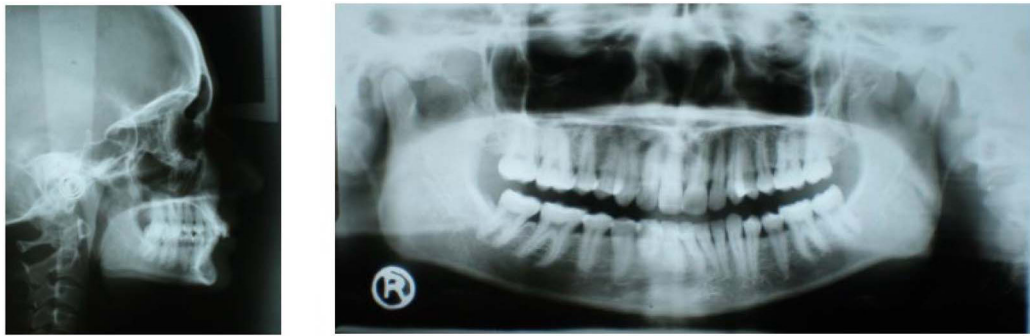

Fig. 13 Pre-treatment lateral cephalogram and orthopantomogram

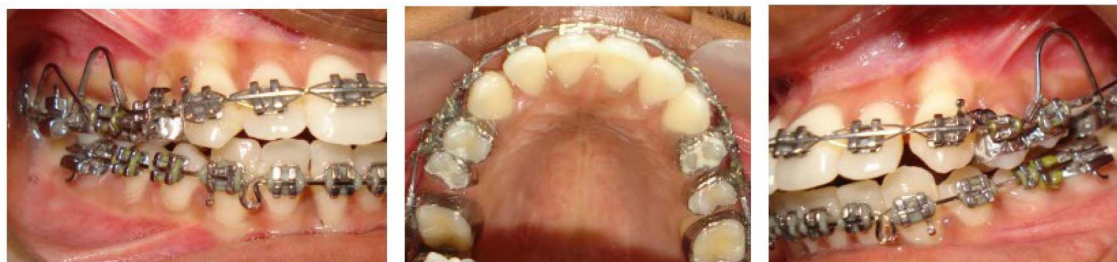

Fig. 14 Post distalization photographs

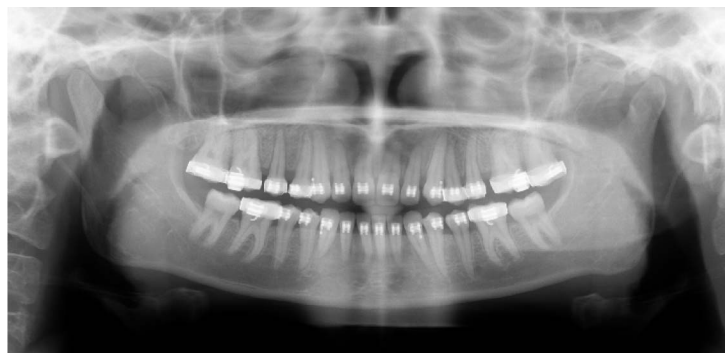

Fig. 15 Post distalization orthopantomogram

CASE 5

A 12 years female patient reported with the chief complaint of crowded teeth. She had mesomorphic body type, convex profile with average FMA angle, Class II molar relation with crowding and deviated lower mid-line by 2mm (Fig 16 and 17). Space analysis indicates a discrepancy of 4 mm in upper arch and 3 mm in lower arch. The treatment objective was to distalize the upper first molars with C- space regainer to correct the

molar relationship and to unravel the crowding without removing any permanent teeth. The open-coil spring used in the C- space regainer had 130% of the length between the soldered point and the mesial edge of the headgear tube. Activation was done by compression of coil spring. Space gained bilaterally on each side was 3mm in three months without anchorage loss (Fig 18 and 19). The rate of distalization was 1mm per month.

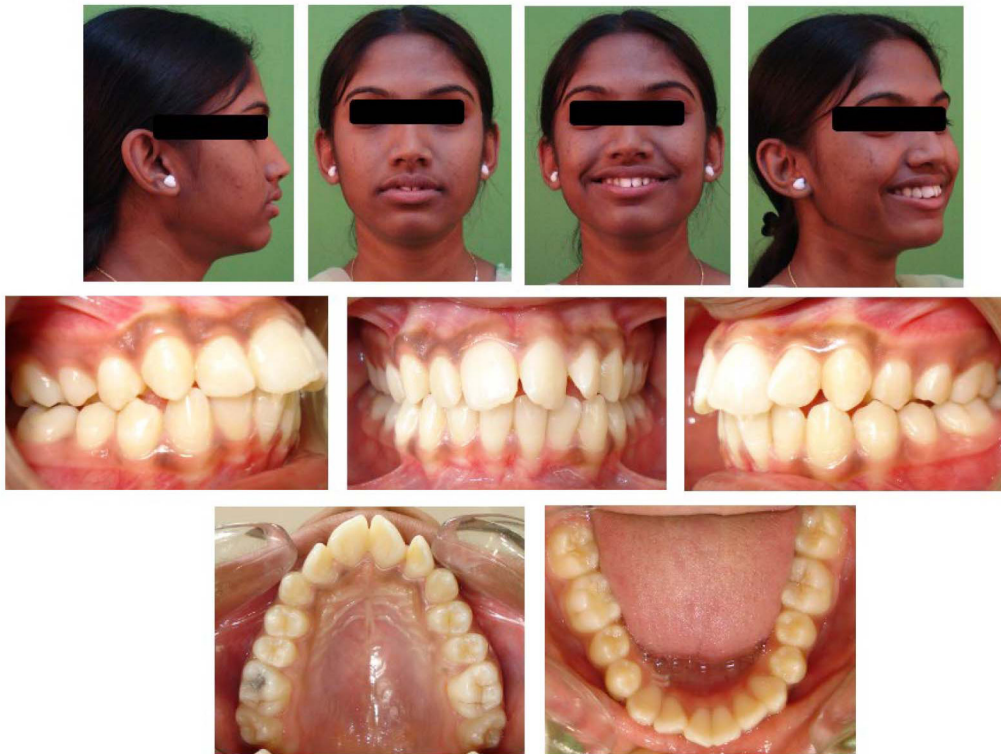

Fig. 16 Pre-treatment photographs

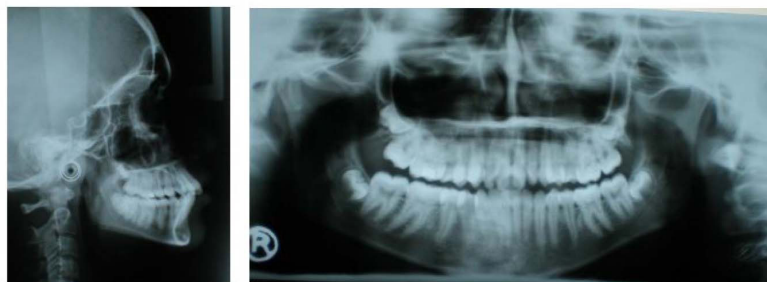

Fig. 17 Pre-treatment lateral cephalogram and orthopantomogram

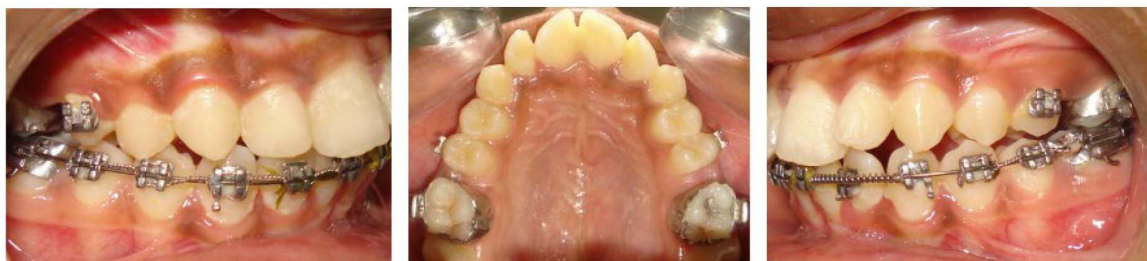

Fig. 18 C- space regainer

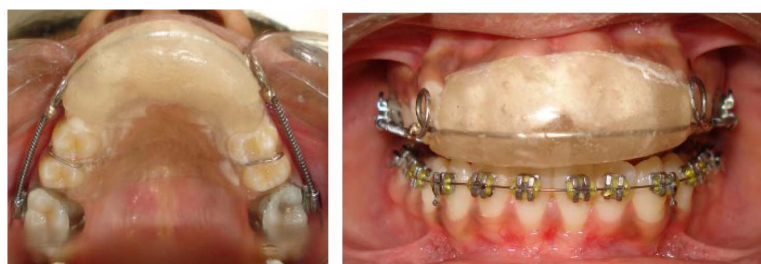

Fig. 19 Post distalization photographs

DISCUSSION

Ghosh and Nanda (1996)⁶ reported that the pendulum appliance is a reliable method for distalizing maxillary molars at the expense of moderate anchorage loss. Byloff and Darendeliler⁷ and Byloff⁸ showed that the pendulum appliance moved molars distally without creating bite opening, but the molars did tend to tip. Hilgers¹ had shown that when the appliance is placed before the eruption of the second molars, two-thirds of the space gained is by molar distalization, one-third is experienced as forward shift of the anterior teeth. Pendulum appliances have several advantages which include cost effectiveness and chairside activation.

Carano A, Testa M² have shown that distal jet provides bodily movement of molars. Its insertion is easy, well tolerated by patient, very esthetic, can be placed unilaterally or bilaterally. It also permits simultaneous use of full bonded appliances. Maxillary molars were distalized with less distal tipping and without the lingual movement that occurs with the pendulum. The distal jet can be easily converted into a Nance holding arch to maintain the distalized molar position. Distal jet appliance is commercially available, very easy to use, but it is expensive.

Kalra V³ quoted that K-loop molar distalizer will move the molars distally by 4 mm and premolars by 1mm. Headgear were used for reinforcement of anchorage. With this appliance, maxillary molars are distalized with less distal tipping. Research has shown that molar undergoes translatory movement instead of tipping and root movement continues even after the force has dissipated. Single activation produces 4mm distal molar movement in 6 to 8 weeks and 1mm anchorage loss is seen during 4mm of molar distalization. This appliance is very easy to fabricate and cost effective too.

Giancotti⁴ quoted that double loop Ni Ti requires minimal patient co-operation and it is ideal for simultaneous distalization for first and second maxillary molar. Anchorage is easily controlled, without any need for TPA/Nance button. Due to stretching of transeptal fibres, 1st molars can be distalized using 80 gms of light force. Maxillary molars are distalized bodily and less distal tipping.

Kyu-Rhim Chung, Young-Guk Park⁵ reported that C-space regainer moves the molar bodily without significant incisor flaring. It can be used to intrude teeth as well as to move them distally or sagittally. Vertical control is maintained by adjusting the frame work occlusally or gingivally. Advantages of C-space regainer include easy fabrication, very economical and give good result. Major disadvantage was its unesthetic look due to acrylic plate on the front teeth.

CONCLUSION

- There are many advantages and disadvantages of both the intra-oral and extra-oral methods of molar distalization. It should be remembered that patient selection for a particular method of distalization is of utmost importance and should not be overlooked.
- Pendulum appliance was better because of easy fabrication, less frequent activation, economical too. But in view of bodily tooth movement, esthetic, anchor loss, distal jet appliance was a better choice. Anchor loss was more with double loop NiTi appliance as compared with the others. K-loop appliance is generally good for those cases where we require very minimal space to correct the molar relationship.

OJN

REFERENCES

1. Hilgers JJ. The pendulum appliance for Class II non-compliance therapy. *J Clin Orthod* 1992;26:706-14.
2. Carano A, Testa M. The distal jet appliance for upper molar distalization. *J Clin Orthod* 1996;30:374-80.
3. Kalra V: The K-loop molar distalizing appliance. *J Clin Orthod* 1995; 29: 298-301.
4. Aldo Giancotti, Paola Cozza: Nickel Titanium double-loop system for simultaneous distalization of first and second molars: *J Clin Orthod* 1998; 32: 255-260.
5. Kyu-Rhim Chung: C-Space Regainer for Molar Distalization: *J Clin Orthod* 2000; 34:32-39.
6. Ghosh J, Nanda RS. Evaluation of an intraoral maxillary molar distalization technique. *Am J Orthod Dentofacial Orthop* 1996; 110: 639-46.
7. Byloff FK, Darendeliler MA. Distal molar movement using the pendulum appliance. Part 1: clinical and radiological evaluation. *Angle Orthod* 1997; 67:249-60.
8. Byloff FK, Darendeliler MA, Clar E, Darendeliler A. Distal molar movement using the pendulum appliance. Part 2: the effects of maxillary molar root uprighting bends. *Angle Orthod* 1997; 67:261-70.