

# Correction of Skeletal Class II Malocclusion in a Growing Child Using Standard Twin Block: A Case Report

Abhishek Kumar<sup>1</sup>, Parul Priya<sup>2</sup>, Shrestha Singh<sup>3</sup>, Abhay Kumar Jain<sup>4</sup>, Raghu Ranjan Prasad<sup>5</sup>

<sup>1,2</sup>Senior Lecturer, <sup>3</sup>Post Graduate, <sup>5</sup>Reader  
Department of Orthodontics and Dentofacial Orthopedics,  
Hazaribag College of Dental Sciences and Hospital, Hazaribag, Jharkhand, India

<sup>4</sup>Asst. Professor, Dept. of Orthodontics  
Rajendra Institute of Medical Sciences, Ranchi

Corresponding author: Abhay Kumar Jain; Email: docabhayjain@gmail.com

## ABSTRACT

Mandibular deficiency in a Class II malocclusion is a frequently encountered condition that can be managed with myofunctional appliance in a growing child. An 11-year-old patient presented with a complaint of forwardly placed upper front teeth. The patient had a convex facial profile, acute naso-labial angle, deep mento-labial sulcus with lip trap. Clinically the patient showed positive VTO. The clinical findings and cephalometric analysis indicated skeletal Class II jaw bases owing to prognathic maxilla and retrognathic mandible with Angle's Class II division 1 malocclusion. CVMI showed that the patient was in his growth phase. The treatment was done with a standard twin block appliance for 9 months followed by fixed orthodontic treatment. The post functional phase showed correction of skeletal class II jaw base and marked improvement in the facial profile from convex to straight. It was later followed by fixed orthodontic treatment in the second phase upon completion of which bonded lingual retainer and wrap around retainers were given in the upper and lower arch. The total duration of the treatment was 23 months.

**KEYWORDS:** Class II malocclusion, Myofunctional appliance, Two phase treatment, twin block.

## INTRODUCTION

Class II malocclusion due to mandibular deficiency is the most common skeletal problem seen in orthodontics.<sup>1</sup> Skeletal problems when addressed during the growth period can bring considerable changes in the bony anatomy by redirecting the growth in the desired direction.<sup>2-5</sup> Alfred Paul Rogers was the first to recommend the role of muscles in the correction of certain malocclusion.<sup>6</sup> The basis of myofunctional therapy is to use the stretching of the muscles during the growth period to bring about changes in the bones.<sup>7</sup> The forces of the muscles are transmitted to the bone to bring about remodeling for the correction of class II discrepancy.<sup>8</sup>

Myofunctional appliances have been in use for a long time now to bring about considerable changes in the mandible to correct Class II malocclusions. Several studies have been done where twin block is seen to be most effective in terms of class II correction

as well as patient compliance.<sup>9-11</sup> Twin Block was developed by William J. Clark in the 1970's.<sup>12</sup> It is the most commonly used myofunctional appliance.<sup>13</sup> Treatment with a functional appliance usually lasts for 9-12 months. This is followed by a support phase and fixed appliance therapy for correction of any dental problems that persist, proper alignment and good interdigitation.<sup>14-15</sup> The following is a case with Class II division 1 malocclusion treated with standard Twin block appliance followed by fixed appliance therapy.

## CASE REPORT

An 11-year-old male patient visited the Department of Orthodontics and Dentofacial Orthopedics with the chief complaint of forwardly placed upper front teeth. The patient had mouth breathing habit. No other relevant medical or dental history was diagnosed.

## Extraoral assessment

The patient had mesoprosopic face form, mesocephalic

head shape with convex facial profile, average clinical FMA, incompetent lips with lip trap, acute nasolabial angle, deep mentolabial sulcus and receded chin (Fig. 1). No gross facial asymmetry was noticed.

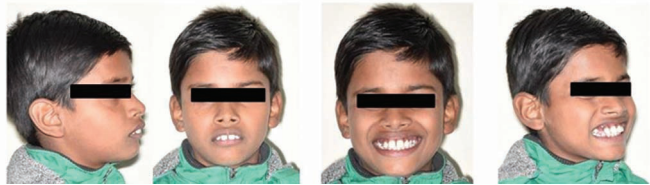

Figure 1: Pre-treatment extra-oral photographs.

### Intraoral assessment

He was in mixed dentition stage with Angle's Class II molar and class II canine relation. The patient had an overjet of 9 mm and overbite of 8 mm, proclined upper incisors with spacing and curve of Spee of 3mm. The patient was in a mixed dentition phase. The upper and lower deciduous second molars were present with erupting upper canines and first premolars. The dental midlines were coincident (Fig. 2).

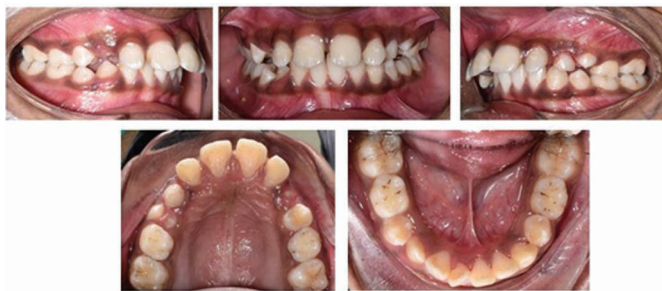

Figure 2: Pre-treatment intra-oral photographs.

### Growth status

The skeletal maturity was assessed using the cervical vertebral maturation index (CVMI) staging, which showed Stage 2 of skeletal maturation (acceleration stage, with more than 65%–80% pubertal growth still remaining).

### Cephalometric analysis

The pre-treatment cephalometric analysis revealed skeletal Class II jaw bases with mild prognathic maxilla and retrognathic mandible, horizontal growth pattern, proclination of upper and lower incisors. The patient had a lip strain of 2 mm.

The panoramic radiograph shows unerupted third molars, canines and premolars in all quadrants with deciduous canines, first and second molars in all quadrants (Fig. 3).

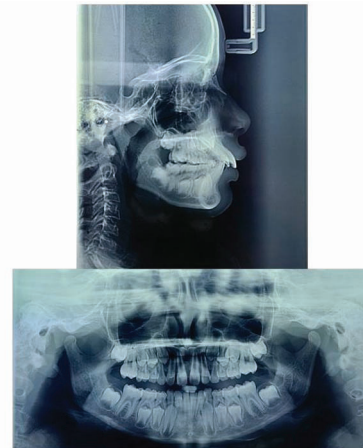


Figure 3: Pre-treatment radiographs.

On the basis of clinical examination and cephalometric findings, diagnosis of skeletal Class II jaw base with prognathic maxilla and retrognathic mandible was made. The patient was in a mixed dentition phase with Class II division 1 malocclusion in with upper lip strain and lower lip trap.

Clinically the patient had positive VTO favoring the use of myofunctional appliance for skeletal correction.

### Aims and Objectives of Treatment

1. To achieve Class I skeletal base
2. To achieve normal incisor axial inclination
3. To improve facial profile
4. To achieve lip competency
5. To achieve Class I molar and canine relation
6. To unravel crowding and close the spaces
7. To achieve a pleasing esthetic profile
8. To achieve ideal overjet and overbite

### Treatment Plan

Based on the clinical and cephalometric analysis, it was decided to treat this case by two phase therapy. The first phase with the twin block appliance followed by fixed orthodontic appliances in the second phase.

### Treatment Progress

The first phase of the treatment was started with myofunctional appliance. Bite registration was done on the patient, standard Twin block appliance (Fig. 4) was fabricated and delivered to the patient. Once the patient started using the appliance full time, the trimming of the appliance was done as per the protocol.<sup>12</sup> The appliance was continued for 9 months, followed by retentive phase for 3 months using anterior inclined plane to retain mandibular advancement. After functional phase



the profile of the patient had significantly improved with marked reduction in overjet and overbite. Correction of molar and canine relation were achieved. The molar relationship was overcorrected keeping relapse into consideration. (Fig. 5 and 6).

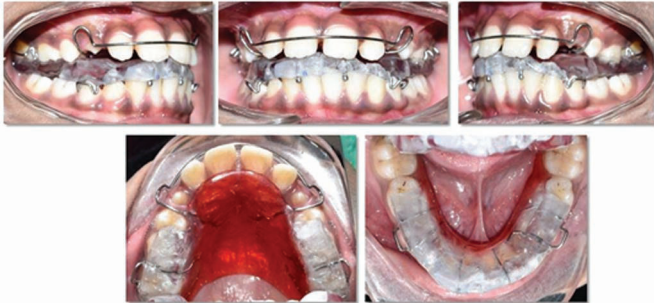

Figure 4: Twin block

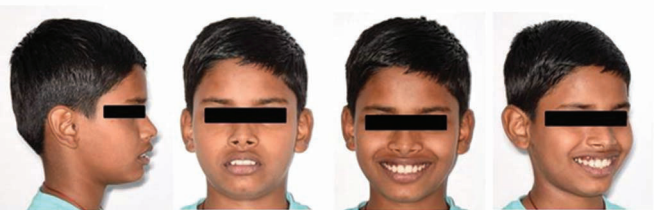

Figure 5: Post-functional extraoral photographs

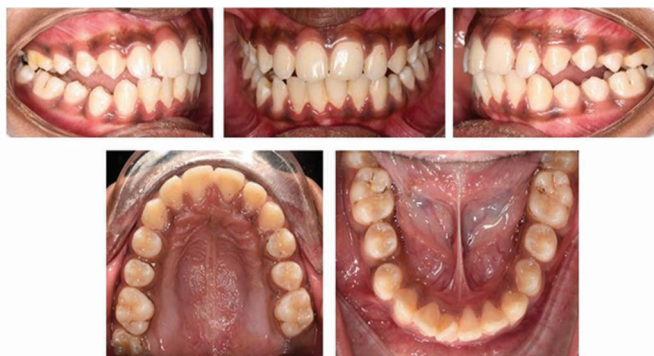

Figure 6: Post-functional intraoral photographs

At the end of Phase I, a preadjusted edgewise appliance (using a MBT 0.022" slot prescription) was bonded on the upper and lower arches and a 0.014 NiTi was placed (Fig. 7).

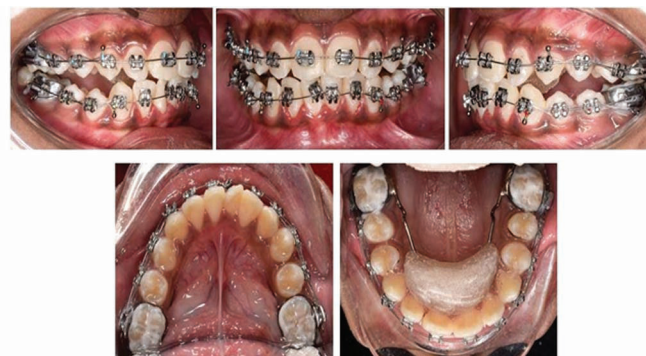

Figure 7: Bonding of upper and lower arch with anterior inclined plane

After 3 months the anterior inclined plane was removed and 0.016" NiTi wires were placed. This was followed by 0.017 X 0.025" NiTi wires and 0.019 X 0.025" stainless steel wires with Class II elastics. Upper and lower 2nd molars were bonded subsequently. Finally, 0.014 A J Wilcock finishing wire was placed with red elastics in triangular fashion for settling of occlusion (Fig. 8).

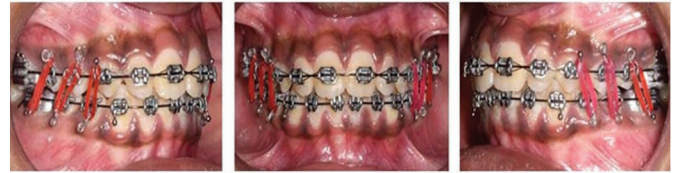

Figure 8: finishing wire with Settling elastics

After debonding, the patient was given bonded lingual retainer with upper and lower wrap around retainers to be worn full time initially and later during nighttime (Fig. 9).

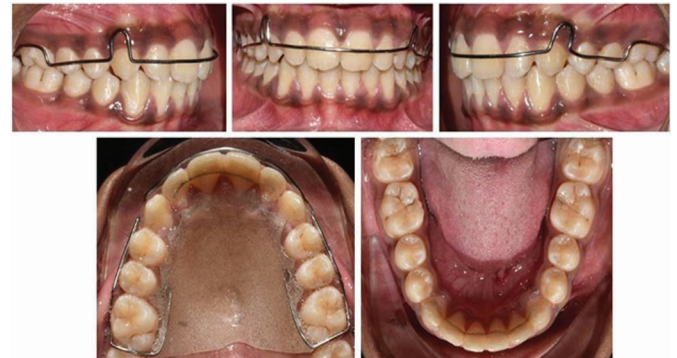

Figure 9: Fixed lingual retainer and wrap around retainer in upper and lower arch.

The overall treatment duration was 23 months which included 12 months of myofunctional appliance therapy and 11 months of fixed appliance treatment.

### Treatment Results

Skeletal correction of the retrognathic mandible was achieved with improvement in the skeletal and soft tissue profile. There was significant increase in the lower anterior facial height seen both clinically and cephalometrically (Fig. 10 and 11).

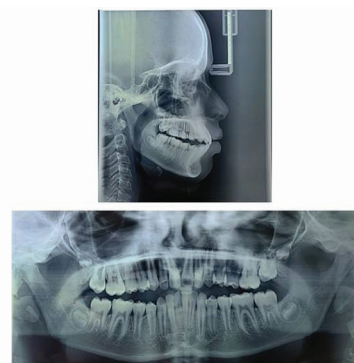


Figure 10: Post-functional radiographs

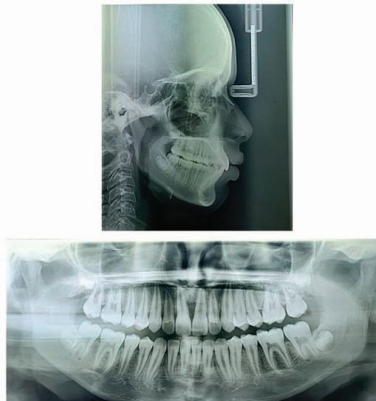


Figure 11: Pre- finishing radiographs

After the fixed appliance treatment, Class I molar, canine and incisor relationship was achieved with ideal overjet, overbite, mutually protected occlusion and canine guidance on left and right lateral excursions with no working or non-working side interferences (Fig. 12).

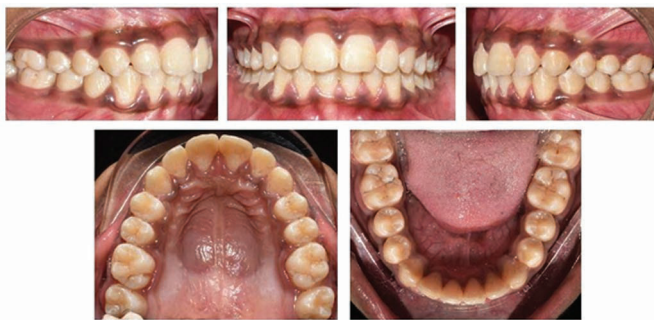

Figure 12: Post-treatment intraoral photographs

The treatment objectives were achieved, and the profile of the patient improved after the treatment (Fig.13).



Figure 13: Post-treatment extraoral photographs

The upper and the lower midlines were matching and in line with the facial midline. Evaluation of post treatment panoramic radiographs showed root parallelism and normal alveolar bone levels. The cephalometric changes and the comparison of pretreatment, post-functional and post-treatment values are evident in Table 1, 2 and 3 and changes in superimpositions are seen in (Fig. 14) demonstrated that the patient grew towards a Class I skeletal pattern.

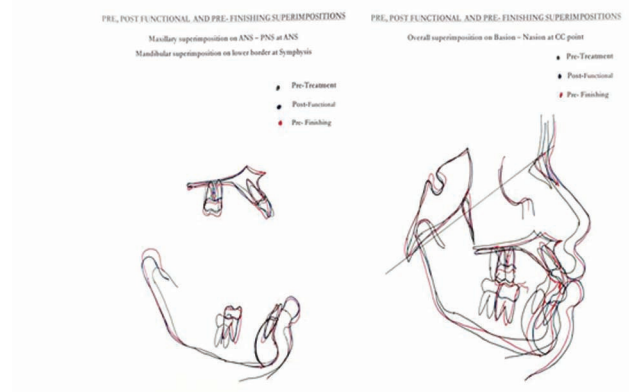


Figure 14: Tracing Superimpositions

Pre-treatment: Black

Post – Functional: Blue

Post-treatment: Red

Table 1: Comparison of skeletal changes in sagittal plane

Variable	Pre-treatment	Post-functional	Post-treatment
SNA	85°	83°	82°
SNB	77°	80°	79°
ANB	8°	3°	3°
Wits	7mm	-2mm	-1mm
Beta Angle	24°	32°	30°

Table 2: Comparison of skeletal changes in Vertical Plane

Variable	Pre-treatment	Post-functional	Post-treatment
Go-Gn to SN	25°	32°	32°
Y-Axis	59°	60°	61°
Basal plane angle	25°	27°	27°
Jaraback Ratio	66.0%	63.8%	64%
FMA	22°	28°	28°

Table 3: Comparison of dento-alveolar and soft tissue changes

Variable	Pre-treatment	Post-functional	Post-treatment
U1 to NA (Angle)	30°	26°	20°
U1 to NA (mm)	8mm	5mm	5mm



Variable	Pre-treatment	Post-functional	Post-treatment
U1 to SN	114°	108°	104°
U1 to PP	122°	114°	110°
U1 to A-Pog	10mm	7mm	6mm
IMPA Angle	96°	103°	98°
L1-NB Angle	28°	35°	34°
L1-NB mm	5mm	7mm	4mm
Interincisal Angle	116°	115°	113°
L1 to A-Pog	4mm	5mm	3mm
Nasolabial Angle	88°	99°	95°
Lip Strain	2mm	1mm	0mm
Mentolabial sulcus	5mm	3mm	3mm
E-line to upper lip	2mm	1mm	1mm
E-line to lower lip	0mm	3mm	3mm

## DISCUSSION

Skeletal jaw discrepancies are very common in childhood.<sup>1</sup> If neglected they can lead to untoward and unaesthetic changes in the soft tissue facial profile of the patient. Early identification and intervention at the correct age is imperative to prevent the severity of such malocclusions. For correction of class II malocclusions with retrognathic mandible various myofunctional appliances have been used conventionally.<sup>8</sup> Twin block has the advantage of full-time wear, shorter treatment duration and is well tolerated by patients.<sup>16</sup>

In the present case with class II malocclusion, there was marked improvement in the patients skeletal, dental and soft tissue profile with the use of twin block. The SNA value was reduced by 3° suggestive of the headgear effect of the twin block and the SNB value increased by 2° which led to the decrease in the ANB angle by 5°. The Beta angle changed from 24° to 30°. Thus, the change of ANB angle to 3° and beta angle to 30° indicate the change of skeletal base from Class II to Class I. There was a change in the Jaraback ratio from 66% to 64% into its normal value. There was a change in saddle angle from 125° to 126°, articular angle from 137° to 133° and gonial angle from 130° to 133°

A significant observation was seen during the functional phase. Development of lateral open bite was observed bilaterally. This could be due to improper trimming of the appliance or because no expansion was done to compensate for the transverse discrepancy between the jaws as the mandible moves forward. Although incisal capping was done to prevent lower incisor proclination 17 there was a mild increase in the IMPA value by 2° post treatment and L1-NB angle by 6°. The U1-SN value was reduced by 10° and U1-NA angle reduced by 10° by the end of the treatment. The soft tissue findings were pleasant with the reduction in the lip strain to 0 mm. There was a significant reduction seen in the depth of the mentolabial sulcus indicating the correction of the lip trap.

Although 3-D superimpositions show better results than 2-D in terms of accuracy, due to certain limitations 2-D superimpositions were done in this case. Maxillary superimposition shows decrease of 10° in the inclination of the upper incisors. Mandibular superimposition showed an increase in the length of the condylar neck and mandibular body. This led to the 10 mm mesial movement of the lower molar. Overall superimposition shows the mesial movement of the upper and lower molars, a decrease in the inclination of the maxillary incisors, and an increase in the inclination of mandibular incisors. Also, a shift of the lower border of the mandible is seen from average to vertical growth.

## CONCLUSION

Excellent post functional and post orthodontic results of the patient were seen. There was considerable improvement in the facial profile, lip competency and occlusion of the patient. Therefore, proper diagnosis and treatment planning of the cases with skeletal discrepancy during growth period can lead to significant changes in the orofacial form of the individual.

## REFERENCES

1. Proffit WR, Fields HW. Contemporary Orthodontics. 3rd ed. St Louis, Mo: Mosby; 2000:13, 96-98, 260-269, 481.
2. Riolo ML, Avery JK. Essentials for Orthodontic Practice. Ann Arbor, Mich: EFOP Press; 2003:170-173.
3. Moyers RE, Riolo ML, Guire KE, Wainright RL, Bookstein FL. Differential diagnosis of class II malocclusions. Part 1. Facial types associated with class II malocclusions. Am J Orthod. 1980;78(4):477-494.
4. Baccetti T, Franchi L, McNamara JA Jr, Tollaro I. Early dentofacial features of class II malocclusion: a longitudinal study from the deciduous through the mixed dentition. Am J Orthod. 1997;111(5):502-509.
5. McNamara JA Jr. Components of Class II malocclusion in children 8-10 years of age. Angle Orthod. 1981;51(3): 171-202.
6. Rogers, A.P.: Exercises for the development of the muscles of the face, with a view to increase their functional activity. Dent. Cosmos 60:857-897, 1918.
7. Mills J.R. The effect of functional appliances on the skeletal pattern. Br. J. Orthod. 1991;18(4):267-275.
8. Graber T.M., Neumann B. Removable Orthodontic Appliances. 2nd ed. W.B. Saunders Company. 1984. 54-84
9. O'Brien The effectiveness of treatment of class II malocclusion with the Twin Block appliance: a randomised, controlled trial. Am. J. Orthod. Dentofac.Orthop. 2003;124:128-137.
10. O'Brien The effectiveness of treatment of class II malocclusion with the Twin Block appliance. A randomised, controlled trial. Part 1: dental and skeletal effects. Am. J. Orthod. Dentofac.Orthop. 2003;124:234-243.
11. O'Brien The effectiveness of treatment of class II malocclusion with the Twin Block appliance: a randomised, controlled trial. Part 2: psychological effects. Am. J. Orthod. Dentofac.Orthop. 2003;124:488-495.
12. Clark W.J. The Twin Block technique.A functional orthopaedic appliance system. Am. J. Orthod. Dentofac.Orthop. 1988;93(1):1-18.
13. Chadwick S.M., Banks P., Wright J.L. The use of myofunctional appliances in the UK: a survey of British orthodontists. Dent. Update. 1998;25(7):302-308.
14. Tulloch FC, Phillips C, Koch G, Proffit WR. The effect of early intervention on skeletal pattern in Class II malocclusion: A randomized clinical trial. American Journal of Orthodontics and Dentofacial Orthopedics 1:391-400,1997.
15. Jain AK, Patil AK, Ganeshkar SV, Sangamesh B, Chugh T. Non-extraction treatment of skeletal class II malocclusion. Contemporary Clinical Dentistry. 2012 Jul;3(3):334.
16. Harradine NW, Gale D. The effects of torque control spurs in twin-block appliances. Clin Orthod Res. 2000 Nov;3(4):202-9.
17. Mills CM, McCulloch KJ. Treatment effects of the twin block appliance: a cephalometric study. Am J Orthod Dentofacial Orthop. 1998 Jul;114(1):15-24.